



UNIVERSIDADE D  
**COIMBRA**

João Pedro Teixeira Marques

**GENOMIC PROFILE AND GENOTYPE-  
PHENOTYPE CORRELATIONS IN PATIENTS  
WITH INHERITED RETINAL DYSTROPHIES  
IN PORTUGAL:  
THE IRD-PT STUDY**

VOLUME 1

Tese no âmbito do Programa de Doutoramento em Ciências da Saúde da Faculdade de Medicina da Universidade de Coimbra orientada pelo Professor Doutor Rufino Martins da Silva e pelo Professor Doutor Jorge Saraiva e apresentada à Faculdade de Medicina da Universidade de Coimbra

Abril de 2023





UNIVERSIDADE D  
**COIMBRA**

João Pedro Teixeira Marques

**GENOMIC PROFILE AND GENOTYPE-  
PHENOTYPE CORRELATIONS IN PATIENTS  
WITH INHERITED RETINAL DYSTROPHIES  
IN PORTUGAL:  
THE IRD-PT STUDY**

**VOLUME 1**

**Tese no âmbito do Programa de Doutoramento em Ciências da  
Saúde da Faculdade de Medicina da Universidade de Coimbra  
orientada pelo Professor Doutor Rufino Martins da Silva e pelo  
Professor Doutor Jorge Saraiva e apresentada à Faculdade de  
Medicina da Universidade de Coimbra**

Abril de 2023



## TABLE OF CONTENTS

ACKNOWLEDGEMENTS .....	3
LIST OF ABBREVIATIONS .....	4
ABSTRACT / RESUMO .....	7
CHAPTER 1: GENERAL INTRODUCTION .....	11
1.1. Background .....	13
1.2. Genetics of IRDs.....	14
1.3. IRD signs and symptoms.....	15
1.4. IRD Phenotypes .....	16
1.5. Deep Phenotyping .....	17
1.6. Genotype-Phenotype Correlations.....	20
1.7. Disease Awareness and Education .....	21
1.8. Patient registries .....	22
1.9. Patient-Reported Outcomes.....	22
1.10. Current and future therapeutic interventions.....	23
1.11. Aims and Outline of this Thesis.....	25
CHAPTER 2: IRD-RELATED UNMET NEEDS.....	37
2.1. Inherited Retinal Degenerations in Portugal: Addressing the Unmet Needs.....	39
2.2. The need for widely available genomic testing in rare eye diseases: an ERN-EYE position statement.....	45
2.3. Design, development and deployment of a web-based interoperable registry for Inherited Retinal Dystrophies in Portugal – The IRD-PT .....	59
2.4. Challenges, facilitators and barriers to the adoption and use of a web-based national IRD registry: lessons learned from the IRD-PT registry .....	79
2.5. Instagram as a vehicle to promote disease awareness and medical education in #retinaldystrophies .....	87
2.6. Treating the first Portuguese patient with Luxturna: A small step for world science, a giant leap for Portuguese Ophthalmology .....	91
CHAPTER 3: CLINICAL AND MOLECULAR STUDIES.....	97
3.1. Clinical/demographic, functional testing and multimodal imaging differences between genetically solved and unsolved Retinitis Pigmentosa .....	99
3.2. <i>EYS</i> -associated Sector Retinitis Pigmentosa .....	117
3.3. <i>Eyes Shut Homolog-Associated Retinal Degeneration: Natural History, Genetic Landscape, and Phenotypic Spectrum</i> .....	135
3.4. Genetic spectrum, retinal phenotype and peripapillary RNFL thickness in <i>RPGR</i> heterozygotes .....	155
3.5. Frequency of cystoid macular edema and vitreomacular interface disorders in genetically solved syndromic and non-syndromic Retinitis Pigmentosa.....	175
3.6. Non-exudative macular neovascularization in Pseudoxanthoma Elasticum.....	193
CHAPTER 4: PATIENT-REPORTED OUTCOMES .....	211

4.1. Portuguese translation and linguistic validation of the Michigan Retinal Degeneration Questionnaire and the Michigan Vision-Related Anxiety Questionnaire in a cohort with Inherited Retinal Degenerations .....	213
4.2. Self-reported visual function and psychosocial impact of visual loss in <i>EYS</i> -associated retinal degeneration in a Portuguese population .....	219
CHAPTER 5: OPHTHALMIC IMAGING IN IRD .....	233
5.1. <i>MFRP</i> -Related Nanophthalmos-Retinitis Pigmentosa-Foveoschisis-Optic Disc Drusen Syndrome .....	235
5.2. <i>SLC24A1</i> -Associated Congenital Stationary Night Blindness in a woman with an abnormal fundus .....	239
5.3. Multimodal Imaging in Hypotrichosis with Juvenile Macular Degeneration .....	243
5.4. Gyrate atrophy of the choroid and retina .....	245
5.5. Double concentric hyperautofluorescent ring in <i>EYS</i> -Associated Retinitis Pigmentosa .....	249
5.6. Genetic, Anatomical, and Functional Correlation of Sector Retinitis Pigmentosa .....	253
5.7. Subretinal bleb of Voretigene Neparovec .....	257
CHAPTER 6: GENERAL DISCUSSION .....	259
6.1. Widely available genetic testing for IRDs: a clinical necessity .....	261
6.2. The IRD-PT registry .....	261
6.3. Disease awareness and medical education .....	262
6.4. Voretigene Neparovec: an igniting hope .....	263
6.5. Extending the mutational and phenotypical spectrum of Retinitis Pigmentosa .....	264
6.6. Deep phenotyping: the more detailed, the better .....	267
6.7. Patient-reported outcomes: measuring results that matter .....	268
6.8. Final Remarks .....	269
CHAPTER 7: LIST OF PUBLICATIONS .....	277
CHAPTER 8: FUNDING .....	283
CHAPTER 9: ANNEXES .....	287

## ACKNOWLEDGEMENTS

Enrolling in a PhD program is never an easy task. To do it while continuing to practice Ophthalmology on a daily basis makes it even more challenging. After years of frustration, conquers, perseverance, achievements and defeats, I take pride in what I was able to accomplish and, most importantly, in what the IRD-PT study meant to the IRD community in Portugal.

I am deeply indebted to a lot of people who believed me, pushed me and lead me through the ups and the downs, motivating me to keep going forward.

Words cannot express my gratitude to my mentors – Professor Rufino Silva and Professor Jorge Saraiva – for their invaluable patience, expertise, guidance and feedback. I also could not have undertaken this journey without the continuous support of Professor Joaquim Murta, who always pointed me in the right direction and offered his vast knowledge and expertise. Additionally, this endeavor would not have been possible without the support and constant availability of Dr Ana Luísa Carvalho, who worked hand in hand with me to offer genetic testing and genetic counselling to IRD patients and their families. A special thank you note should also go to Professor Bart Leroy for the friendship, inspiration and teaching, and for Dr Thiran Jayasundera and Professor Maria Fernanda Abalem for their active collaboration in the Portuguese translation of MRDQ and MVAQ. Additionally, I must thank all members of the EVICR.net Retinal Dystrophies expert committee, with whom I have learned, discussed and grown and as an IRD specialist.

I am also grateful to Professor Maria da Luz Cachulo, Professor Isabel Pires, Professor João Figueira, Dr Catarina Paiva, Professor Henrique Girão, Professor Francisco Ambrósio, Professor Henrique Alves, Dr João Gil, Dr Sara Geada, Dr Emmanuel Neves, Dr Luís Bernardes, Dr Miguel Raimundo, Dr Pedro Pereira, Dr Telmo Cortinhal, Dr Rosa Pinheiro, Dr Ricardo Soares and Dr Ana Marta, for their companionship, editing help, late-night feedback sessions, and moral support.

Thanks should also go to all my patients, who impacted and inspired me to develop the IRD-PT study. All my work is meant for them.

Lastly, I would be remiss in not mentioning my family, especially my mum and dad, my brother Francisco, and my spouse Filipa. Their belief in me has kept my spirits and motivation high during this process.

## **LIST OF ABBREVIATIONS**

AAV – Adeno-associated virus  
ACMG – American College of Medical Genetics and Genomics  
AD – Autosomal dominant  
AR – Autosomal recessive  
BCVA – Best-corrected visual acuity  
BVMD – Best vitelliform macular dystrophy  
CAIs – Carbonic anhydrase inhibitors  
CFP – Color fundus photography  
CME – Cystoid macular edema  
CNV – Copy number variation  
EMA – European Medicines Agency  
EOG – Electro-oculogram  
EORD – Early-onset retinal degeneration  
ERM – Epiretinal membrane  
ERN-EYE – European Reference Network for Rare Eye Diseases  
EVICR.net – European Vision Institute Clinical Research Network  
EYS – Eyes shut homolog  
EZ – Ellipsoid zone  
FAF – Fundus autofluorescence  
FDA – Food and Drug Administration  
ffERG – Full field electroretinography  
FST – Full field stimulus testing  
GRID – Global Retinal Inherited Disease  
IRDs – Inherited retinal dystrophies/degenerations  
ISCEV – International Society for Clinical Electrophysiology of Vision  
L-ORD – Late-onset retinal degeneration  
LCA – Leber congenital amaurosis  
MLPA – Multiplex ligation-dependent probe amplification  
MNV – Macular neovascularization  
MRDQ – Michigan Retinal Degeneration Questionnaire  
MVAQ – Michigan Vision-Related Anxiety Questionnaire  
NGS – Next generation sequencing  
nsRP – Non-syndromic retinitis pigmentosa  
OCT – Optical coherence tomography



ORDO – Orphanet Rare Disease Ontology  
PERG – Pattern electroretinography  
PROs – Patient-reported outcomes  
PXE – Pseudoxanthoma elasticum  
QoL – Quality of life  
RNFL – Retinal nerve fiber layer  
RP – Retinitis pigmentosa  
RPE – Retinal pigment epithelium  
RPGR – Retinitis pigmentosa GTPase regulator  
SD-OCT – Spectral domain optical coherence tomography  
STGD – Stargardt Disease  
UWF – Ultra-widefield  
VA – Visual acuity  
VMID – Vitreomacular interface disorders  
VUS – Variant of uncertain significance  
WES – Whole exome sequencing  
WGS – Whole genome sequencing  
XL – X-linked



## ABSTRACT / RESUMO

Inherited retinal dystrophies/degenerations (IRDs) are a group of clinically and genetically heterogeneous rare eye diseases affecting 5–10 million individuals worldwide. Despite the low prevalence (~1:3,000 individuals), IRDs are among the most important causes of severe visual impairment and blindness in children and working-age adults in developed countries, thus posing a significant psychosocial and economic burden.

Deep phenotyping and genotyping are essential steps to establish a final diagnosis. Unfortunately, for most IRD patients, this process remains a burdensome odyssey. Mis- and/or disinformation towards IRDs, absence of established referral pathways and inequalities in access to genetic testing or IRD expert centers make the IRD patient journey very difficult.

Several unmet needs exist in the diagnosis and management of IRDs worldwide and Portugal is no exception. The global aim of the IRD-PT study was to improve the understanding of the clinical and molecular characteristics of IRDs in Portugal.

A general introduction to IRDs and the outline of this thesis are provided in chapter 1. In chapter 2, we focus on IRD-related unmet needs. Manuscript 1 is a position paper from the Ophthalmic Genetics Group of the Portuguese Society of Ophthalmology. Here, we identify four pivotal unmet needs, along with reasonable solutions to address them. Manuscript 2 is a position paper from the *European Reference Network for Rare Eye Diseases* where we highlight the need for widely available genomic testing in rare eye diseases, including IRDs. Manuscripts 3 and 4 cover a very specific need in rare diseases: patient registries. We describe the design, development and deployment of the IRD-PT, a national, web-based, interoperable IRD registry; and discuss challenges, facilitators and barriers to its national adoption. The role of social media, specifically Instagram, as a vehicle to promote disease awareness and medical education in IRDs is the topic of Manuscript 5. Finally, Manuscript 6 describes what used to be an unmet need and became a triumph for Portuguese Ophthalmology in general and for those managing IRD patients in particular – the approval of Voretigene Neparvovec and the first Portuguese patient treated with this groundbreaking therapy.

Chapter 3 contains several clinical and molecular studies with a special emphasis on retinitis pigmentosa (RP), the single most prevalent IRD. Manuscript 7 describes the importance of baseline clinical/demographic, functional testing and multimodal imaging when counselling IRD patients about the probability of identifying disease-causing variants. We have shown that a younger age of symptom onset, consanguinity, evidence for a particular inheritance pattern and absence of indicators for phenocopies positively impact the diagnostic yield in patients with nonsyndromic RP. Manuscripts 8 and 9 describe the mutational spectrum and multimodal imaging features of *EYS*-associated disease, with a particular emphasis on atypical phenotypes.

Overall, we report 12 novel clinically significant variants in this gene, the most frequent IRD-associated gene in Portugal. The focus of Manuscript 10 is X-linked RP, in particular the genetic spectrum and retinal phenotype of *RPGR* heterozygotes, i.e. female carriers. We expand the mutational spectrum of *RPGR* by reporting 3 novel clinically significant variants in this gene: 2 likely pathogenic frameshift variants in the ORF15 region and 1 pathogenic variant located in exon 11. Furthermore, we show that a male-type phenotype is not infrequent, stressing the need to test for X-linked RP (including the difficult-to-study ORF15 region) even in families with affected females. Manuscript 11 evaluates the frequency of cystoid macular edema and vitreomacular interface disorders among genetically-solved nonsyndromic and syndromic RP patients and highlights the importance of screening for these potentially treatable central vision-threatening conditions. Finally, in Manuscript 12, multimodal retinal imaging was used to characterize the retinal phenotype of a cohort of Pseudoxanthoma elasticum (PXE). We reported for the first time the prevalence and natural history of non-exudative macular neovascularization, underscoring the role of optical coherence tomography angiography in the management of PXE.

Chapter 4 is dedicated to patient-reported outcomes. Manuscript 13 describes the Portuguese translation and linguistic validation of the *Michigan Retinal Degeneration Questionnaire* and *Michigan Vision-related Anxiety Questionnaire*; while the results of its application in a cohort of *EYS*-associated retinal degeneration are covered in Manuscript 14.

The manuscripts that compose Chapter 5 are examples of the utility of deep phenotyping in IRDs, illustrating retinal changes in uncommon phenotypes.

Lastly, chapter 6 elaborates on the main findings described in this thesis and their implications/clinical relevance for ongoing and future management of IRD patients.

## RESUMO

As distrofias hereditárias da retina (DHR) são um grupo clínico e geneticamente heterogéneo de doenças raras que afetam 5-10 milhões de indivíduos em todo o mundo. Apesar da sua baixa prevalência (~1:3000), as DHR são das principais causas de comprometimento visual grave e cegueira em crianças e adultos em idade ativa, em países desenvolvidos, produzindo um enorme peso económico e psicossocial.

A fenotipagem e a genotipagem são passos essenciais para chegar a um diagnóstico final. Infelizmente, para muitos doentes com DHR, este processo envolve uma longa e penosa odisseia. A desinformação que existe em relação às DHR, a ausência de vias de referência bem estabelecidas e as desigualdades no acesso a testes genéticos e centros especializados em DHR, tornam a jornada do doente num caminho muito difícil de percorrer.

Mundialmente, são múltiplas as necessidades não satisfeitas no diagnóstico e acompanhamento de DHR e Portugal não é exceção. O objetivo principal do estudo IRD-PT era melhorar o conhecimento das características clínicas e moleculares das DHR em Portugal.

No capítulo 1 é feita uma introdução geral às DHR e apresentada a organização desta dissertação. No capítulo 2 focamo-nos nas necessidades não satisfeitas em DHR. O manuscrito 1 é uma carta de posicionamento do Grupo de Oftalmogenética da Sociedade Portuguesa de Oftalmologia onde identificamos 4 necessidades fulcrais, bem como soluções para as endereçar. O Manuscrito 2 é uma carta de posicionamento da *European Reference Network for Rare Eye Diseases* onde destacamos a necessidade de disponibilizar globalmente testes genéticos em doenças oftalmológicas raras, incluindo as DHR. Os manuscritos 3 e 4 cobrem uma necessidade muito específica no campo das doenças raras: registos de doentes. Descrevemos o desenho, desenvolvimento e implementação do IRD-PT, um registo nacional e interoperável para DHR; e discutimos desafios, facilitadores e barreiras à sua adoção no nosso país. O papel dos mídias digitais, em particular do *Instagram*, como veículo de sensibilização e educação médica em DHR é o tópico do manuscrito 5. Finalmente, o manuscrito 6 descreve aquela que era uma necessidade não satisfeita e se tornou numa conquista para a Oftalmologia nacional – a aprovação do Voretigene Neparvovec em Portugal e o tratamento da primeira doente portuguesa com esta inovadora terapia.

O capítulo 3 é composto por vários estudos clínicos e moleculares, com especial ênfase na retinopatia pigmentar (RP), a DHR mais prevalente. O manuscrito 7 descreve a importância de fatores clínicos/demográficos, avaliação funcional e imagiologia multimodal no aconselhamento genético pré-teste de indivíduos com RP. Demonstrámos que o início de sintomas em idade precoce, a consanguinidade, a evidência de um padrão de hereditariedade e a ausência de indicadores de fenocópias impactam de forma positiva o rendimento diagnóstico do teste genético. Os manuscritos 8 e 9 descrevem o espetro mutacional e características

imagiológicas das DHR associadas ao gene *EYS*, com especial foco nos fenótipos atípicos. Descrevemos 12 novas variantes clinicamente significativas neste gene, a causa mais frequente de DHR em Portugal. O foco do manuscrito 10 é a RP ligada ao X, em particular o espectro genético e fenótipo retiniano de mulheres heterozigotas para o gene *RPGR*. Expandimos o espectro mutacional do gene *RPGR* reportando 3 novas variantes: 2 provavelmente patogénicas localizadas na região ORF15 e 1 patogénica localizada no exão 11. Adicionalmente, demonstrámos que o fenótipo masculino não é infrequente, acentuando a necessidade de testar para RP ligada ao X (inclusive a região ORF15) mesmo em famílias com mulheres afetadas. O manuscrito 11 avalia a frequência de edema macular cistóide e alterações da interface vítreo-retiniana em doentes com RP síndrómica e não síndrómica. Devido ao risco de perda de visão central e à possibilidade de tratamento, destacamos a importância de avaliar estas condições. Finalmente, no manuscrito 12 utilizámos imagiologia retiniana multimodal para caracterizar o fenótipo retiniano de uma população com Pseudoxanthoma elasticum (PXE). Pela primeira vez, reportámos a prevalência e a história natural da neovascularização macular não exsudativa, destacando o papel da angiografia por tomografia de coerência ótica no seguimento do PXE.

O capítulo 4 é dedicado a *patient-reported outcomes*. No manuscrito 13 descrevemos a tradução e validação linguística do *Michigan Retinal Degeneration Questionnaire* e do *Michigan Vision-related Anxiety Questionnaire*; enquanto que os resultados da sua aplicação numa população com distrofia retiniana associada ao gene *EYS* são descritos no manuscrito 14.

Os manuscritos que compõem o capítulo 5 são exemplos da utilidade da imagiologia retiniana multimodal nas DHR, ilustrando alterações retinianas em fenótipos incomuns.

Por fim, o capítulo 6 elabora nos achados principais deste projeto e na relevância clínica/implicações futuras para doentes com DHR.

## **CHAPTER I: GENERAL INTRODUCTION**





## **I. GENERAL INTRODUCTION**

### **I.1. Background**

Inherited retinal dystrophies/degenerations (IRDs) are a group of clinically and genetically heterogeneous rare eye diseases with a global caseload in the range of 5–10 million individuals.<sup>1</sup> Despite the low prevalence (~1:3,000 individuals),<sup>2</sup> IRDs are among the most important causes of severe visual impairment and blindness in children and working-age adults in developed countries,<sup>3,4</sup> thus posing a significant psychosocial and economic burden and gravely impacting quality of life (QoL).<sup>5-7</sup> Individuals living with an IRD incur significant economic costs. The societal cost of IRDs (comprising both economic costs and wellbeing costs) in the United Kingdom (UK) and the United States (US) were estimated at more than 530 million pounds (USD 700 million) and USD 30 billion, respectively.<sup>8,9</sup> Most strikingly, wellbeing costs represent a significant parcel of these costs: 37% and 63% in UK and the US, respectively.<sup>8</sup> Since vision loss from IRDs often manifests in childhood, some people live with vision impairment and blindness for their whole lives.

Because of the phenotypic overlap, establishing a final diagnosis based solely on clinical findings and multimodal imaging is often extremely difficult. On the other hand, the remarkable genetic heterogeneity characterizing IRDs used to be a significant challenge in ascertaining a molecular diagnosis. Major breakthroughs in molecular biology techniques have enabled significant progress in defining the molecular pathogenesis of these disorders,<sup>10</sup> and there are currently 316 genes and loci listed with established links to IRDs (RetNet database: <https://sph.uth.edu/retnet/home.htm>). The advent of next-generation sequencing (NGS) revolutionized genetic testing in IRDs,<sup>5,10-12</sup> contributing to a reduction in time and costs for the molecular diagnosis and facilitating its widespread availability.<sup>10</sup> However, this wealth of information is only slowly being translated into genetic diagnoses for individual patients, as significant barriers to testing still exist all over the world. Geographical inequity in access to genetic testing has already been identified across the world,<sup>13-15</sup> and Portugal is no exception.<sup>16</sup> A recent survey from the European Vision Institute for Clinical Research Network (EVICR.net)<sup>17</sup> emphasized the significant heterogeneity between centers and across countries regarding the current management of IRD patients in Europe. This applies not only to genetic testing and genetic counselling, but also to referral pathways, access to expert centers, ancillary diagnostic tests, among others. Offering IRD patients genetic testing and genetic counseling within routine mainstream clinical care represents a considerable challenge with inherent costs.<sup>18</sup> However, genetic testing improves the chance of establishing a precise diagnosis, identifies features not previously determined (e.g. syndromic forms), improves counselling (e.g. understanding

prognosis; facilitating reproductive decision-making), and is increasingly important in directing treatment options.<sup>19</sup>

## 1.2. Genetics of IRDs

Most IRDs are monogenic phenotypes with a Mendelian inheritance – autosomal recessive (AR), autosomal dominant (AD) and X-linked (XL). However, the genetic analysis of IRDs is not always straightforward due to the contribution of overlapping causative genes and phenotypes. Several IRD phenotypes (e.g. non syndromic retinitis pigmentosa, RP) can be caused by sequence variants in different genes and the same gene may be associated with different phenotypes (e.g. *PRPH2*). Additionally, a growing number of genes are now known to cause both AR and AD-associated disease (e.g. *PROM1* or *GUCY2D*) and, in some cases, even the same pathogenic variants have been linked to both AR and AD inheritance patterns.<sup>20</sup> Although for some cases the mechanism is fully understood, in others there is currently no explanation for this phenomenon. The genetic complexity of IRDs is further increased due to some cases of digenic biallelic inheritance (e.g. sequence variants in *ROM1* and *PRPH2*), di-genic triallelic inheritance (e.g. in some families with Bardet-Biedl syndrome and achromatopsia), and mitochondrial inheritance.

Population-based analyses estimate that at least one out of three individuals worldwide is heterozygous for at least one recessive IRD-causing variant.<sup>1,20</sup> Still, given the total number of IRD-associated genes, the odds that two individuals carry disease-causing variants in the same gene are small, keeping IRD prevalence relatively low (~1:3000). However, a similar proportion of IRD patients (1:3) carry, by chance, a heterozygous recessive variant that is not the cause of disease but might modulate its severity.<sup>21</sup> Accordingly, careful interpretation and clinical context is imperative when receiving genetic results.

Pathogenic variants in five genes (*ABCA4*, *USH2A*, *EYS*, *RPGR*, and *CRB1*) make up ~50% of IRD-causing variants in the Global Retinal Inherited Disease (GRID) dataset, a compilation of published IRD cohort papers from around the world.<sup>20</sup> The dataset included 4,798 discrete variants and 17,299 alleles in 194 genes published in 31 papers describing large IRD cohorts. Despite some common ground, IRD genetic profiles have been shown to vary considerably among regions and ethnic groups,<sup>2,22</sup> underscoring the importance of obtaining reference population-based data. The GRID dataset<sup>20</sup> collected genetic information from studies conducted mostly in North America and Europe and therefore might be biased by over-represented founder pathogenic variants in these populations. Population-specific founder pathogenic variants represent young variants (hundreds to thousands years old) that can be found in high frequency in one specific population and are often absent or extremely rare in

other populations.<sup>23</sup> Among the most common IRD pathogenic variants in the GRID dataset, 29 are panethnic (identified in all or most of the populations represented in gnomAD), 33 are multiethnic (identified in 2–3 different populations), and 45 are population-specific.<sup>20</sup>

A relatively large percentage of IRD patients (30–40%) remain genetically unsolved even after state-of-the-art genetic testing, including whole exome and whole genome sequencing (WES and WGS, respectively).<sup>12</sup> Different pathogenic variant detection rates (diagnostic yields) are observed in different IRD phenotypes.<sup>24</sup> Possible reasons include (1) phenotypes with a higher proportion of overall identified genes (e.g. Usher syndrome versus nonsyndromic RP); (2) smaller number of candidate genes in more specific phenotypes; and (3) phenotypes that are predominantly recessive tend to have higher pathogenic variant detection rates.<sup>24</sup> Furthermore, undetected/unknown genotypes (e.g. hypomorphic variants; variants within non-coding regions or variants in genes that have not yet been associated with IRDs),<sup>24-27</sup> or an incorrect clinical diagnosis (i.e. disease entities that mimic IRDs such as paraneoplastic retinopathy, inflammation, infection or autoimmune disease)<sup>28,29</sup> are also possible explanations for a negative genetic testing result.

### **1.3. IRD signs and symptoms**

Signs and symptoms of IRDs are quite varied and depend upon the degree of involvement of the two main arms of retinal function. When rod-driven function is predominantly involved, impaired night vision (nyctalopia) is usually the first symptom, followed by visual field constriction. On the other hand, cone-dominant disease will lead to impaired visual acuity and color vision, photophobia and, in severe and early-onset cases, also nystagmus. Generally, rod dominant disease usually causes increased difficulty when shifting from a well-lit to a darker environment, while in cone-dominant disease the opposite is true.<sup>20</sup> Chorioretinal degenerations are characterized by early degeneration of the retinal pigment epithelium (RPE) that progresses to involve the choriocapillaris, Haller and Sattler layers of the choroid, and the photoreceptors in the later stages.<sup>30</sup> The clinical presentation varies depending on the disease and may involve loss of central vision (e.g. central areolar choroidal dystrophy) or nyctalopia and progressive loss of peripheral vision in gyrate atrophy and choroideremia.

IRDs involving the macula, including Stargardt disease (STGD), Best vitelliform macular dystrophy (BVMD), and pattern dystrophies usually overlap with a multitude of acquired diseases (e.g. age-related macular degeneration, central serous chorioretinopathy, etc).<sup>30</sup> Symptoms such as metamorphopsia, reduced visual acuity, and progressive central and paracentral scotomata are predominant, while the peripheral vision is typically spared.<sup>30</sup> The reasons for their predilection for the macula remain unclear.

Still, symptoms are not always this straightforward as many patients present both rod- and cone-system compromise and clinical manifestations may change throughout the patient's life. Early recognition of clinical clues/red flags like abnormal visual behavior and nystagmus in preverbal children; or low vision, constricted visual fields, nyctalopia and photophobia in children, adolescents or young adults is crucial for a timely referral to an IRD expert center where patients can be adequately diagnosed, genotyped and ultimately treated.<sup>31</sup>

#### **1.4. IRD Phenotypes**

The genetic heterogeneity and complexity of IRDs is matched by their phenotypic diversity. Thus far, more than 50 major subtypes of IRDs have been described.<sup>20</sup> Several IRD phenotype classification systems exist but none is universally accepted. IRDs may be developmental (e.g. foveal hypoplasia), manifest at birth or soon after birth (e.g.: Leber congenital amaurosis, LCA), or appear later in life, occasionally even at the 5<sup>th</sup>, 6<sup>th</sup> or 7<sup>th</sup> decades (e.g. Late-onset retinal degeneration, L-ORD). Additionally, IRDs may be progressive or non-progressive (stationary), diffuse or restricted to the macula or far periphery. While in most cases IRDs are limited to the eye (nonsyndromic) and caused by variants in retina-specific genes, over 80 forms of syndromic IRD have been described.<sup>32</sup> Syndromic IRDs can be further classified into one of two major disease groups: inborn errors of metabolism and ciliopathies, and the majority are recessively inherited and rare.<sup>33</sup> In cases of syndromic IRDs, a timely diagnosis and appropriate multidisciplinary management is essential.<sup>34</sup> Not infrequently, syndromic cases are revealed only after genetic testing, underscoring the importance of a molecular diagnosis in IRDs.

After a rare eye disease ontology meeting and expert consensus, the European Reference Network for Rare Eye Diseases (ERN-EYE) proposed a broader group classification for IRDs<sup>35</sup> based on the Orphanet Rare Disease Ontology (ORDO). This included: (a) stationary non-syndromic photoreceptor dystrophies; (b) progressive non-syndromic photoreceptor dystrophies; (c) syndromic retinal dystrophies; (d) macular dystrophies; (e) choroidal dystrophies; and (f) hereditary vitreoretinopathies. Another simplified classification is provided by Fenner et al,<sup>30</sup> claiming that the majority of IRDs can be classified as one of four broad subtypes: (1) rod-cone degenerations; (2) cone-rod degenerations; (3) chorioretinal degenerations; and (4) degenerations involving the macula. Stone et al<sup>36</sup> proposed a classification containing 3 main branches (I – Photoreceptor Diseases; II – Macular Diseases; III – Third-branch Disorders) and several diagnostic categories within each branch. On the latter two grouping schemes, syndromic IRDs are included under the most relevant umbrella classification. The major limitation of these broader phenotypical classifications is that a correlation with a specific gene is not always straightforward. The same gene may be associated with phenotypes from

different groups (e.g. *ABCA4* is usually associated with STGD but it may cause RP or cone-rod degeneration). Additionally, some genes may cause either syndromic or nonsyndromic disease (e.g. *USH2A* gene is associated with both Usher syndrome and nonsyndromic RP). Last but not least, many phenotypes actually lie along a spectrum, varying in manifestations along the course of disease and as a function of modifying genetic and environmental factors. As such, even within affected members from the same family that share the same genetic cause, one can often find phenotypic variability.<sup>20</sup> Over the last years, a trend towards a genotype-based classification of IRDs is being observed. Here, the gene assumes a central role and the associated phenotypes associated with that gene are listed (e.g. *PRPH2*-associated central areolar choroidal dystrophy or *PRPH2*-associated rod-cone degeneration).

Both inter- and intrafamilial clinical variability is known to exist among individuals who share the same causative genotype. The reason behind this phenotypical variability is largely unknown and many researchers have speculated that both environmental as well as genetic modifier alleles contribute to this phenomenon.<sup>20,21</sup> Since ~1:3 individuals worldwide is expected to be a carrier of an AR sequence variant associated with an IRD, a similar proportion of affected individuals with clinically significant variants in a specific gene probably carry an AR IRD variant in other gene(s) just by chance.<sup>1,20</sup> Analyzing large cohorts holds promise for clarification of the role of potentially modifier genes.

## **1.5. Deep Phenotyping**

Deep phenotyping by means of retinal imaging,<sup>37-39</sup> electrodiagnosis<sup>40</sup> and other functional assessments (visual acuity, visual fields, etc)<sup>41,42</sup> is key for establishing a clinical diagnosis of IRD. With the recent approval of the first gene therapy drug (Voretigene Neparvovec) and several other therapies in the pipeline, the role of deep phenotyping in IRDs cannot be overemphasized. Although predicting the genetic cause solely by phenotype is seldom possible, multimodal assessment of retinal architectural integrity is vital to explore disease natural history, monitor disease progression, advise patients on their disease prognosis, elucidate disease mechanisms/pathogenesis, stratify patients and evaluate treatment efficacy.<sup>37</sup> Reliable and repeatable measurements are essential to identify who to treat and when to treat, and to establish structural biomarkers.<sup>43</sup>

Since its debut in 1988, optical coherence tomography (OCT) has become the most valuable tool for retinal structural assessment, providing an *in vivo* cross-sectional view of the retina that has revolutionized clinical and academic practice.<sup>44</sup> With improvements in acquisition time and resolution, OCT enables both a qualitative assessment of multiple retinal layers, and repeatable quantitative/volumetric measurements.<sup>37</sup> The ability to accurately determine

anatomical degeneration has transformed disease characterization in IRDs. Useful OCT features include volumetric analysis and thickness assessments. Parameters such as central foveal thickness, central outer nuclear layer thickness, choroidal thickness and macular volume are easily quantified with OCT. Ellipsoid zone (EZ) area and width are metrics of great value for elucidating disease natural history and currently used as structural endpoints in clinical trials for different IRDs, such as rod-cone degeneration (RP and Leber congenital amaurosis), cone-rod degeneration or STGD.<sup>43</sup> In fact, measuring the EZ remains one of the most sensitive ways of tracking the progression in rod-cone degeneration.<sup>45</sup> Structural-functional correlations between OCT features and functional testing (such as visual acuity or visual field testing) are well established.<sup>46,47</sup> Furthermore, OCT is able to reveal countless phenotypic features that may complicate IRDs such as vitreomacular interface disorders, cystoid macular edema, choroidal neovascularization, or outer retinal tubulations.<sup>48-50</sup> Other OCT features may point towards a specific diagnosis, such as foveoschisis in X-linked retinoschisis, outer retinal hyperreflective deposits in Retinitis Punctata Albescens and Fundus Albipunctatus, or retinal and choroidal crystalline deposits in Bietti Crystalline Dystrophy. A present challenge regarding OCT analysis in patients with IRDs (particularly those with extensive macular atrophy, e.g. STGD) is that automated retinal layer segmentation tends to be unreliable when retinal architecture is altered, requiring time consuming manual correction.<sup>51</sup> OCT can also be employed intraoperatively to facilitate optimal targeting and safe treatment delivery in subretinal injections of gene therapy products in IRDs. With intraoperative OCT, surgeons can confirm the correct placement of the injection cannula and document the bleb formation in real-time.<sup>52</sup>

Color fundus photography (CFP) has been used for a long time to document the retinal appearance. Before its introduction around the end of the 19<sup>th</sup> century, clinicians used drawings for the exact same purpose. Nowadays, a broad range of digital and widefield options is available with an optical angle of view ranging from 20° (particularly used to image the optic disc) to 200° (ultra-widefield, UWF), covering approximately 80% of the retina.<sup>37,38,53</sup>

Fundus autofluorescence (FAF) has become a key tool to diagnose and monitor the progression of IRDs, due to its capacity of revealing the retina's health and metabolism, while providing valuable insights into disease pathophysiology.<sup>37</sup> Lipofuscin is an endogenous fluorophore that can be found in most eukaryotic cells, and in the eye is predominantly located in the RPE. The autofluorescence signal corresponds to the concentration of lipofuscin and other secondary fluorophores, which also relates to the pace at which photoreceptor outer segments are metabolized by the RPE cells.<sup>54</sup> Hypoautofluorescence can be due to a reduced concentration of lipofuscin (e.g. *RPE65*-associated retinal degeneration), RPE atrophy (e.g. macular atrophy in STGD), fibrotic tissue (e.g. late-stage BVMD) or signal absorption by cells or extracellular material overlying the RPE. On the other hand, hyperautofluorescence can be explained by an

increase in lipofuscin (e.g. flecks in STGD or vitelliform deposits in *BEST1/PRPH2*-associated retinal degeneration), intraretinal fluid (e.g. cystoid macular edema), some types of drusen (e.g. *EFEMP1*-autosomal dominant drusen) or window defects (pseudocoloboma/macular dysplasia in *NMNAT1*-associated retinal degeneration). A parafoveal hyperautofluorescent ring can be observed in both cone-rod and rod-cone dystrophies and it is likely to represent ongoing RPE/photoreceptor stress and an intermediate stage before cell loss.<sup>55,56</sup> Sequential measurements (e.g. ring area or greatest linear dimension) can quantify disease progression (either its expansion in cone-rod, or constriction in rod-cone dystrophies).<sup>37</sup> UWF-FAF allows better identification of the magnitude and extent of mid-peripheral and far-peripheral retinal involvement and is increasingly being used to create disease classifications (e.g. *ABCA4*-associated retinal degeneration, *ABCC6*-associated retinal degeneration or *RPGR* heterozygotes)<sup>38,57,58</sup> or identify atypical phenotypes (e.g. sector RP).<sup>27,59-62</sup>

Psychophysical tests that help characterize visual and retinal function in IRDs include visual acuity (VA), color vision testing, dark adaptometry, contrast sensitivity, and various forms of light- as well as dark-adapted perimetry. While highly dependent on patient compliance and abilities, these tests often contribute to determine disease phenotype and severity.<sup>20,41</sup> VA represents the ocular spatial resolving capacity. Quantification of VA is usually the first assessment in clinic and an essential parameter in the evaluation of the function and integrity of the visual system. Best-corrected VA (BCVA) has been shown to significantly correlate with the width and integrity of the EZ on OCT,<sup>63</sup> as well as with visual field.<sup>64,65</sup> However, correlation between VA and structural measures is not always straightforward, as both better or worse results are sometimes observed, with a notable disconnect from what would be predicted from anatomy alone (e.g. *RDH12* and *CEP290* genotypes).<sup>41</sup>

Visual field evaluation, using kinetic or static perimetry, is a key component in the functional evaluation of an IRD patient. Loss of peripheral visual field, as frequently observed in rod-cone degeneration, results in symptoms such as tripping, bumping into people/obstacles, struggling to find objects, or difficulty navigating in dim or crowded/unfamiliar environments. In contrast, loss of central field is commonly observed in cone-dominant degenerations and macular dystrophies, leading to difficulties in recognizing faces, reading signs and identifying objects. VA and visual field testing are outcome measures in all IRD trials and remain the most important measures when the degree of handicap and the need for support must be established.

Another important functional test is full-field stimulus testing (FST), which can evaluate visual function even in patients with profound vision loss (e.g. LCA). FST measures the sensitivity of the entire visual field by providing an estimation of the lowest level of luminance that elicits a visual sensation by the subject.<sup>42</sup> Stimuli of varying luminance are presented according to a prespecified algorithm and the patient presses a button when a visual sensation is perceived. It

can present varying colors to preferentially test different photoreceptor subsets, or be undertaken following dark adaptation to distinguish between cone and rod deficits.<sup>30</sup> FST is currently the single most valued outcome when assessing the efficacy of treatment with Voretigene Neparvovec.<sup>66,67</sup>

Electrophysiological testing provides an objective measure of retinal and RPE function and can significantly contribute to decipher the nature and degree of retinal involvement. Standardized procedures by the International Society for Clinical Electrophysiology of Vision (ISCEV) are in place so that electrophysiology results can be meaningfully interpreted and compared worldwide.<sup>68</sup> Full-field electroretinography (ffERG) allows to differentiate between rod-dominated, cone-dominated and mixed involvement of the two photoreceptor pathways, and often reveals the presence of disease before funduscopy findings become apparent.<sup>20</sup> The ffERG is a measure of the entire retinal function, which means that loss of function from focal lesions, including the macula, is averaged with the remainder of the retinal function and the focal functional significance is often not demonstrated. To overcome this limitation, standard topographical retinal testing has been developed: pattern ERG (PERG) and multifocal ERG (mfERG).<sup>40</sup> The electro-oculogram (EOG) assesses generalized RPE function as there is a potential difference between the basal and apical surface of the RPE of about 60 mV.<sup>40</sup> There are a small group of disorders with a normal ffERG and an abnormal EOG, the most important of which is Best vitelliform macular dystrophy. Lastly, flash and pattern visual evoked potentials allow for the assessment of the integrity of the visual pathways and visual cortex as well as serving to estimate visual acuity.<sup>20</sup> Several IRDs have specific visual electrophysiology changes that are pathognomonic and correlate with genotype.<sup>40,69</sup> These include *KCNV2* retinopathy (cone dystrophy with supernormal rod responses), congenital stationary night blindness and enhanced S-cone syndrome. In the era of genetic testing, visual electrophysiology still has two broad roles: (1) it provides functional results that assist in localizing the defect to a particular retinal cell type and thus a diagnostic group; and (2) it assists in interpreting molecular genetic results by conveying structure–function outcomes.<sup>40</sup> This commonly involves confirming that the identified molecular genetic change is consistent with the patient phenotype. Additionally, it may assist in interpreting variants of uncertain significance (VUS) and contribute to a change in classification of these variants.<sup>70</sup>

## **1.6. Genotype-Phenotype Correlations**

While clinical examination and the various ancillary tests described above help defining the phenotype and can guide the molecular genetic search for the causative gene defect, predicting the genetic cause solely by phenotype is seldom possible.<sup>20</sup> Clinical findings of most



IRDs are rarely pathognomonic of a particular genetic defect, making genotype-phenotype correlations very difficult to establish. Still, some clear-cut genotype-phenotype correlations are well established. One example is with *GUCY2D*-associated retinal degeneration. While most *GUCY2D* clinically significant variants cause AR-LCA, in-frame and mainly missense variants in a specific protein motif cause AD cone-dominated disease.<sup>71</sup> Another example is *USH2A*-associated retinal degeneration. The presence of at least one 'retinal disease-specific' *USH2A* pathogenic variant (mainly missense variants) in a patient with *USH2A*-associated retinal degeneration results in nonsyndromic RP, ie with preserved, normal hearing.<sup>72</sup>

### **1.7. Disease Awareness and Education**

Like many rare diseases, IRDs are too often neglected, to a large extent because of misinformation and/or insufficient medical knowledge. This in turn puts a barrier to timely diagnosis and deprives affected individuals from the support they need, be it clinical, financial, educational or social. Thus, it is crucial to raise awareness and educate decision/policy-makers, the general public, clinicians, and other healthcare workers for these visually incapacitating diseases. Only with this background work can patients be granted full clinical, familial, social and economic support.

Ophthalmologists, pediatricians and general practitioners (GP) are usually the first clinicians to encounter an IRD patient, thus making up the group where targeted educational actions are most needed. The IRD patient journey is usually a burdensome diagnostic odyssey leading to multiple rounds of referrals that does not always mean access to specialist services. Rare disease patients are estimated to see up to 8 physicians and receive up to 3 misdiagnosis over the course of 5-7 years before the correct diagnosis is established.<sup>73</sup> This delay must be reduced or eliminated in order to prevent irreparable vision loss, lost opportunities to receive current and emerging treatments or harm to a patient's general health in cases of syndromic IRDs.

Recognizing clinical clues/red flags like nystagmus, low vision, constricted visual field, nyctalopia and photophobia is crucial for a timely referral to an IRD expert center. In preverbal children, abnormal visual behavior and nystagmus observed and reported by the parents should prompt an appropriate ophthalmological workup for IRD.<sup>31</sup>

Medical education has grown beyond the boundaries of the classroom. The explosive rise of social media platforms revolutionized the learning experience, creating different ways of sharing knowledge and making it readily and widely available. Academic departments, medical associations, and medical journals are using social media to broadcast research advances, increase visibility and engage with a global audience. A recent study has shown that citation rate

has a moderate positive correlation with online and social media sharing of research in ophthalmology literature.<sup>74</sup>

Social media channels offer an avenue to engage with audiences in an unprecedented manner, allowing for communication and education on a larger and more rapid scale than traditional print methods.<sup>75</sup> Given the daily amount of time that people spend on social media, this creates a window of opportunity to promote disease awareness and medical education in IRDs.<sup>76</sup>

## **1.8. Patient registries**

Clinical registries have existed for decades in the field of ophthalmology,<sup>77-80</sup> serving a variety of purposes, including (1) capturing the epidemiologic features of an ocular disease or condition, (2) tracking outcomes and complications of drugs or procedures, (3) recording adverse events, or (4) combinations of the above.<sup>81</sup> In recent years, policy makers started recognizing clinical registries as an important tool for improving the value of healthcare. The development of multicenter patient registries promotes the generation of scientific knowledge by using real-world data. Additionally, clinical registries are increasingly being used to establish research collaborations.<sup>82</sup> This is particularly important in rare diseases where the small number of cases creates additional barriers to the translational research pathway, making identification and establishment of a substantial cohort a very difficult task. Data from multicenter registries can be used to fill in gaps of evidence that cannot be provided by randomized controlled trials. As rare diseases gain visibility as a public health priority and the marketplace expands, acknowledgement of the importance of building collaborative relationships in rare disease research increases.<sup>82</sup> Rare disease registries increase research accessibility for patients, while providing clinicians/investigators with a coherent data ecosystem necessary to boost research and patient care. Furthermore, patient registries support formal partnerships with investigators and stakeholders in the global aim to develop high-value, high-utility research.<sup>83</sup> While local hospital-based rare disease registries may provide high quality information, their coverage is usually small, underscoring the need to develop multicenter IRD registries or combine existing registries.

## **1.9. Patient-Reported Outcomes**

Visual impairment has a profound impact on the affected individual, ranging from mental health and QoL to equality, social inclusion or access to education, during childhood and beyond.<sup>84</sup> These effects usually reach beyond the individual to family members and/or caregivers,

who may struggle to adjust to new caretaking and supportive roles.<sup>73,85,86</sup> Self-perceived health has been more strongly associated with QoL than traditional clinical tests, suggesting that a patient's perception of his/her quality of vision may be more impactful on his/her QoL. Not surprisingly, individual QoL is one of the seven areas of emphasis of the 2021 National Eye Institute (NEI) Strategic Plan<sup>87,88</sup>. NEI's director Michael F. Chiang highlights the importance of incorporating patient perspectives in vision-related QoL assessments for clinical research studies and PROs for measuring quality of care.<sup>88</sup> This is particularly important in IRDs since it remains difficult to detect therapeutic improvement using standard objective visual function testing<sup>89</sup>, in spite of the recent growth in clinical trials evaluating treatments for these conditions.<sup>90</sup> In fact, clinical trials for therapies targeting IRDs have several obstacles to overcome: (1) the rarity of these maladies, making multi-center trials a necessity; (2) the diversity of genotypes and low accessibility to genetic testing in many parts of the world; and (3) the variable expression of phenotype, making standardized outcome measuring a complex endeavor. To facilitate in the goal of assessing the efficacy of current and future therapies and investigating IRDs natural history in a precise, standardized manner, patient-reported outcomes (PRO), obtained from valid and reliable questionnaires, are essential.<sup>89</sup> PRO instruments are valuable indicators of a patient's QoL, functioning or disability from his/her own perspective, and are recognized as valid clinical trial outcome measures.<sup>91</sup>

The Michigan Retinal Degeneration Questionnaire (MRDQ)<sup>92</sup> and the Michigan Vision-Related Anxiety Questionnaire (MVAQ)<sup>93</sup> are two psychometrically validated PRO measures specifically designed for use in IRD gene therapy trials.

MRDQ measures the impact of visual handicap in daily tasks across five different dimensions: reading; color and contrast; dark adaptation; mobility and peripheral vision; and light sensitivity<sup>92</sup>; while MVAQ measures anxiety caused by the lack of sufficient visual function to perform these activities/tasks<sup>93</sup>. MRDQ and MVAQ can be used to monitor vision-related quality of life changes over time, and therefore are adequate tools to monitor disease progression and treatment impact both in clinical practice and in clinical trial settings. The use of MRDQ and MVAQ in a pediatric sample lacks validation. However, studies are in progress to fulfill this need to holistically evaluate the efficacy of an intervention in children with IRD.<sup>94</sup>

### **1.10. Current and future therapeutic interventions**

Although rare in the general population, IRDs occupy a crucial position in current efforts to develop innovative therapies for blinding diseases. Genomic data is already influencing medical decision making for a diverse and growing group of patients, offering the possibility of an early diagnosis and establishment of gene-directed therapies.<sup>30,95,96</sup>

IRD therapies are usually divided into two major groups: gene-dependent, for which information about the causative gene and sometimes the particular causing variant/s for each patient is needed,<sup>95,97</sup> versus global approaches that might be beneficial to many IRD cases, irrespective of their genetic etiology, but are likely to be more appropriate to individuals with end-stage disease.<sup>20</sup> The latter include mutation-agnostic gene therapies, cell therapies, optogenetics, stem cell-based therapies, retinal implants and neurotrophic factors for neuroprotection.<sup>20,30,98-101</sup> However, only one therapy has been granted approval so far. Voretigene neparvovec (AAV2-hRPE65v2)<sup>66,67</sup> received Food and Drug Administration (FDA) authorization for the treatment of patients with *RPE65*-related retinal dystrophy presenting with biallelic mutations in late 2017, becoming the first gene therapy for inherited blindness to receive FDA approval. This was a significant milestone for ophthalmology in particular and modern medicine in general, as Voretigene Neparvovec was also the first *in vivo* gene therapy ever approved. Treatment is directed at *RPE65*-associated retinal degeneration, a severe form of inherited retinal blindness. Gene augmentation therapy delivers a normal copy of the native human *RPE65* cDNA to the diseased RPE cells after subretinal injection of a recombinant adeno-associated virus (AAV).<sup>102</sup> Improved light sensitivity, visual field, and navigational ability under dim lighting conditions were reported, with preservation of the clinically meaningful effect for at least 4 years.<sup>66</sup> In November 2018, the European Medicines Agency (EMA) granted Novartis AG<sup>®</sup> marketing authorization for the use of Voretigene Neparvovec in Europe. Unfortunately, the high cost and country-specific regulations still hamper its widespread use, creating treatment access inequalities both in Europe and in rest the world.

The *RPE65* gene is expressed in the RPE and plays a key role in the retinoid cycle as it encodes retinoid isomerohydrolase, an enzyme that regenerates *11-cis* retinal.<sup>103</sup> Biallelic loss-of-function mutations in the *RPE65* gene result in either a lack of *RPE65* protein or protein that is non-functional. Without this important protein, phototransduction in photoreceptor cells is impaired, resulting in severe photoreceptor degeneration and ultimately death.<sup>102</sup> Like many IRDs, *RPE65* mutation-associated retinal degeneration can be heterogenous, with a phenotypic continuum modulated by disease severity. Severe visual impairment or blindness is usually present from birth or in early childhood, a clinical presentation that falls within the LCA/early-onset retinal degeneration (EORD) spectrum. Although the true prevalence of *RPE65*-associated disease is unknown, estimates point towards an overall prevalence of 1 per 300,000 individuals.<sup>9,104,105</sup> *RPE65* is believed to account for 5-6% of LCA cases and 2-5% of AR RP cases.<sup>106</sup>

Not only has this newly approved therapy changed the lives of people previously destined to live a life of blindness, but it has fueled interest in developing additional gene therapy reagents targeting numerous other genetic forms of inherited retinal disease.<sup>102</sup> Other possible therapies are currently in clinical trial phase<sup>30,95,96</sup> and will hopefully be available in a not so distant

future. It is thus of the utmost importance to offer a molecular diagnosis to all IRD patients and to create national registries of IRDs to easily identify patients eligible to participate in clinical trials or receive newly approved therapies. Although restoring normal vision is likely an utopia, any visual acuity, visual field, and/or light sensitivity that is retained or improved with treatment is significant and may partly ameliorate the psychosocial impact of progressive vision loss, with an inestimable reduction in wellbeing and overall costs.<sup>107</sup>

While available treatment options are currently scarce, managing associated ocular comorbidities such as refractive errors, amblyopia, strabismus, keratoconus, cataract, cystoid macular edema, vitreomacular interface disorders, macular neovascularization, ocular hypertension/glaucoma, among others, is critical. Most importantly, referral to a low vision clinic to maximize the residual vision with near and distance visual aids, learn braille and/or improve navigational skills, orientation and mobility with a cane are important strategies that can significantly ameliorate IRD patients' QoL.<sup>108</sup>

### **1.1.1. Aims and Outline of this Thesis**

The global aim of the IRD-PT study was to improve the understanding of the clinical and molecular characteristics of IRDs in Portugal. First, IRD-related unmet needs were identified, along with reasonable solutions to address them, in an effort to move the field forward. One of these unmet needs and a pivotal part of this project was the design, development and deployment of a national IRD registry – the IRD-PT.<sup>83</sup> This registry served as a foundation to the clinical and molecular studies that compose this thesis. Additionally, two IRD-specific PRO measures were translated to Portuguese and subsequent application of these instruments was achieved,<sup>109</sup> demonstrating its clinical utility. Finally, in an effort to increase disease awareness and improve medical education in the field of IRDs, an Instagram® account (@retinaldystrophies) was created.<sup>76</sup> The implementation of the several steps of the IRD-PT study culminated in the treatment of the first Portuguese patient with Voretigene Neparvovec, a giant leap to Portuguese Ophthalmology.<sup>110</sup>

After a general introduction (Chapter 1), IRD-related unmet needs are the focus of Chapter 2, while Chapter 3 presents clinical and molecular studies with a special emphasis on RP, the single most prevalent IRD phenotype. Chapter 4 is dedicated to IRD-specific PRO measures and Chapter 5 presents a few outstanding examples of ophthalmic images in IRDs. Chapter 6 provides a general discussion of the studies described in this thesis, placing them in a broader, future perspective.

Overall, we present 21 manuscripts published in peer-reviewed journals. The published manuscripts' title, article type, journal, CiteScore and quartile are shown in Table I (source: Scopus).

**Table I.** Overview of the publications

<b>Title</b>	<b>Article Type</b>	<b>Journal</b>	<b>CiteScore</b>	<b>Quartile</b>
<i>Inherited Retinal Degenerations in Portugal: Addressing the Unmet Needs</i>	Perspective	<i>Acta Médica Portuguesa</i>	1.8	Q3 Medicine
<i>The need for widely available genomic testing in rare eye diseases: an ERN-EYE position statement</i>	Position Statement	<i>Orphanet Journal of Rare Diseases</i>	5.2	Q1 Medicine Q2 Genetics
<i>Design, development and deployment of a web-based interoperable registry for Inherited Retinal Dystrophies in Portugal – The IRD-PT</i>	Original Article	<i>Orphanet Journal of Rare Diseases</i>	5.2	Q1 Medicine Q2 Genetics
<i>Challenges, facilitators and barriers to the adoption and use of a web-based national IRD registry: lessons learned from the IRD-PT registry</i>	Letter	<i>Orphanet Journal of Rare Diseases</i>	5.2	Q1 Medicine Q2 Genetics
<i>Instagram as a vehicle to promote disease awareness and medical education in #retinaldystrophies</i>	Letter	<i>Postgraduate Medical Journal</i>	4.1	Q2 Medicine
<i>Treating the first Portuguese patient with Luxturna: A small step for world science, a giant leap for Portuguese Ophthalmology</i>	Letter	<i>Oftalmologia</i>	NA	NA
<i>Clinical/demographic, functional testing and multimodal imaging differences between genetically solved and unsolved Retinitis Pigmentosa</i>	Original article	<i>Ophthalmologica</i>	5.1	Q1 Ophthalmology
<i>EYS-Associated Sector Retinitis Pigmentosa</i>	Original article	<i>Graefe's Archive for Clinical and Experimental Ophthalmology</i>	5.0	Q1 Ophthalmology
<i>Eyes Shut Homolog-Associated Retinal Degeneration: Natural History, Genetic Landscape, and Phenotypic Spectrum</i>	Original article	<i>Ophthalmology Retina</i>	5.8	Q1 Ophthalmology
<i>Genetic spectrum, retinal phenotype and peripapillary RNFL thickness in RPGR heterozygotes</i>	Original article	<i>Graefe's Archive for Clinical and Experimental Ophthalmology</i>	5.0	Q1 Ophthalmology
<i>Frequency of cystoid macular edema and vitreomacular interface disorders in genetically solved syndromic and non-syndromic Retinitis Pigmentosa</i>	Original article	<i>Graefe's Archive for Clinical and Experimental Ophthalmology</i>	5.0	Q1 Ophthalmology
<i>Non-exudative macular neovascularization in pseudoxanthoma elasticum</i>	Original article	<i>Graefe's Archive for Clinical and Experimental Ophthalmology</i>	5.0	Q1 Ophthalmology

<i>Portuguese translation and linguistic validation of the Michigan Retinal Degeneration Questionnaire and the Michigan Vision-Related Anxiety Questionnaire in a cohort with Inherited Retinal Degenerations</i>	Letter	<i>Ophthalmic Genetics</i>	2.4	Q2 Ophthalmology
<i>Self-reported visual function and psychosocial impact of visual loss in EYS-associated retinal degeneration in a Portuguese population</i>	Original article	<i>Ophthalmic Genetics</i>	2.4	Q2 Ophthalmology
<i>MFRP-Related Nanophthalmos-Retinitis Pigmentosa-Foveoschisis-Optic Disc Drusen Syndrome</i>	Photo essay	<i>Ophthalmic Surgery Lasers and Imaging Retina</i>	2.2	Q2 Ophthalmology
<i>SLC24A1-Associated Congenital Stationary Night Blindness in a woman with an abnormal fundus</i>	Photo essay	<i>JAMA Ophthalmology</i>	11.3	Q1 Ophthalmology
<i>Multimodal Imaging in Hypotrichosis with Juvenile Macular Degeneration</i>	Photo essay	<i>Ophthalmology Retina</i>	5.8	Q1 Ophthalmology
<i>Gyrate atrophy of the choroid and retina</i>	Photo essay	<i>Postgraduate Medical Journal</i>	4.1	Q2 Medicine
<i>Double concentric hyperautofluorescent ring in EYS-Associated Retinitis Pigmentosa</i>	Photo essay	<i>Asia Pacific Journal of Ophthalmology</i>	4.9	Q1 Ophthalmology
<i>Genetic, Anatomical, and Functional Correlation of Sector Retinitis Pigmentosa</i>	Photo essay	<i>JAMA Ophthalmology</i>	11.3	Q1 Ophthalmology
<i>Subretinal bleb of Voretigene Neparvovec</i>	Photo essay	<i>Asia Pacific Journal of Ophthalmology</i>	4.9	Q1 Ophthalmology

## REFERENCES

1. Hanany M, Rivolta C, Sharon D. Worldwide carrier frequency and genetic prevalence of autosomal recessive inherited retinal diseases. *Proc Natl Acad Sci U S A* 2020;117(5):2710-2716. DOI: 10.1073/pnas.1913179117.
2. Weisschuh N, Obermaier CD, Battke F, et al. Genetic architecture of inherited retinal degeneration in Germany: A large cohort study from a single diagnostic center over a 9-year period. *Hum Mutat* 2020;41(9):1514-1527. DOI: 10.1002/humu.24064.
3. Liew G, Michaelides M, Bunce C. A comparison of the causes of blindness certifications in England and Wales in working age adults (16-64 years), 1999-2000 with 2009-2010. *BMJ Open* 2014;4(2):e004015. DOI: 10.1136/bmjopen-2013-004015.
4. Solebo AL, Teoh L, Rahi J. Epidemiology of blindness in children. *Arch Dis Child* 2017;102(9):853-857. DOI: 10.1136/archdischild-2016-310532.
5. Broadgate S, Yu J, Downes SM, Halford S. Unravelling the genetics of inherited retinal dystrophies: Past, present and future. *Prog Retin Eye Res* 2017;59:53-96. DOI: 10.1016/j.preteyeres.2017.03.003.
6. Ferreira CR. The burden of rare diseases. *Am J Med Genet A* 2019;179(6):885-892. DOI: 10.1002/ajmg.a.61124.

7. Jayasundera KT, Abuzaitoun RO, Lacy GD, et al. Challenges of cost-effectiveness analyses of novel therapeutics for Inherited Retinal Diseases: Cost-effectiveness analysis in Inherited Retinal Diseases. *Am J Ophthalmol* 2021. DOI: 10.1016/j.ajo.2021.08.009.
8. Gong J, Cheung S, Fasso-Opie A, et al. The Impact of Inherited Retinal Diseases in the United States of America (US) and Canada from a Cost-of-Illness Perspective. *Clin Ophthalmol* 2021;15:2855-2866. DOI: 10.2147/OPTH.S313719.
9. Galvin O, Chi G, Brady L, et al. The Impact of Inherited Retinal Diseases in the Republic of Ireland (ROI) and the United Kingdom (UK) from a Cost-of-Illness Perspective. *Clin Ophthalmol* 2020;14:707-719. DOI: 10.2147/OPTH.S241928.
10. Adams DR, Eng CM. Next-Generation Sequencing to Diagnose Suspected Genetic Disorders. *N Engl J Med* 2019;380(2):201. DOI: 10.1056/NEJMc1814955.
11. Dockery A, Whelan L, Humphries P, Farrar GJ. Next-Generation Sequencing Applications for Inherited Retinal Diseases. *Int J Mol Sci* 2021;22(11). DOI: 10.3390/ijms22115684.
12. Fadaie Z, Whelan L, Ben-Yosef T, et al. Whole genome sequencing and in vitro splice assays reveal genetic causes for inherited retinal diseases. *NPJ Genom Med* 2021;6(1):97. DOI: 10.1038/s41525-021-00261-1.
13. Harrison M, Birch S, Eden M, et al. Variation in healthcare services for specialist genetic testing and implications for planning genetic services: the example of inherited retinal dystrophy in the English NHS. *J Community Genet* 2015;6(2):157-65. DOI: 10.1007/s12687-014-0210-4.
14. Lorenz B, Tavares J, van den Born LI, Marques JP, Scholl HPN, Group EVn. Current Management of Inherited Retinal Degeneration Patients in Europe: Results of a Multinational Survey by the European Vision Institute Clinical Research Network. *Ophthalmic Res* 2021;64(4):622-638. DOI: 10.1159/000514540.
15. Black GC, Sergouniotis P, Sodi A, et al. The need for widely available genomic testing in rare eye diseases: an ERN-EYE position statement. *Orphanet J Rare Dis* 2021;16(1):142. DOI: 10.1186/s13023-021-01756-x.
16. Marques JP, Pires J, Costa J, Murta J, Silva R. Inherited Retinal Degenerations in Portugal: Addressing the Unmet Needs. *Acta Med Port* 2021;34(5):332-334. DOI: 10.20344/amp.15802.
17. Lorenz B, Tavares J, van den Born LI, Marques JP, Scholl HPN. Current management of Inherited Retinal Degenerations (IRD) patients in Europe. Results of a multinational survey by the European Vision Institute Clinical Research Network EVICR.net. *Ophthalmic Res* 2021 (Epub ahead of print). DOI: 10.1159/000514540.



18. Davison N, Payne K, Eden M, et al. Exploring the feasibility of delivering standardized genomic care using ophthalmology as an example. *Genet Med* 2017;19(9):1032-1039. DOI: 10.1038/gim.2017.9.
19. Claussnitzer M, Cho JH, Collins R, et al. A brief history of human disease genetics. *Nature* 2020;577(7789):179-189. DOI: 10.1038/s41586-019-1879-7.
20. Schneider N, Sundaresan Y, Gopalakrishnan P, et al. Inherited retinal diseases: Linking genes, disease-causing variants, and relevant therapeutic modalities. *Prog Retin Eye Res* 2022;89:101029. DOI: 10.1016/j.preteyeres.2021.101029.
21. Kousi M, Katsanis N. Genetic modifiers and oligogenic inheritance. *Cold Spring Harb Perspect Med* 2015;5(6). DOI: 10.1101/cshperspect.a017145.
22. Shah M, Shanks M, Packham E, et al. Next generation sequencing using phenotype-based panels for genetic testing in inherited retinal diseases. *Ophthalmic Genet* 2020;41(4):331-337. DOI: 10.1080/13816810.2020.1778736.
23. Sharon D, Ben-Yosef T, Goldenberg-Cohen N, et al. A nationwide genetic analysis of inherited retinal diseases in Israel as assessed by the Israeli inherited retinal disease consortium (IIRDC). *Hum Mutat* 2020;41(1):140-149. DOI: 10.1002/humu.23903.
24. Carss KJ, Arno G, Erwood M, et al. Comprehensive Rare Variant Analysis via Whole-Genome Sequencing to Determine the Molecular Pathology of Inherited Retinal Disease. *Am J Hum Genet* 2017;100(1):75-90. DOI: 10.1016/j.ajhg.2016.12.003.
25. Huang XF, Wu J, Lv JN, Zhang X, Jin ZB. Identification of false-negative mutations missed by next-generation sequencing in retinitis pigmentosa patients: a complementary approach to clinical genetic diagnostic testing. *Genet Med* 2015;17(4):307-11. DOI: 10.1038/gim.2014.193.
26. Eisenberger T, Neuhaus C, Khan AO, et al. Increasing the yield in targeted next-generation sequencing by implicating CNV analysis, non-coding exons and the overall variant load: the example of retinal dystrophies. *PLoS One* 2013;8(11):e78496. DOI: 10.1371/journal.pone.0078496.
27. Birtel J, Gliem M, Oishi A, et al. Genetic testing in patients with retinitis pigmentosa: Features of unsolved cases. *Clin Exp Ophthalmol* 2019;47(6):779-786. DOI: 10.1111/ceo.13516.
28. Heckenlively JR, Fawzi AA, Oversier J, Jordan BL, Aptsiauri N. Autoimmune retinopathy: patients with antirecoverin immunoreactivity and panretinal degeneration. *Arch Ophthalmol* 2000;118(11):1525-33. DOI: 10.1001/archophth.118.11.1525.
29. Makiyama Y, Kikuchi T, Otani A, et al. Clinical and immunological characterization of paraneoplastic retinopathy. *Invest Ophthalmol Vis Sci* 2013;54(8):5424-31. DOI: 10.1167/iovs.13-11868.

30. Fenner BJ, Tan TE, Barathi AV, et al. Gene-Based Therapeutics for Inherited Retinal Diseases. *Front Genet* 2021;12:794805. DOI: 10.3389/fgene.2021.794805.
31. Suppiej A, Marino S, Reffo ME, et al. Early onset retinal dystrophies: clinical clues to diagnosis for pediatricians. *Ital J Pediatr* 2019;45(1):168. DOI: 10.1186/s13052-019-0760-5.
32. Tatour Y, Ben-Yosef T. Syndromic Inherited Retinal Diseases: Genetic, Clinical and Diagnostic Aspects. *Diagnostics (Basel)* 2020;10(10). DOI: 10.3390/diagnostics10100779.
33. Sanchez-Bellver L, Toulis V, Marfany G. On the Wrong Track: Alterations of Ciliary Transport in Inherited Retinal Dystrophies. *Front Cell Dev Biol* 2021;9:623734. DOI: 10.3389/fcell.2021.623734.
34. Sadagopan KA. Practical approach to syndromic pediatric retinal dystrophies. *Curr Opin Ophthalmol* 2017;28(5):416-429. DOI: 10.1097/ICU.0000000000000404.
35. Sergouniotis PI, Maxime E, Leroux D, et al. An ontological foundation for ocular phenotypes and rare eye diseases. *Orphanet J Rare Dis* 2019;14(1):8. DOI: 10.1186/s13023-018-0980-6.
36. Stone EM, Andorf JL, Whitmore SS, et al. Clinically Focused Molecular Investigation of 1000 Consecutive Families with Inherited Retinal Disease. *Ophthalmology* 2017;124(9):1314-1331. DOI: 10.1016/j.ophtha.2017.04.008.
37. Daich Varela M, Esener B, Hashem SA, Cabral de Guimaraes TA, Georgiou M, Michaelides M. Structural evaluation in inherited retinal diseases. *Br J Ophthalmol* 2021;105(12):1623-1631. DOI: 10.1136/bjophthalmol-2021-319228.
38. Cicinelli MV, Marchese A, Bordato A, Manitto MP, Bandello F, Battaglia Parodi M. Reviewing the Role of Ultra-Widefield Imaging in Inherited Retinal Dystrophies. *Ophthalmol Ther* 2020;9(2):249-263. DOI: 10.1007/s40123-020-00241-1.
39. Rahman N, Georgiou M, Khan KN, Michaelides M. Macular dystrophies: clinical and imaging features, molecular genetics and therapeutic options. *Br J Ophthalmol* 2020;104(4):451-460. DOI: 10.1136/bjophthalmol-2019-315086.
40. Cornish EE, Vaze A, Jamieson RV, Grigg JR. The electroretinogram in the genomics era: outer retinal disorders. *Eye (Lond)* 2021;35(9):2406-2418. DOI: 10.1038/s41433-021-01659-y.
41. Daich Varela M, Georgiou M, Hashem SA, Weleber RG, Michaelides M. Functional evaluation in inherited retinal disease. *Br J Ophthalmol* 2021. DOI: 10.1136/bjophthalmol-2021-319994.

42. Roman AJ, Cideciyan AV, Wu V, Garafalo AV, Jacobson SG. Full-field stimulus testing: Role in the clinic and as an outcome measure in clinical trials of severe childhood retinal disease. *Prog Retin Eye Res* 2022;87:101000. DOI: 10.1016/j.preteyeres.2021.101000.
43. Otte B, Andrews C, Lacy G, Branham K, Musch DC, Jayasundera KT. Clinical trial design for neuroprotection in RHO autosomal dominant retinitis pigmentosa; outcome measure considerations. *Ophthalmic Genet* 2021;42(2):170-177. DOI: 10.1080/13816810.2020.1867752.
44. Huang D, Swanson EA, Lin CP, et al. Optical coherence tomography. *Science* 1991;254(5035):1178-81. DOI: 10.1126/science.1957169.
45. Ramachandran R, Zhou L, Locke KG, Birch DG, Hood DC. A Comparison of Methods for Tracking Progression in X-Linked Retinitis Pigmentosa Using Frequency Domain OCT. *Transl Vis Sci Technol* 2013;2(7):5. DOI: 10.1167/tvst.2.7.5.
46. Marques JP, Porto FBO, Carvalho AL, et al. EYS-Associated Sector Retinitis Pigmentosa. *Graefes Arch Clin Exp Ophthalmol* 2021. DOI: 10.1007/s00417-021-05411-w.
47. Marques JP, Marta A, Geada S, et al. Clinical/Demographic Functional Testing and Multimodal Imaging Differences between Genetically Solved and Unsolved Retinitis Pigmentosa. *Ophthalmologica* 2021. DOI: 10.1159/000520305.
48. Marques JP, Neves E, Geada S, et al. Frequency of cystoid macular edema and vitreomacular interface disorders in genetically solved syndromic and non-syndromic retinitis pigmentosa. *Graefes Arch Clin Exp Ophthalmol* 2022. DOI: 10.1007/s00417-022-05649-y.
49. Liew G, Strong S, Bradley P, et al. Prevalence of cystoid macular oedema, epiretinal membrane and cataract in retinitis pigmentosa. *Br J Ophthalmol* 2019;103(8):1163-1166. DOI: 10.1136/bjophthalmol-2018-311964.
50. Strong S, Liew G, Michaelides M. Retinitis pigmentosa-associated cystoid macular oedema: pathogenesis and avenues of intervention. *Br J Ophthalmol* 2017;101(1):31-37. DOI: 10.1136/bjophthalmol-2016-309376.
51. Velaga SB, Nittala MG, Jenkins D, et al. Impact of segmentation density on spectral domain optical coherence tomography assessment in Stargardt disease. *Graefes Arch Clin Exp Ophthalmol* 2019;257(3):549-556. DOI: 10.1007/s00417-018-04229-3.
52. Marques JP, Alfaiate M, Figueira JP. Subretinal Bleb of Voretigene Neparvovec. *Asia Pac J Ophthalmol (Phila)* 2021. DOI: 10.1097/APO.0000000000000431.
53. Bennett TJ, Barry CJ. Ophthalmic imaging today: an ophthalmic photographer's viewpoint - a review. *Clin Exp Ophthalmol* 2009;37(1):2-13. DOI: 10.1111/j.1442-9071.2008.01812.x.

54. Delori FC, Dorey CK, Staurenghi G, Arend O, Goger DG, Weiter JJ. In vivo fluorescence of the ocular fundus exhibits retinal pigment epithelium lipofuscin characteristics. *Invest Ophthalmol Vis Sci* 1995;36(3):718-29.
55. Tee JLL, Kalitzeos A, Webster AR, Peto T, Michaelides M. Quantitative Analysis of Hyperautofluorescent Rings to Characterize the Natural History and Progression in Rpgp-Associated Retinopathy. *Retina* 2018;38(12):2401-2414. DOI: 10.1097/IAE.0000000000001871.
56. Escher P, Tran HV, Vaclavik V, Borruat FX, Schorderet DF, Munier FL. Double concentric autofluorescence ring in NR2E3-p.G56R-linked autosomal dominant retinitis pigmentosa. *Invest Ophthalmol Vis Sci* 2012;53(8):4754-64. DOI: 10.1167/iovs.11-8693.
57. Nanda A, Salvetti AP, Clouston P, Downes SM, MacLaren RE. Exploring the Variable Phenotypes of RPGR Carrier Females in Assessing their Potential for Retinal Gene Therapy. *Genes (Basel)* 2018;9(12). DOI: 10.3390/genes9120643.
58. Marques JP, Bernardes J, Geada S, et al. Non-exudative macular neovascularization in pseudoxanthoma elasticum. *Graefes Arch Clin Exp Ophthalmol* 2021;259(4):873-882. DOI: 10.1007/s00417-020-04979-z.
59. Marques JP, Porto FBO, Carvalho AL, et al. EYS-Associated Sector Retinitis Pigmentosa. *Graefes Arch Clin Exp Ophthalmol* 2022;260(4):1405-1413. DOI: 10.1007/s00417-021-05411-w.
60. Oliveira MA, Neves E, Marques JP. Genetic, Anatomical, and Functional Correlation of Sector Retinitis Pigmentosa. *JAMA Ophthalmol* 2020;138(6):e193133. DOI: 10.1001/jamaophthalmol.2019.3133.
61. Marques JP, Marta A, Geada S, et al. Clinical/Demographic Functional Testing and Multimodal Imaging Differences between Genetically Solved and Unsolved Retinitis Pigmentosa. *Ophthalmologica* 2022;245(2):134-143. DOI: 10.1159/000520305.
62. Georgiou M, Grewal PS, Narayan A, et al. Sector Retinitis Pigmentosa: Extending the Molecular Genetics Basis and Elucidating the Natural History. *Am J Ophthalmol* 2021;221:299-310. DOI: 10.1016/j.ajo.2020.08.004.
63. Hara A, Nakazawa M, Saito M, Suzuki Y. The qualitative assessment of optical coherence tomography and the central retinal sensitivity in patients with retinitis pigmentosa. *PLoS One* 2020;15(5):e0232700. DOI: 10.1371/journal.pone.0232700.
64. Abe K, Iijima H, Hirakawa H, Tsukahara Y, Toda Y. Visual acuity and 10 degrees automated static perimetry in eyes with retinitis pigmentosa. *Jpn J Ophthalmol* 2002;46(5):581-5. DOI: 10.1016/s0021-5155(02)00548-8.
65. Iijima H. Visual loss and perimetric sensitivity in eyes with retinitis pigmentosa. *Jpn J Ophthalmol* 2013;57(6):563-7. DOI: 10.1007/s10384-013-0271-7.

66. Maguire AM, Russell S, Wellman JA, et al. Efficacy, Safety, and Durability of Voretigene Neparvovec-rzyl in RPE65 Mutation-Associated Inherited Retinal Dystrophy: Results of Phase 1 and 3 Trials. *Ophthalmology* 2019;126(9):1273-1285. DOI: 10.1016/j.ophtha.2019.06.017.
67. Russell S, Bennett J, Wellman JA, et al. Efficacy and safety of voretigene neparvovec (AAV2-hRPE65v2) in patients with RPE65-mediated inherited retinal dystrophy: a randomised, controlled, open-label, phase 3 trial. *Lancet* 2017;390(10097):849-860. DOI: 10.1016/S0140-6736(17)31868-8.
68. McCulloch DL, Marmor MF, Brigell MG, et al. ISCEV Standard for full-field clinical electroretinography (2015 update). *Doc Ophthalmol* 2015;130(1):1-12. DOI: 10.1007/s10633-014-9473-7.
69. Vincent A, Robson AG, Holder GE. Pathognomonic (diagnostic) ERGs. A review and update. *Retina* 2013;33(1):5-12. DOI: 10.1097/IAE.0b013e31827e2306.
70. Richards S, Aziz N, Bale S, et al. Standards and guidelines for the interpretation of sequence variants: a joint consensus recommendation of the American College of Medical Genetics and Genomics and the Association for Molecular Pathology. *Genet Med* 2015;17(5):405-24. DOI: 10.1038/gim.2015.30.
71. Sharon D, Wimberg H, Kinarty Y, Koch KW. Genotype-functional-phenotype correlations in photoreceptor guanylate cyclase (GC-E) encoded by GUCY2D. *Prog Retin Eye Res* 2018;63:69-91. DOI: 10.1016/j.preteyeres.2017.10.003.
72. Pierrache LH, Hartel BP, van Wijk E, et al. Visual Prognosis in USH2A-Associated Retinitis Pigmentosa Is Worse for Patients with Usher Syndrome Type IIa Than for Those with Nonsyndromic Retinitis Pigmentosa. *Ophthalmology* 2016;123(5):1151-60. DOI: 10.1016/j.ophtha.2016.01.021.
73. Ng YNC, Ng NYT, Fung JLF, et al. Evaluating the Health-Related Quality of Life of the Rare Disease Population in Hong Kong Using EQ-5D 3-Level. *Value Health* 2022. DOI: 10.1016/j.jval.2022.04.1725.
74. Djulbegovic M, Kalahasty K, Watane A, Jabori SK, Al-Khersan H, Sridhar J. Correlation Between Altmetric Attention Scores and Citations for Articles Published in High-Impact Factor Ophthalmology Journals From 2018 to 2019. *JAMA Ophthalmol* 2022;140(6):623-627. DOI: 10.1001/jamaophthalmol.2022.0858.
75. Tsui E, Rao RC. Navigating Social Media in #Ophthalmology. *Ophthalmology* 2019;126(6):779-782. DOI: 10.1016/j.ophtha.2019.02.015.
76. Marques JP. Instagram as a vehicle to promote disease awareness and medical education in #retinaldystrophies. *Postgrad Med J* 2022;98(e3):e167. DOI: 10.1136/postgradmedj-2021-140041.

77. Gillies MC, Walton R, Liong J, et al. Efficient capture of high-quality data on outcomes of treatment for macular diseases: the fight retinal blindness! Project. *Retina* 2014;34(1):188-95. DOI: 10.1097/IAE.0b013e318296b271.
78. Chiang MF, Sommer A, Rich WL, Lum F, Parke DW, 2nd. The 2016 American Academy of Ophthalmology IRIS((R)) Registry (Intelligent Research in Sight) Database: Characteristics and Methods. *Ophthalmology* 2018;125(8):1143-1148. DOI: 10.1016/j.ophtha.2017.12.001.
79. Lundstrom M, Manning S, Barry P, Stenevi U, Henry Y, Rosen P. The European registry of quality outcomes for cataract and refractive surgery (EUREQUO): a database study of trends in volumes, surgical techniques and outcomes of refractive surgery. *Eye Vis (Lond)* 2015;2:8. DOI: 10.1186/s40662-015-0019-1.
80. Lum F, Schachat AP, Jampel HD. The development and demise of a cataract surgery database. *Jt Comm J Qual Improv* 2002;28(3):108-14. DOI: 10.1016/s1070-3241(02)28010-4.
81. Tan JCK, Ferdi AC, Gillies MC, Watson SL. Clinical Registries in Ophthalmology. *Ophthalmology* 2019;126(5):655-662. DOI: 10.1016/j.ophtha.2018.12.030.
82. Boulanger V, Schlemmer M, Rossov S, Seebald A, Gavin P. Establishing Patient Registries for Rare Diseases: Rationale and Challenges. *Pharmaceut Med* 2020. DOI: 10.1007/s40290-020-00332-1.
83. Marques JP, Carvalho AL, Henriques J, Murta JN, Saraiva J, Silva R. Design, development and deployment of a web-based interoperable registry for inherited retinal dystrophies in Portugal: the IRD-PT. *Orphanet J Rare Dis* 2020;15(1):304. DOI: 10.1186/s13023-020-01591-6.
84. Solebo AL, Rahi J. Epidemiology, aetiology and management of visual impairment in children. *Arch Dis Child* 2014;99(4):375-9. DOI: 10.1136/archdischild-2012-303002.
85. D'Amada CS, Nolen R, Huryn LA, Turriff A. Psychosocial impacts of Mendelian eye conditions: A systematic literature review. *Surv Ophthalmol* 2020;65(5):562-580. DOI: 10.1016/j.survophthal.2020.02.002.
86. Bambara JK, Wadley V, Owsley C, Martin RC, Porter C, Dreer LE. Family Functioning and Low Vision: A Systematic Review. *J Vis Impair Blind* 2009;103(3):137-149.
87. Chiang MF, Tumminia SJ. The 2021 National Eye Institute Strategic Plan: Eliminating Vision Loss and Improving Quality of Life. *Ophthalmology* 2022;129(1):12-14. DOI: 10.1016/j.ophtha.2021.09.012.
88. Chiang MF. The 2021 National Eye Institute Strategic Plan-Relating Vision to Health and Quality of Life. *JAMA Ophthalmol* 2021;139(12):1263-1265. DOI: 10.1001/jamaophthalmol.2021.4774.

89. Lacy GD, Abalem MF, Popova LT, et al. Content generation for patient-reported outcome measures for retinal degeneration therapeutic trials. *Ophthalmic Genet* 2020;41(4):315-324. DOI: 10.1080/13816810.2020.1776337.
90. Botto C, Rucli M, Tekinsoy MD, Pulman J, Sahel JA, Dalkara D. Early and late stage gene therapy interventions for inherited retinal degenerations. *Prog Retin Eye Res* 2021;100975. DOI: 10.1016/j.preteyeres.2021.100975.
91. Rausch-Koster TP, van der Ham AJ, Terwee CB, Verbraak FD, van Rens G, van Nispen RMA. Translation and content validity of the Dutch Impact of Vision Impairment questionnaire assessed by Three-Step Test-Interviewing. *J Patient Rep Outcomes* 2021;5(1):1. DOI: 10.1186/s41687-020-00272-z.
92. Lacy GD, Abalem MF, Andrews CA, et al. The Michigan Retinal Degeneration Questionnaire: A Patient-Reported Outcome Instrument for Inherited Retinal Degenerations. *Am J Ophthalmol* 2021;222:60-68. DOI: 10.1016/j.ajo.2020.08.032.
93. Lacy GD, Abalem MF, Andrews CA, et al. The Michigan Vision-Related Anxiety Questionnaire: A Psychosocial Outcomes Measure for Inherited Retinal Degenerations. *Am J Ophthalmol* 2021;225:137-146. DOI: 10.1016/j.ajo.2020.12.001.
94. Selvan K, Abalem MF, Lacy GD, Vincent A, Heon E. The State of Patient-Reported Outcome Measures for Pediatric Patients with Inherited Retinal Disease. *Ophthalmol Ther* 2022;11(3):1031-1046. DOI: 10.1007/s40123-022-00514-x.
95. Botto C, Rucli M, Tekinsoy MD, Pulman J, Sahel JA, Dalkara D. Early and late stage gene therapy interventions for inherited retinal degenerations. *Prog Retin Eye Res* 2022;86:100975. DOI: 10.1016/j.preteyeres.2021.100975.
96. Georgiou M, Fujinami K, Michaelides M. Inherited retinal diseases: Therapeutics, clinical trials and end points-A review. *Clin Exp Ophthalmol* 2021;49(3):270-288. DOI: 10.1111/ceo.13917.
97. Garafalo AV, Cideciyan AV, Heon E, et al. Progress in treating inherited retinal diseases: Early subretinal gene therapy clinical trials and candidates for future initiatives. *Prog Retin Eye Res* 2020;77:100827. DOI: 10.1016/j.preteyeres.2019.100827.
98. Gasparini SJ, Llonch S, Borsch O, Ader M. Transplantation of photoreceptors into the degenerative retina: Current state and future perspectives. *Prog Retin Eye Res* 2019;69:1-37. DOI: 10.1016/j.preteyeres.2018.11.001.
99. Pardue MT, Allen RS. Neuroprotective strategies for retinal disease. *Prog Retin Eye Res* 2018;65:50-76. DOI: 10.1016/j.preteyeres.2018.02.002.
100. Singh RK, Binette F, Seiler M, Petersen-Jones SM, Nasonkin IO. Pluripotent Stem Cell-Based Organoid Technologies for Developing Next-Generation Vision Restoration

- Therapies of Blindness. *J Ocul Pharmacol Ther* 2021;37(3):147-156. DOI: 10.1089/jop.2020.0016.
101. Sahel JA, Boulanger-Scemama E, Pagot C, et al. Partial recovery of visual function in a blind patient after optogenetic therapy. *Nat Med* 2021;27(7):1223-1229. DOI: 10.1038/s41591-021-01351-4.
102. Maguire AM, Bennett J, Aleman EM, Leroy BP, Aleman TS. Clinical Perspective: Treating RPE65-Associated Retinal Dystrophy. *Mol Ther* 2020 (Epub ahead of print). DOI: 10.1016/j.ymthe.2020.11.029.
103. Redmond TM, Yu S, Lee E, et al. Rpe65 is necessary for production of 11-cis-vitamin A in the retinal visual cycle. *Nat Genet* 1998;20(4):344-51. DOI: 10.1038/3813.
104. Lorenz B, Tavares J, van den Born LI, Marques JP, Scholl HPN, Group EVn. Current management of patients with RPE65 mutation-associated inherited retinal degenerations (IRDs) in Europe. Results of a multinational survey by the European Vision Institute Clinical Research Network EVICR.net. *Ophthalmic Res* 2021. DOI: 10.1159/000515688.
105. Pontikos N, Arno G, Jurkute N, et al. Genetic Basis of Inherited Retinal Disease in a Molecularly Characterized Cohort of More Than 3000 Families from the United Kingdom. *Ophthalmology* 2020;127(10):1384-1394. DOI: 10.1016/j.ophtha.2020.04.008.
106. Kumaran N, Georgiou M, Bainbridge JWB, et al. Retinal Structure in RPE65-Associated Retinal Dystrophy. *Invest Ophthalmol Vis Sci* 2020;61(4):47. DOI: 10.1167/iovs.61.4.47.
107. Jayasundera KT, Abuzaitoun RO, Lacy GD, et al. Challenges of Cost-Effectiveness Analyses of Novel Therapeutics for Inherited Retinal Diseases. *Am J Ophthalmol* 2022;235:90-97. DOI: 10.1016/j.ajo.2021.08.009.
108. Agarwal R, Tripathi A. Current Modalities for Low Vision Rehabilitation. *Cureus* 2021;13(7):e16561. DOI: 10.7759/cureus.16561.
109. Marques JP, Bernardes L, Oliveira C, et al. Portuguese translation and linguistic validation of the Michigan Retinal Degeneration Questionnaire and the Michigan Vision-Related Anxiety Questionnaire in a cohort with inherited retinal degenerations. *Ophthalmic Genet* 2022;43(1):137-139. DOI: 10.1080/13816810.2022.2025609.
110. Marques JP, Raimundo M, Paiva C, et al. Treating the first Portuguese patient with Luxturna: A small step for world science, a giant leap for Portuguese Ophthalmology. *Revista Sociedade Portuguesa de Oftalmologia* 2021;45(2):67-69. DOI: 10.48560/rspo.24654.



## **CHAPTER 2: IRD-RELATED UNMET NEEDS**



Manuscript I

## **2.1. Inherited Retinal Degenerations in Portugal: Addressing the Unmet Needs**

João Pedro Marques

Joana Pires

José Costa

Joaquim Murta

Rufino Silva

*Published in: Acta Med Port. 2021 May 2;34(5):332-334.*

## INTRODUCTION

Inherited retinal dystrophies/degenerations (IRDs) are a clinically and genetically heterogeneous group of rare eye diseases. Despite their low prevalence (~1:3000 individuals),<sup>1</sup> IRDs are an important cause of severe visual impairment and blindness in children and young adults. Over the past three decades, major advances in molecular biology and human genetics have contributed to uncover the molecular basis of these disorders. Most excitingly, treatment of a particular form of congenital retinal degeneration is now possible. In December 2017, the Food and Drug Administration (FDA) approved voretigene neparvovec (Luxturna, Spark Therapeutics Inc.) to treat *RPE65* mutation-associated retinal degeneration, which inevitably progresses to complete blindness by the third/fourth decade of life. Gene augmentation therapy delivers a normal copy of the native human *RPE65* cDNA to the diseased retinal pigment epithelium (RPE) cells after subretinal injection of a recombinant adeno-associated virus. The transduced RPE cells then produce the *RPE65* protein and the biochemical pathway leading to production of 11-cis retinal is restored, thus improving photoreceptor function.<sup>2</sup> Results from a phase three trial demonstrated improved light sensitivity, visual fields, and navigational ability under dim lighting conditions in patients with *RPE65* mutation-associated retinal degeneration.<sup>3</sup> The clinically meaningful effect, which is nearly maximal by 30 days after the administration, is maintained at least for four years, with observations ongoing.<sup>4</sup> In November 2018, the European Medicines Agency (EMA) granted Novartis AG marketing authorization for the use of Luxturna in Europe and several European countries have already started treatment. Not only has this newly approved therapy changed the lives of people previously destined to live a life of blindness, but it has fueled interest in developing additional gene therapy reagents targeting numerous other genetic forms of inherited retinal disease.<sup>2</sup> The lack of a consistent *RPE65* mutation-to-phenotype correlation underscores the need for widespread genetic screening in order to identify IRD patients who might benefit from this or other potential future gene therapies.

Despite some common ground, IRD genetic profiles have been shown to vary considerably among regions and ethnic groups,<sup>1,5</sup> thus highlighting the importance of obtaining reference population-based data. A recent survey from the European Vision Institute for Clinical Research Network (EVICR.net)<sup>6</sup> underlined the significant heterogeneity between centers and across countries regarding the current management of IRD patients in Europe. This applies not only to genetic testing and genetic counselling, but also to referral pathways, access to expert centers, ancillary diagnostic tests, among others. To improve the care of IRD patients in Portugal, we need to urgently address four pivotal unmet needs: 1) improve disease awareness and

education; 2) provide equitable access to genetic testing and genetic counselling; 3) establish referral pathways; and 4) develop a national IRD registry.

### **Disease awareness and education**

One of the most important issues is the dis- and/or misinformation that exists towards IRDs. It is crucial to raise awareness and educate decision/policy-makers, the general public, clinicians, and other healthcare workers about these visually incapacitating diseases. Only with this background work can patients be granted full clinical, familial, social, and economic support. Strategies to improve disease awareness include position papers written by experts in the field, targeted conferences/lectures/courses/preceptorships for healthcare professionals, media coverage and even social media actions. Ophthalmologists, pediatricians, and general practitioners (GPs) / family physicians are usually the first clinicians to encounter an IRD patient, thus making up the group where targeted educational actions are most needed. Recognizing clinical clues/red flags like nystagmus, low vision, constricted visual field, nyctalopia and photophobia is crucial for a timely referral to an IRD expert center. In preverbal children, abnormal visual behavior and nystagmus observed and reported by the parents should prompt an appropriate ophthalmological workup for IRD.<sup>7</sup>

### **Genetic testing and genetic counselling**

Remarkable progress in understanding the genetics of IRDs resulted in the identification of roughly 300 disease-causing genes (<https://sph.uth.edu/retnet/>). Several studies have confirmed that next-generation sequencing (NGS) panel-based genetic testing can be highly accurate, sensitive and reproducible in the molecular diagnosis of IRDs.<sup>8</sup> However, this wealth of information is only slowly being translated into genetic diagnoses for individual patients, as significant barriers to testing still exist. In Portugal, the overall prevalence and genetic architecture of IRDs is largely unknown since access to genetic testing is not equitable. A critical goal for moving the field forward is to obtain a genetic diagnosis for every IRD patient, the importance of which cannot be overemphasized. In fact, having a genetic diagnosis is likely to be the single most important factor for gaining access to an approved treatment or clinical trial based on gene therapy.<sup>9</sup> Furthermore, it allows accurate genetic counselling for the patient and other family members, along with prenatal testing. Additionally, it is a singularly important strategy for advancing the classification of mutations and corresponding phenotypes, and for evaluating the prognosis of specific disease-causing genes. In order to provide all IRD patients with the opportunity to undergo genetic testing, patient referral pathways must be in place so that patients may access expert centres easily. Portugal must draw up clinical recommendations

or guidelines for genetic testing in IRDs, aiming to grant an equitable access to genetic testing and genetic counselling.

### **Referral pathways**

Timely referral of patients with presumed IRDs to an ophthalmologist is critical. This applies especially to children since visual rehabilitation during the appropriate stages of visual development may prevent amblyopia. If the initial suspicion of IRD is confirmed by the ophthalmologist, the patient should be referred for genotyping. Now that treatment of *RPE65* mutation-associated retinal degeneration is possible, establishing a genetic diagnosis is even more important. Given the degenerative nature of IRDs, a window of opportunity for gene therapy exists and gene therapy candidates must be identified as soon as possible. A list of national IRD experts and IRD expert centers should be created and made available to ensure a smooth referral process. The European Reference Network for Rare Eye Diseases (ERN-EYE) is a unique and innovative cross-border cooperation platform between specialists for the diagnosis and treatment of rare or low prevalence complex eye diseases, where IRDs are included. The only Portuguese healthcare provider that integrates the ERN-EYE is *Centro Hospitalar e Universitário de Coimbra* (CHUC). However, appropriate dissemination of this information is warranted, especially to those that deal with IRD patients – ophthalmologists, pediatricians and GPs.

### **National IRD registry**

A national, web-based registry for IRDs is able to empower patients and community organizations, while supporting formal partnerships with investigators and stakeholders in the global aim to develop high-value, high-utility research.<sup>10</sup> In 2020, the IRD-PT registry ([www.retina.com.pt](http://www.retina.com.pt)) was launched with the mission to generate important knowledge and collect high-quality longitudinal data on the epidemiology, genomic landscape, genotype–phenotype correlations and natural history of IRDs in Portugal.<sup>10</sup> Hopefully, this invaluable resource will both boost and excel clinical research in the field of IRDs in our country, while facilitating patient access to clinical trials or new therapies.

## **CONCLUSION**

Although rare in the general population, IRDs occupy a key position in current efforts to develop innovative therapies for blinding diseases. Despite remarkable advances witnessed in the field, complex challenges subsist. This position paper from the Ophthalmic Genetics Group of the Portuguese Society of Ophthalmology identifies four pivotal unmet needs along with reasonable solutions to address them, aiming to improve management of IRDs and preparing the upcoming approval of voretigene neparvovec in Portugal.

## REFERENCES

1. Weisschuh N, Obermaier CD, Battke F, et al. Genetic architecture of inherited retinal degeneration in Germany: A large cohort study from a single diagnostic center over a 9-year period. *Hum Mutat* 2020;41(9):1514-1527. DOI: 10.1002/humu.24064.
2. Maguire AM, Bennett J, Aleman EM, Leroy BP, Aleman TS. Clinical Perspective: Treating RPE65-Associated Retinal Dystrophy. *Mol Ther* 2020 (Epub ahead of print). DOI: 10.1016/j.ymthe.2020.11.029.
3. Russell S, Bennett J, Wellman JA, et al. Efficacy and safety of voretigene neparvovec (AAV2-hRPE65v2) in patients with RPE65-mediated inherited retinal dystrophy: a randomised, controlled, open-label, phase 3 trial. *Lancet* 2017;390(10097):849-860. DOI: 10.1016/S0140-6736(17)31868-8.
4. Maguire AM, Russell S, Wellman JA, et al. Efficacy, Safety, and Durability of Voretigene Neparvovec-rzyl in RPE65 Mutation-Associated Inherited Retinal Dystrophy: Results of Phase 1 and 3 Trials. *Ophthalmology* 2019;126(9):1273-1285. DOI: 10.1016/j.ophtha.2019.06.017.
5. Shah M, Shanks M, Packham E, et al. Next generation sequencing using phenotype-based panels for genetic testing in inherited retinal diseases. *Ophthalmic Genet* 2020;41(4):331-337. DOI: 10.1080/13816810.2020.1778736.
6. Lorenz B, Tavares J, van den Born LI, Marques JP, Scholl HPN. Current management of Inherited Retinal Degenerations (IRD) patients in Europe. Results of a multinational survey by the European Vision Institute Clinical Research Network EVICR.net. *Ophthalmic Res* 2021 (Epub ahead of print). DOI: 10.1159/000514540.
7. Suppiej A, Marino S, Reffo ME, et al. Early onset retinal dystrophies: clinical clues to diagnosis for pediatricians. *Ital J Pediatr* 2019;45(1):168. DOI: 10.1186/s13052-019-0760-5.
8. Consugar MB, Navarro-Gomez D, Place EM, et al. Panel-based genetic diagnostic testing for inherited eye diseases is highly accurate and reproducible, and more sensitive for variant detection, than exome sequencing. *Genet Med* 2015;17(4):253-261. DOI: 10.1038/gim.2014.172.
9. Thompson DA, Ali RR, Banin E, et al. Advancing therapeutic strategies for inherited retinal degeneration: recommendations from the Monaciano Symposium. *Invest Ophthalmol Vis Sci* 2015;56(2):918-31. DOI: 10.1167/iovs.14-16049.
10. Marques JP, Carvalho AL, Henriques J, Murta JN, Saraiva J, Silva R. Design, development and deployment of a web-based interoperable registry for inherited retinal dystrophies

in Portugal: the IRD-PT. Orphanet J Rare Dis 2020;15(1):304. DOI: 10.1186/s13023-020-01591-6.



Manuscript 2

## **2.2. The need for widely available genomic testing in rare eye diseases: an ERN-EYE position statement**

Graeme C Black

Panagiotis Sergouniotis

Andrea Sodi

Bart P Leroy

Caroline Van Cowenberg

Petra Liskova

Karen Grønskov

Artur Klett

Susanne Kohl

Gita Taurina

Marius Sukys

Lonneke Haer-Wigman

Katarzyna Nowomiejska

João Pedro Marques

Dorothee Leroux

Frans P M Cremers

Elfride De Baere

Hélène Dollfus

ERN-EYE study group

*Published in: Orphanet J Rare Dis. 2021 Mar 20;16(1):142.*

## **ABSTRACT**

### **Background**

Rare Eye Diseases (RED) are the leading cause of visual impairment and blindness for children and young adults in Europe. This heterogeneous group of conditions includes over 900 disorders ranging from relatively prevalent disorders such as retinitis pigmentosa to very rare entities such as developmental eye anomalies. A significant number of patients with RED have an underlying genetic etiology. One of the aims of the European Reference Network for Rare Eye Diseases (ERN-EYE) is to facilitate improvement in diagnosis of RED in European member states.

### **Main body**

Technological advances have allowed genetic and genomic testing for RED. The outcome of genetic testing allows better understanding of the condition and allows reproductive and therapeutic options. The increase of the number of clinical trials for RED has provided urgency for genetic testing in RED. A survey of countries participating in ERN-EYE demonstrated that the majority are able to access some forms of genomic testing. However, there is significant variability, particularly regarding testing as part of clinical service. Some countries have a well-delineated rare disease pathway and have a national plan for rare diseases combined or not with a national plan for genomics in medicine. In other countries, there is a well-established organization of genetic centers that offer reimbursed genomic testing of RED and other rare diseases. Clinicians often rely upon research-funded laboratories or private companies. Notably, some member states rely on cross-border testing by way of an academic research project. Consequently, many clinicians are either unable to access testing or are confronted with long turnaround times. Overall, while the cost of sequencing has dropped, the cumulative cost of a genomic testing service for populations remains considerable. Importantly, the majority of countries reported healthcare budgets that limit testing.

### **Short conclusion**

Despite technological advances, critical gaps in genomic testing remain in Europe, especially in smaller countries where no formal genomic testing pathways exist. Even within larger countries, the existing arrangements are insufficient to meet the demand and to ensure access. ERN-EYE promotes access to genetic testing in RED and emphasizes the clinical need and relevance of genetic testing in RED.

## **BACKGROUND**

Technological advances have allowed genetic and genomic testing for Rare Eye Diseases (RED). The outcome of genetic testing allows better understanding of RED and allows reproductive and therapeutic options. Despite these advances critical gaps in testing remain in European member states, especially in smaller countries. Even within larger countries, the existing arrangements are insufficient to meet the demand and to ensure equity of access. The European Reference Network (ERN) initiative, a cross-border cooperation between healthcare providers and researchers from across the European Union, has been created to improve diagnosis and treatment of complex or rare medical conditions that require specialized treatment, knowledge and resources.<sup>1</sup> ERN-EYE promotes access to genetic testing in RED and emphasizes the clinical need and relevance of genetic testing in RED.

## **MAIN TEXT**

There are 24 thematic ERNs, including ERN-EYE, whose focus is on RED.<sup>2</sup> The ERNs seek to aggregate healthcare providers in order to improve patient access to healthcare information and thereby increase treatment options. They aim to do this by (i) creating innovative care models, in particular using digital technologies, (ii) enhancing research through the increase of the size and power of clinical studies as well as epidemiological registries and (iii) enabling sharing of costly resources which ultimately leads to more sustainable national healthcare systems. The overarching objective is to improve health outcomes for the large numbers of patients in the EU suffering from rare and often complex conditions.

RED are the leading cause of visual impairment and blindness for children and young adults in Europe.<sup>3,4</sup> This heterogeneous group of conditions includes over 900 disorders ranging from relatively prevalent disorders such as retinitis pigmentosa (estimated prevalence of 1 in 4,000) to very rare entities described only once or twice in medical literature.<sup>5</sup> ERN-EYE is structured around 4 clinical thematic working groups (Retina, Neuro-ophthalmology, Pediatric, Anterior segment) and 6 transversal working groups (Low vision, Genetic diagnostic, Registries, Research, Education/Training, Communication).<sup>2</sup> Notably, the ERN-EYE has organized workshops on diverse areas ranging from clinical terminology standardization (Mont Sainte-Odile workshop, 2017) to genomic testing (Florence workshop, 2018) and clinical trials (Strasbourg workshop, 2019).<sup>6</sup>

The advance towards personalization of medicine is accelerating.<sup>7</sup> For rare diseases, including RED, there is now a general understanding that patients often experience delayed diagnosis, which in turn leads to poor access to appropriate treatment and management protocols. For RED, a significant number of patients have an underlying genetic etiology. Effective and individualized approaches to clinical management are consequently dependent upon a

comprehensive means of delivering genetic or genomic testing.<sup>8</sup> Genomic testing allows a precise diagnosis of highly heterogeneous disorders, improves counselling (e.g. understanding prognosis; facilitating reproductive decision-making) and is increasingly important in directing treatment options.<sup>9</sup>

### **Genomic approaches can improve diagnosis and management of RED**

There are now numerous examples demonstrating clinical benefit of genomic testing in RED. For example, for oculocutaneous albinism, genetic diagnostic approaches provide a positive diagnosis in over 75% of cases. This not only achieves a diagnosis in early life for individuals with reduced vision but also allows identification of syndromic forms including the 1 in 30 cases of apparently uncomplicated albinism that represent unsuspected cases of Hermansky-Pudlak syndrome implying specific surveillance and care.<sup>10</sup>

Leber Congenital Amaurosis (LCA) is the earliest onset and most severe form of inherited retinal diseases (IRD).<sup>11</sup> This group of conditions is caused by genetic alterations in over 20 genes and is also the field where most clinical research is performed to date.<sup>12-14</sup> Some examples are given where comprehensive genomic testing leads to a molecular diagnosis and offers therapeutic perspectives. A first example are pathogenic variants in the RPE-specific gene *RPE65* encoding a protein member of the visual cycle that regenerates retinal. The recent FDA and EMA approval of *voretigene neparvovec-rzyl* for the treatment of LCA patients with biallelic *RPE65* mutations, as a landmark of novel gene-directed therapy, paved the way for successful treatment.<sup>15-18</sup> A second example is a recurrent deep-intronic pathogenic variant in *CEP290*, a gene encoding a key component of the connecting cilium. There are promising clinical studies suggesting potential for intravitreally delivered antisense oligonucleotide (AON) therapy and for gene editing using CRISPR/Cas9.<sup>19-21</sup> Pathogenic variants in *CEP290* and other cilia-related genes (e.g. *IQCB1*) can predispose for multi-systemic complications including renal failure.<sup>22,23</sup> Other examples requiring an early diagnosis are *AILP1*- and *GUCY2D*-associated LCA given the ongoing therapeutic efforts.<sup>24-27</sup>

Moreover, *CLN3*-associated Batten disease, first diagnosed by ophthalmologists, is another example where early diagnosis is critical to direct management, counseling, and support for young patients and their families. The systemic therapeutic options for this disease in early-phase clinical trial benefit from a start at the earliest stage of disease.<sup>28,29</sup>

Other examples are pathogenic variants identified in disease genes implicated in achromatopsia,<sup>30</sup> choroideremia,<sup>31</sup> Stargardt disease (STGD1), X-linked retinitis pigmentosa and other IRD<sup>33,34</sup> that are eligible for the huge range of clinical trials being undertaken currently.<sup>12-</sup>

<sup>14</sup> Specifically, rare and recurrent deep-intronic pathogenic variants (total: 355) in *ABCA4*

associated with STGDI in ~10% of cases allow the design of novel RNA splice modulation therapies using AONs.<sup>35-37</sup>

Patient groups, clinicians and scientists together recognize an urgent need for widespread availability of genomic testing for RED to avoid the so-called 'diagnostic odyssey' - an extended and distressing period, often unsuccessful, characterized by multiple sequential investigations. By providing a definitive molecular diagnosis this can strongly facilitate clinical and personal decision-making.<sup>38,39</sup>

### **What is the current picture of genomic testing in RED?**

Adoption of genomic testing for RED has accelerated considerably over the past 10 years due to the availability of 'next generation sequencing' (NGS), a technological advance allowing massively parallel sequencing of multiple nucleic acid targets.<sup>38</sup> This technique is increasingly being deployed in the clinical diagnostic setting and it has allowed affordable analysis of complete genomes.<sup>40,41</sup>

A survey of countries participating in ERN-EYE demonstrated that the majority are able to access some forms of genomic testing. However, access is still far from universal and there is significant variability of delivery, particularly in the degree to which different countries are able to provide testing as part of clinical service. It is not uncommon for clinicians to have to rely partly or completely upon either research-funded laboratories (for example in the Czech Republic) or private companies. Notably, some member state relies mainly on cross-border testing either by way of an academic research project. For example, research-based sequencing of the entire *ABCA4* gene for variants associated with STGDI in the Netherlands and Belgium has yielded bi-allelic variants in ~500 probands ascertained worldwide, including many undiagnosed families from Eastern European countries.<sup>35-37</sup> Currently 2,000 STGDI and STGD-like maculopathy probands have been sequenced for mutations in *ABCA4* and *PRPH2*, solving ~50% of the cases.

In the US, *Invitae* has announced a free sequencing service for RED probands from the US based on a partnership with *Spark Therapeutics*.<sup>41</sup> The Foundation Fighting Blindness, in partnership with *Blueprint Genetics* and *InformedDNA*, offers free genetic testing and counselling to individuals living in the US or US territories and clinically diagnosed with an IRD.<sup>42</sup>

In Europe, some countries have a very well delineated rare disease pathway (summarized in Table 1). In France for example, there is a long-standing national centralized organizational plan for rare diseases (*Plan National Maladies Rares*)<sup>43</sup> now combined with a centralized national plan for genomics in medicine (*Plan France Médecine Génomique*).<sup>44</sup> In the UK, a small number of Genomic Laboratory Hubs and a highly productive national initiative (100,000 Genomes;

Genomic England) allow relatively frictionless access to testing.<sup>45</sup> In Belgium and the Netherlands there is a well-established organization of genetic centers with good access to reimbursed genomic testing of RED and other rare diseases. In Germany, academic genetic centers, private genetic laboratories but also industrial laboratories offer this service. Other member states such as Italy rely on regional organization where University centers have, over time, developed significant expertise in specific RED fields.

Within this overall picture, critical gaps in testing remain, especially in a number of smaller countries where no formal genomic testing structures exist. Notably, even within larger countries, the existing arrangements are insufficient to meet the demand and to ensure equity of access. Consequently, across the EU there are large numbers of clinicians and affected families who are either unable to access testing or who have to wait for considerable periods of time to receive results. Overall, while the cost of genomic sequencing has dropped at an extraordinary rate over the past decade, the cumulative cost of providing a comprehensive genomic testing service for populations remains considerable. Importantly, the majority of EU countries reported healthcare budgets that limit testing despite the fact that increase in demand (i.e. numbers of patients requiring testing) is inevitable.<sup>46</sup>

### ***Clinical utility: making the argument to justify genomic testing***

It is perhaps not surprising that translation of clinical, technological and research advances into routine healthcare is slow. Undoubtedly, the adoption of a clinically relevant intervention—in this case, genomic testing—is more likely where its ability to influence management and health outcomes has been clearly demonstrated. Therefore, a focus on clinical benefit ('clinical utility') of genomic testing remains an urgent requirement to provide a clear evidence for widespread implementation.<sup>47,48</sup> To date, compiling such evidence for RED has been slow. However, evidence of clinical utility has been demonstrated for small groups of patients.<sup>49-</sup>  
<sup>53</sup> Additional, well-designed studies of broader scale are becoming available.<sup>7,54</sup>

**Table I. Rare disease pathway summary and access to genetic testing by country**

QUESTIONS TO OUR MEMBERS ? (oct 2018 with March 2020 update)	Beg	Cze	Den	Est	Fra	Ger	Ita	Lat	Lit	NL	UK	Pol	Por
Are there National initiatives for Genetic testing (GT) such a National Plan?		Y	N	Y	Y	N	N	N	Y	?	Y	N	N
Is there a unique national model for the consent form? (thus HCP specific)		N	?	N	Y	N	N	Y	N	N	Y	N	N
Are most of the tests done with academic hospital laboratories?				Y	Y	Y	Y	Y	Y	Y	Y	Y	Y
Are tests done by industrial partners?				Y	N	N/Y	Y	Y	N	N	N	Y	Y
Are there samples sent abroad for genetic testing?		Y	N	Y	N	N	N	95%	rare	N	N	Y	Y
Can the ophthalmologist prescribe the genetic test?		Sanger only	Y	Y	Y	Y	Y	N	N	Y	Y	Y	Y
Are there national rule for genetic prescription of test?		Y	N	Y	Y	N	N	N	Y	Y	Y	N	N
Are there multidisciplinary meetings in the GT course?		Y	Y	Y	Y	Y	Y	Y	Y	Y	Y	Y	Y
Do you have access to Sanger sequencing?		Y	Y	Y	Y	Y	Y	Y	Y	Y	Y	Y	Y
Do you have access to panel testing?		Y	Y	Y	Y	Y	Y	Y	Y	Y	Y	Y	Y
Do you have access to Whole exome sequencing for GT in your country?		N	N	N	Y	N	Y	N	Y	Y	Y	Y	Y
Do you have access to Whole genome sequencing for GT in your country?		N	N	N	Y	N	N	N	N	?	Y	N	N
Do you have access to WES for research only?		Y	Y	Y	N	N	N	?	N	N	N	?	N
Do you have access to WGS for research only?		Y	Y	Y	N	Y	Y	?	Y	?	N	?	N
Is the patient reimbursed for GT (Panels, Sanger)?		Y	Y	Y	Y	Y	Y	Y	Y	Y	Y	?	Y
Is the patient reimbursed for WES?		N	Y	-na	Y	N	Y/N	Y	Y	Y	Y	N	Y
Is the patient reimbursed for WGS?		-na	-na	-na	soon	N	-na	Y	-na	Y	Y	N	N
Are there enough specialists in genetic ophthalmology in your MS?		N	?	N	N	N	N	N	N	N	N	N	N
Is there a national genetic database?		N	Y	Y	N	N	N	N	?	Y	Y	N	N
Is there a national biobank?				Y	N	N	N	N	?	Y	Y	N	N

Abbreviations used: BE: Belgium; CZ: Czech Republic; DK: Denmark; ES: Spain; FR: France; GE: Germany; IT: Italy; LV: Latvia; LT: Lithuania; NL: Netherlands; UK: United Kingdom; PL: Poland; PT: Portugal

### ***Training and mainstreaming of genomic medicine***

Genomic testing is only one of the barriers that exist for effective diagnosis and management for individuals with RED. It is clear that the number of healthcare professionals and genetic counsellors who specialize in ophthalmic genetics is another important limiting factor, even in settings where genomic testing is readily available. Notably, at present, care for families with RED is generally delivered by a few “super-specialists” in ophthalmic genetics who work within a relatively small number of academic centers. Given the cumulative prevalence and overall number of RED, and the increasing recognition of clinical need, this dependence of small groups of experts is likely to be unsustainable.

Broadening access to genomic testing will require an expansion of the group of clinicians who are willing and able to order such diagnostic tests. Since this requires specialist knowledge, training of a wider group of clinicians at all strata of seniority will be necessary. While in the longer term this sits within medical schools and professional curricula, in the shorter term it will be critical to provide professional development that enables up-skilling of existing clinical workforces. There will be different levels of skills required for different groups of clinicians. Pediatric ophthalmologists and medical retina specialists who encounter RED more frequently are perhaps the first who need to acquire these new skills and to enhance their understanding of the care pathways, consent issues and utilization of genomic knowledge in clinical management. However, it is expected that in the not-so-distant future, broader applications of genomic medicine such as pharmacogenetics and complex genetics will be increasingly important to all clinicians.

Technological advances of DNA sequencing technologies have tremendously expanded the ability of healthcare systems to diagnose RED. This gives great hope to affected families. Harnessing the motivating power of patient groups and hearing the patient voice is critical in promoting systematic change in healthcare provision. The ERN-EYE initiative has been strongly influenced by patient bodies and advocates. These interactions have greatly enhanced our understanding of how a definitive genetic diagnosis can promote closure, lead to early resolution of uncertainty, allow better understanding of the condition and, crucially, inform reproductive and life planning. However, ultimately, implementation of such advanced diagnostic strategies will require considerable increased investment. Thus, there is an urgent need for professionals to provide broad evidence of clinical benefit and utility. The extraordinary acceleration in the number of clinical trials for RED in general and for inherited retinal disorders in particular, has provided considerable urgency and impetus.

### **CONCLUSIONS**

- Technological advances have allowed genomic testing for RED.



- Despite these advances critical gaps in testing remain, especially in smaller countries where no formal genomic testing structures exist. Even within larger countries, the existing arrangements are insufficient to meet the demand and to ensure equity of access.
- The outcome of genetic testing allows better understanding of the condition and allows reproductive and therapeutic options. The increase of the number of clinical trials for RED has provided considerable urgency for genetic testing in RED.
- ERN-EYE promotes access to genetic testing in RED and emphasizes the clinical need and relevance of genetic testing in RED.

## REFERENCES

1. ERN description on European Commission official website [Internet]. Public Health - Eur. Comm. 2016 [cited 2020 Sep 29]. Available from: [https://ec.europa.eu/health/ern\\_en](https://ec.europa.eu/health/ern_en)
2. ERN-EYE official website [Internet]. ERN-EYE. [cited 2020 Sep 29]. Available from: <https://www.ern-eye.eu/>
3. Solebo AL, Teoh L, Rahi J. Epidemiology of blindness in children. *Arch Dis Child*. 2017;102:853–7.
4. Liew G, Michaelides M, Bunce C. A comparison of the causes of blindness certifications in England and Wales in working age adults (16–64 years), 1999–2000 with 2009–2010. *BMJ Open*. 2014;4:e004015.
5. Verbakel SK, van Huet RAC, Boon CJF, den Hollander AI, Collin RWJ, Klaver CCW, *et al*. Non-syndromic retinitis pigmentosa. *Prog Retin Eye Res*. 2018;66:157–86.
6. Sergouniotis PI, Maxime E, Leroux D, Olry A, Thompson R, Rath A, *et al*. An ontological foundation for ocular phenotypes and rare eye diseases. *Orphanet J Rare Dis*. 2019;14:8.
7. Zeggini E, Gloyn AL, Barton AC, Wain LV. Translational genomics and precision medicine: Moving from the lab to the clinic. *Science*. 2019;365:1409–13.
8. Lenassi E, Clayton-Smith J, Douzgou S, Ramsden SC, Ingram S, Hall G, *et al*. Clinical utility of genetic testing in 201 preschool children with inherited eye disorders. *Genet Med Off J Am Coll Med Genet*. 2020;22:745–51.
9. Claussnitzer M, Cho JH, Collins R, Cox NJ, Dermitzakis ET, Hurles ME, *et al*. A brief history of human disease genetics. *Nature*. 2020;577:179–89.

10. Lasseaux E, Plaisant C, Michaud V, Pennamen P, Trimouille A, Gaston L, *et al.* Molecular characterization of a series of 990 index patients with albinism. *Pigment Cell Melanoma Res.* 2018;31:466–74.
11. Kumaran N, Moore AT, Weleber RG, Michaelides M. Leber congenital amaurosis/early-onset severe retinal dystrophy: clinical features, molecular genetics and therapeutic interventions. *Br J Ophthalmol.* 2017;101:1147–54.
12. Vázquez-Domínguez I, Garanto A, Collin RWJ. Molecular Therapies for Inherited Retinal Diseases-Current Standing, Opportunities and Challenges. *Genes.* 2019;10.
13. Garafalo AV, Cideciyan AV, Héon E, Sheplock R, Pearson A, WeiYang YuC, *et al.* Progress in treating inherited retinal diseases: Early subretinal gene therapy clinical trials and candidates for future initiatives. *Prog Retin Eye Res.* 2020;77:100827.
14. Cideciyan AV, Jacobson SG. Leber Congenital Amaurosis (LCA): Potential for Improvement of Vision. *Invest Ophthalmol Vis Sci.* 2019;60:1680–95.
15. Research C for BE and. Luxturna description on U.S Food and Drug website [Internet]. FDA. 2019 [cited 2020 Sep 26]. Available from: <https://www.fda.gov/vaccines-blood-biologics/cellular-gene-therapy-products/Luxturna>
16. Luxturna description on European Medicines Agency website [Internet]. EMA. 2018 [cited 2020 Sep 29]. Available from: <https://www.ema.europa.eu/en/medicines/human/EPAR/Luxturna>
17. Guidance for Luxturna on National Institute for Health and Care Excellence website [Internet]. NIH. NICE; [cited 2020 Sep 29]. Available from: <https://www.nice.org.uk/guidance/hst11>
18. LUXTURNA on Haute Autorité de Santé website [Internet]. HAS. [cited 2020 Sep 29]. Available from: [https://www.has-sante.fr/jcms/c\\_2964759/fr/Luxturna](https://www.has-sante.fr/jcms/c_2964759/fr/Luxturna)
19. Duijkers L, van den Born LI, Neidhardt J, Bax NM, Pierrache LHM, Klevering BJ, *et al.* Antisense Oligonucleotide-Based Splicing Correction in Individuals with Leber Congenital Amaurosis due to Compound Heterozygosity for the c.2991+1655A>G Mutation in CEP290. *Int J Mol Sci.* 2018;19.
20. Cideciyan AV, Jacobson SG, Drack AV, Ho AC, Charng J, Garafalo AV, *et al.* Effect of an intravitreal antisense oligonucleotide on vision in Leber congenital amaurosis due to a photoreceptor cilium defect. *Nat Med.* 2019;25:225–8.
21. Ledford H. CRISPR treatment inserted directly into the body for first time. *Nature.* 2020;579:185.
22. Bachmann-Gagescu R, Neuhaus SC. The photoreceptor cilium and its diseases. *Curr Opin Genet Dev.* 2019;56:22–33.

23. Ellingford JM, Sergouniotis PI, Lennon R, Bhaskar S, Williams SG, Hillman KA, *et al.* Pinpointing clinical diagnosis through whole exome sequencing to direct patient care: a case of Senior-Loken syndrome. *Lancet Lond Engl.* 2015;385:1916.
24. Aboshiha J, Dubis AM, van der Spuy J, Nishiguchi KM, Cheeseman EW, Ayuso C, *et al.* Preserved outer retina in AIPL1 Leber's congenital amaurosis: implications for gene therapy. *Ophthalmology.* 2015;122:862–4.
25. Sacristan-Reviriego A, Le HM, Georgiou M, Meunier I, Bocquet B, Roux A-F, *et al.* Clinical and functional analyses of AIPL1 variants reveal mechanisms of pathogenicity linked to different forms of retinal degeneration. *Sci Rep.* 2020;10:17520.
26. Bouzia Z, Georgiou M, Hull S, Robson AG, Fujinami K, Rotsos T, *et al.* GUCY2D-associated leber congenital amaurosis: a retrospective natural history study in preparation for trials of novel therapies. *Am J Ophthalmol.* 2020;210:59–70.
27. Jacobson SG, Cideciyan AV, Sumaroka A, Roman AJ, Charng J, Lu M, *et al.* Defining outcomes for clinical trials of leber congenital amaurosis caused by GUCY2D mutations. *Am J Ophthalmol.* 2017;177:44–57.
28. Wright GA, Georgiou M, Robson AG, Ali N, Kalhor A, Holthaus SK, *et al.* Juvenile batten disease (CLN3): detailed ocular phenotype, novel observations, delayed diagnosis, masquerades, and prospects for therapy. *Ophthalmol Retina.* 2020;4:433–45.
29. Dulz S, Atiskova Y, Wibbeler E, Wildner J, Wagenfeld L, Schwering C, *et al.* An ophthalmic rating scale to assess ocular involvement in juvenile CLN3 disease. *Am J Ophthalmol.* 2020;220:64–71.
30. Hirji N, Aboshiha J, Georgiou M, Bainbridge J, Michaelides M. Achromatopsia: clinical features, molecular genetics, animal models and therapeutic options. *Ophthalmic Genet.* 2018;39:149–57.
31. Cehajic Kapetanovic J, Patrício MI, MacLaren RE. Progress in the development of novel therapies for choroideremia. *Expert Rev Ophthalmol.* 2019;14:277–85.
32. De Silva SR, Arno G, Robson AG, Fakin A, Pontikos N, Mohamed MD, *et al.* The X-linked retinopathies: Physiological insights, pathogenic mechanisms, phenotypic features and novel therapies. *Prog Retin Eye Res.* 2020;100898.
33. Rahman N, Georgiou M, Khan KN, Michaelides M. Macular dystrophies: clinical and imaging features, molecular genetics and therapeutic options. *Br J Ophthalmol.* 2020;104:451–60.
34. Gill JS, Georgiou M, Kalitzeos A, Moore AT, Michaelides M. Progressive cone and cone-rod dystrophies: clinical features, molecular genetics and prospects for therapy. *Br J Ophthalmol.* 2019;103(5):711-720

35. Bauwens M, Garanto A, Sangermano R, Naessens S, Weisschuh N, De Zaeytijd J, *et al.* ABCA4-associated disease as a model for missing heritability in autosomal recessive disorders: novel noncoding splice, cis-regulatory, structural, and recurrent hypomorphic variants. *Genet Med Off J Am Coll Med Genet.* 2019;21:1761–71.
36. Sangermano R, Garanto A, Khan M, Runhart EH, Bauwens M, Bax NM, *et al.* Deep-intronic ABCA4 variants explain missing heritability in Stargardt disease and allow correction of splice defects by antisense oligonucleotides. *Genet Med Off J Am Coll Med Genet.* 2019;21:1751–60.
37. Khan M, Cornelis SS, Pozo-Valero MD, Whelan L, Runhart EH, Mishra K, *et al.* Resolving the dark matter of ABCA4 for 1054 Stargardt disease probands through integrated genomics and transcriptomics. *Genet Med Off J Am Coll Med Genet.* 2020;22:1235–46.
38. Shendure J, Balasubramanian S, Church GM, Gilbert W, Rogers J, Schloss JA, *et al.* DNA sequencing at 40: past, present and future. *Nature.* 2017;550:345–53.
39. Boycott KM, Hartley T, Biesecker LG, Gibbs RA, Innes AM, Riess O, *et al.* A diagnosis for all rare genetic diseases: the horizon and the next frontiers. *Cell.* 2019;177:32–7.
40. Lappalainen T, Scott AJ, Brandt M, Hall IM. Genomic analysis in the age of human genome sequencing. *Cell.* 2019;177:70–84.
41. Inherited retinal Disease Gene Testing Program on Invitae website [Internet]. INVITEAE. [cited 2020 Sep 29]. Available from: <https://www.invitae.com/en/sponsored-testing/ophthalmology/>
42. Genetic Testing for Inherited Retinal Diseases through the Foundation’s Open Access Program on Fighting Blindness Foundation website [Internet]. Found. Fight. Blind. [cited 2020 Sep 29]. Available from: <https://www.fightingblindness.org/research/genetic-testing-for-inherited-retinal-diseases-through-the-foundation-s-open-access-program-79>
43. Rare diseases description on official French government website [Internet]. DGOS Ministère Solidar. Santé. 2021 [cited 2020 Sep 29]. Available from: <https://solidarites-sante.gouv.fr/soins-et-maladies/prises-en-charge-specialisees/maladiesrares/article/les-maladies-rares>
44. Plan France Médecine Génomique 2025 / aviesan [Internet]. [cited 2021 Jan 26]. Available from: <https://www.aviesan.fr/aviesan/accueil/toute-l-actualite/plan-france-medecine-genomique-2025>
45. Genomics England website [Internet]. Genomics Engl. [cited 2020 Sep 29]. Available from: <https://www.genomicsengland.co.uk/>

46. The Cost of Sequencing a Human Genome on National Human Genome Research Institute website [Internet]. [cited 2020 Sep 29]. Available from: <https://www.genome.gov/about-genomics/fact-sheets/Sequencing-Human-Genome-cost>
47. Peterson JF, Roden DM, Orlando LA, Ramirez AH, Mensah GA, Williams MS. Building evidence and measuring clinical outcomes for genomic medicine. *Lancet Lond Engl*. 2019;394:604–10.
48. Sergouniotis PI. Inherited retinal disorders: using evidence as a driver for implementation. *Ophthalmol J Int Ophtalmol Int J Ophthalmol Z Augen- heilkd*. 2019;242:187–94.
49. Gillespie RL, Urquhart J, Anderson B, Williams S, Waller S, Ashworth J, et al. Next-generation sequencing in the diagnosis of metabolic disease marked by pediatric cataract. *Ophthalmology*. 2016;123:217–20.
50. Gillespie RL, O’Sullivan J, Ashworth J, Bhaskar S, Williams S, Biswas S, et al. Personalized diagnosis and management of congenital cataract by next-generation sequencing. *Ophthalmology*. 2014;121:2124–2137.e1–2.
51. Taylor RL, Parry NRA, Barton SJ, Campbell C, Delaney CM, Ellingford JM, et al. Panel-based clinical genetic testing in 85 children with inherited retinal disease. *Ophthalmology*. 2017;124:985–91.
52. Haer-Wigman L, van Zelst-Stams WA, Pfundt R, van den Born LI, Klaver CC, Verheij JB, et al. Diagnostic exome sequencing in 266 Dutch patients with visual impairment. *Eur J Hum Genet EJHG*. 2017;25:591–9.
53. Birtel J, Gliem M, Oishi A, Müller PL, Herrmann P, Holz FG, et al. Genetic testing in patients with retinitis pigmentosa: Features of unsolved cases. *Clin Experiment Ophthalmol*. 2019;47:779–86.
54. Carss KJ, Arno G, Erwood M, Stephens J, Sanchis-Juan A, Hull S, et al. Comprehensive rare variant analysis via whole-genome sequencing to determine the molecular pathology of inherited retinal disease. *Am J Hum Genet*. 2017;100:75–90.



Manuscript 3

**2.3. Design, development and deployment of a web-based interoperable registry for Inherited Retinal Dystrophies in Portugal – The IRD-PT**

João Pedro Marques

Ana Luísa Carvalho

José Henriques

Joaquim Neto Murta

Jorge Saraiva

Rufino Silva

*Published in: Orphanet J Rare Dis. 2020 Oct 27;15(1):304.*

## **ABSTRACT**

### **Background**

The development of multicenter patient registries promotes the generation of scientific knowledge by using real-world data. A country-wide, web-based registry for inherited retinal dystrophies (IRDs) empowers patients and community organizations, while supporting formal partnerships with investigators and stakeholders in the global aim to develop high-value, high-utility research. We aim to describe the design, development and deployment of a country-wide, web-based, user-friendly and interoperable registry for IRDs – the IRD-PT.

### **Results**

The IRD-PT is a clinical/genetic research registry included in the *retina.pt* platform (<http://www.retina.com.pt>), which was developed by the Portuguese Retina Study Group. The *retina.pt* platform collects data on individuals diagnosed with retinal diseases, from several sites across Portugal, with over 1800 participants and over 30,000 consultations to date. The IRD-PT module interacts with the *retina.pt* core system which provides a range of basic functions for patient data management, while the IRD-PT module allows data capture for the specific purpose of IRDs. All IRDs are coded accordingly to the International Statistical Classification of Diseases and Related Health Problems (ICD) 9, ICD 10, ICD 11, and Orphanet Rare Disease Ontology (ORPHA codes) to make the IRD-PT interoperable with other IRD registries across the world. Furthermore, the genes are coded according to the Ontology of Genes and Genomes and Online Mendelian Inheritance in Man, whereas signs and symptoms are coded according to the Human Phenotype Ontology. The IRD-PT module pre-launched at *Centro Hospitalar e Universitário de Coimbra*, the largest reference center for IRDs in Portugal. As of April 1<sup>st</sup> 2020, finalized data from 537 participants were available for this preliminary analysis.

### **Conclusions**

In the specific field of rare diseases, the use of registries increases research accessibility for individuals, while providing clinicians/investigators with a coherent data ecosystem necessary to boost research. Appropriate design and implementation of patient registries enables rapid decision making and ongoing data mining, ultimately leading to improved patient outcomes. We have described here the principles behind the design, development and deployment of a web-based, user-friendly and interoperable software tool aimed to generate important knowledge and collecting high-quality data on the epidemiology, genomic landscape and natural history of IRDs in Portugal.



## BACKGROUND

The Agency for Healthcare Research and Quality defines a registry as “an organized system that uses observational study methods to collect uniform data (clinical and other) to evaluate specified outcomes for a population defined by a particular disease, condition, or exposure, and that serves one or more predetermined scientific, clinical, or policy purposes”.<sup>1</sup> Clinical registries have existed for decades in the field of ophthalmology,<sup>2-5</sup> serving a variety of purposes, which include (1) capturing the epidemiologic features of an ocular disease or condition, (2) tracking outcomes and complications of drugs or procedures, (3) recording adverse events, or (4) combinations of the above.<sup>6</sup> In recent years, policy makers started recognizing clinical registries as an important tool for improving the value of healthcare. Outcome data is now used to fill in gaps of evidence that cannot be provided by randomized controlled trials.<sup>6</sup> Furthermore, data from clinical registries is also increasingly being used to facilitate learning networks and to establish research collaborations between scientific researchers, clinicians, industry, regulators, patient organizations, patients and families.<sup>7</sup> This is especially true for rare diseases where the small number of cases for each disease creates additional barriers in the translational research pathway, and makes identification and establishment of a substantial cohort a very difficult task.

Inherited retinal dystrophies (IRDs) are a clinically and genetically heterogenous group of diseases with an estimated prevalence of 1 in 3,000 individuals.<sup>8</sup> Despite some common ground, genetic profiles vary considerably among regions and ethnic groups,<sup>9-16</sup> thus highlighting the importance of obtaining reference population-based data. The presence of founder mutations may greatly contribute for these differences, as observed in a large Israeli population.<sup>9</sup> While local hospital-based registries may provide high quality information and resources, their coverage is usually small. To fully understand the prevalence and genomic landscape of IRDs, we must connect knowledge that is widespread throughout miscellaneous registries. The development of multicenter patient registries and natural history studies promote the generation of scientific knowledge by using real-world data. As rare diseases gain visibility as a public health priority and the marketplace expands, acknowledgement of the importance of building collaborative relationships in rare disease research increases.<sup>7</sup> A national, web-based registry for IRDs is able to empower patients and community organizations, while supporting formal partnerships with investigators and stakeholders in the global aim to develop high-value, high-utility research.

When developing a registry, it is essential to ensure that it is ethically governed, user-friendly and designed with maximum sustainability. This includes the implementation of foundational, structural, semantic, and organizational interoperability processes to optimize the utility of data and allow its linkage to other existing or future registries.<sup>7</sup> By making data

computationally accessible, it is possible to bridge compatibility gaps between different hospitals, healthcare systems, registries and languages.<sup>17</sup> Adoption of comprehensive phenotype and rare disease ontologies enables this type of sharing by making data findable, accessible, interoperable, and re-usable (FAIR principles).<sup>18</sup> These features have made Orphanet Rare Disease Ontology (ORDO) a standard for rare disease coding in European health-care systems and led to the widespread adoption of ontologies like the Human Phenotype Ontology (HPO) by global genomics initiatives, like the European Reference Network for Rare Eye Disease (ERN-EYE).<sup>17</sup>

The purpose of this study is to describe the design, development and deployment of a country-wide, web-based, user-friendly and interoperable registry for IRDs – the IRD-PT.

## RESULTS

### **Data Capture**

The IRD-PT was designed to capture longitudinal data on IRDs. The data captured by the IRD-PT module is kept to a minimum to deliver an efficient and user-friendly data collecting tool. The user must complete all the mandatory fields/check all the mandatory boxes in order to save the entry. However, the system allows editing and/or completion of previously unanswered non-mandatory fields at the user's convenience. The list of covered clinical diagnoses is shown on Table 1, while the list of the genes and their respective Ontology of Genes and Genomes (OGG) and Mendelian Inheritance in Man (MIM) numbers are shown on Table 2. Even though inherited optic neuropathies and other genetically-associated retinal diseases (such as Pseudoxanthoma Elasticum-associated retinopathy or isolated foveal hypoplasia) are not IRDs *per se*, we opted to include them in the registry since these are common diagnoses in an Ophthalmic Genetics clinic. This is not something previously unseen. In fact, these diseases are also part of the Inherited Retinal Disease Classification proposed by Stone et al<sup>16</sup>.

We were able to design an interoperable module by reusing the *retina.pt* core data elements where appropriate (epidemiological data such as sex, date of birth and patient ID), whilst also incorporating bespoke data elements, sections and forms for the specific field of IRDs (Table 3). Upon selection of a particular item (clinical diagnosis, signs and symptoms, syndromic features, gene or additional diagnoses), a hyperlink is available to direct the user to the correspondent ontology webpage (ORPHA, HPO, OGG).

The family linkage section allows simple viewing of the details of affected family members that are also part of the registry. At the end of each visit, a free text area is available for comments (follow-up, imaging, prescription, etc).

Longitudinal data is captured through specific follow-up forms. The platform allows retrospective data introduction. As the program develops, and through alignment with

international data collection for IRD clinical registries, the IRD-PT core data set may be modified or extended to include additional key clinical variables.

**Table 2** List and ORPHA numbers of the clinical diagnoses covered by the IRD-PT module

<b>INHERITED RETINAL DYSTROPHIES*</b> ORPHA 71862		
<p><b>1. Isolated Progressive Inherited Retinal Disorder (ORPHA 519306)</b></p> <p>1.1. Retinitis Punctata Albescens (ORPHA 52427)</p> <p>1.2. ARB (ORPHA 139455)</p> <p>1.3. Cone/Cone-rod dystrophy (ORPHA 1872)</p> <p>1.4. Late-Onset Retinal Degeneration (ORPHA 67042)</p> <p>1.5. Leber Congenital Amaurosis (ORPHA 65)</p> <p>1.6. Retinitis Pigmentosa AR (ORPHA 791)</p> <p>1.7. Retinitis Pigmentosa AD (ORPHA 791)</p> <p>1.8. Retinitis Pigmentosa XL (ORPHA 791)</p> <p><b>1.9. Isolated Macular Dystrophy (ORPHA 519302)</b></p> <p>1.9.1. Sorsby Fundus Dystrophy (59181)</p> <p>1.9.2. Stargardt disease (ORPHA 827)</p> <p>1.9.3. Best Vitelliform Macular Dystrophy (ORPHA 1243)</p> <p>1.9.4. North Carolina Macular Dystrophy (ORPHA 75327)</p> <p><b>1.10. Pattern Dystrophy (ORPHA 63454)</b></p> <p>1.10.1. Butterfly-shaped pigment dystrophy (ORPHA 99001)</p> <p>1.10.2. MFD simulating fundus flavimaculatus (ORPHA 99003)</p> <p>1.10.3. Reticular Dystrophy of the RPE (ORPHA 99002)</p> <p>1.10.4. AOFVD (ORPHA 99000)</p> <p><b>2. Isolated Stationary Inherited Retinal Disorder (ORPHA 519319)</b></p> <p>2.1. Achromatopsia (ORPHA 49382)</p> <p>2.2. CSNB (ORPHA 215)</p> <p>2.3. Fundus Albipunctatus (ORPHA 227796)</p> <p>2.4. Familial drusen / Malattia leventinese (ORPHA 75376)</p>	<p><b>3. Syndromic Inherited Retinal Disorder (ORPHA 519325)</b></p> <p>3.1. Alström Syndrome (ORPHA 64)</p> <p>3.2. Jalili Syndrome (ORPHA 1873)</p> <p>3.3. Senior-Loken Syndrome (ORPHA 3156)</p> <p>3.4. Joubert Syndrome (ORPHA 475)</p> <p>3.5. Usher Syndrome (ORPHA 886)</p> <p>3.6. Bardet-Biedl Syndrome (ORPHA 110)</p> <p>3.7. Hallervorden-Spatz Syndrome (ORPHA 157850)</p> <p>3.8. Syndromic Retinitis Pigmentosa - Other (ORPHA 519325)</p> <p>3.9. Kearns-Sayre syndrome (ORPHA 480)</p> <p>3.10. PXE (ORPHA 758)</p> <p>3.11. Alport Syndrome (ORPHA 63)</p> <p>3.12. MIDD (ORPHA 225)</p> <p>3.13. Cuticular drusen/C3 Glomerulopathy (ORPHA 329918)</p> <p><b>4. Inherited Vitreous Dystrophies (ORPHA 519304)</b></p> <p>4.1. X-linked Retinoschisis (ORPHA 792)</p> <p>4.2. Stickler syndrome (ORPHA 828)</p> <p>4.3. Wagner disease (ORPHA 898)</p> <p>4.4. FFEVR (ORPHA 891)</p> <p>4.5. Goldmann-Favre syndrome/ESCS</p> <p>4.6. ADVIRC (ORPHA 3086)</p>	<p><b>5. Chorioretinal Dystrophies (ORPHA 519300)</b></p> <p>5.1. Bietti Crystalline Dystrophy (ORPHA 41751)</p> <p>5.2. CACD (ORPHA 75377)</p> <p>5.3. Choroideremia (ORPHA 180)</p> <p>5.4. Gyrate Atrophy of Choroid and Retina (ORPHA 414)</p> <p>5.5. Helicoid Peripapillary Chorioretinal Degeneration (ORPHA 86813)</p> <p>5.6. Pigmented Paravenous Retinochoroidal Atrophy (ORPHA 251295)</p> <p><b>6. Hereditary Optic Neuropathy (ORPHA 98671)</b></p> <p>6.1. Autosomal dominant Optical Atrophy (ORPHA 98672)</p> <p>6.2. Leber Hereditary Optic Atrophy (ORPHA 104)</p> <p>6.3. Hereditary Optic Neuropathy - Other (98671)</p> <p><b>7. Other Rare Disorders of the Posterior Segment of the Eye (ORPHA 519311)</b></p> <p>7.1. Foveal hypoplasia (ORPHA 519398)</p> <p>7.2. Coloboma (ORPHA 98942)</p> <p>7.3. Ocular albinism (ORPHA 284804)</p> <p>7.4. Oculocutaneous Albinism (ORPHA 55)</p> <p>7.5. Other</p>

\* The platform allows the selection of more than one diagnosis.

MFD – multifocal pattern dystrophy; AOFVD – adult-onset foveomacular vitelliform dystrophy; CSNB – congenital stationary night blindness; PXE – pseudoxanthoma elasticum; MIDD – maternally-inherited diabetes and deafness; FEVR – familial exudative vitreoretinopathy; ADVIRC – autosomal-dominant vitreoretinochoroidopathy; CACD – central areolar choroidal dystrophy

**Table 3** List of available IRD genes\* and their respective Ontology of Genes and Genomes (OGG) and Mendelian Inheritance in Man (MIM) numbers

ABCA4	OGG:3000000024	MIM:601691	LRAT	OGG:3000009227	MIM:604863
ABCC6	OGG:3000000368	MIM:603234	MAK	OGG:3000004117	MIM:154235
ADGRV1	OGG:3000084059	MIM:602851	MERTK	OGG:3000010461	MIM:604705
AIP1	OGG:3000023746	MIM:604392	MT-ND1	OGG:3000004535	MIM:516000
ALMS1	OGG:3000007840	MIM:606844	MT-ND4	OGG:3000004538	MIM:516003
BBS1	OGG:3000000582	MIM:209901	MT-ND4L	OGG:3000004539	MIM:516004
BBS10	OGG:3000079738	MIM:610148	MT-ND6	OGG:3000004541	MIM:516006
BBS12	OGG:3000166379	MIM:610683	MT-TL1	OGG:3000004567	MIM:590050
BBS2	OGG:3000000583	MIM:606151	MYO7A	OGG:3000004647	MIM:276903
BBS3/ARL6	OGG:3000084100	MIM:608845	NMNAT1	OGG:3000064802	MIM:608700
BBS4	OGG:3000000585	MIM:600374	NR2E3	OGG:3000010002	MIM:604485
BBS5	OGG:3000129880	MIM:603650	NRL	OGG:3000004901	MIM:162080
BBS7	OGG:3000055212	MIM:607590	NYX	OGG:3000060506	MIM:300278
BBS9	OGG:3000027241	MIM:607968	OAT	OGG:3000004942	MIM:613349
BEST1	OGG:3000007439	MIM:607854	OPA1	OGG:3000004976	MIM:605290
CIQTNF5	OGG:3000114902	MIM:608752	OPN1LW	OGG:3000005956	MIM:300822
CACNA1F	OGG:3000000778	MIM:300110	PANK2	OGG:3000080025	MIM:606157
CDH23	OGG:3000064072	MIM:605516	PAX6	OGG:3000005080	MIM:607108
CEP290	OGG:3000080184	MIM:610142	PCARE	OGG:3000388939	MIM:613425
CERKL	OGG:3000001399	MIM:608381	PDE6A	OGG:30000005145	MIM:180071
CFH	OGG:3000003075	MIM:134370	PDE6B	OGG:30000005158	MIM:180072
CHM	OGG:3000001121	MIM:300390	PDE6C	OGG:30000005146	MIM:600827
CLN3	OGG:3000001201	MIM:607042	PDE6G	OGG:30000005148	MIM:180073
CLRN1	OGG:3000007401	MIM:606397	PHYH	OGG:30000005264	MIM:602026
CNGA3	OGG:3000001261	MIM:600053	POC1B	OGG:3000282809	MIM:614784
CNGB1	OGG:3000001258	MIM:600724	PRCD	OGG:3000768206	MIM:610598
CNGB3	OGG:3000054714	MIM:605080	PROM1	OGG:3000008842	MIM:604365
CNNM4	OGG:3000026504	MIM:607805	PRPF3	OGG:30000009129	MIM:607301
COL2A1	OGG:3000001280	MIM:120140	PRPF31	OGG:3000026121	MIM:606419
COL4A3	OGG:3000001285	MIM:120070	PRPF8	OGG:3000010594	MIM:607300
COL4A4	OGG:3000001286	MIM:120131	PRPH2 (RDS)	OGG:30000005961	MIM:179605
COL4A5	OGG:3000001287	MIM:303630	RDH12	OGG:3000145226	MIM:608830
CRB1	OGG:3000023418	MIM:604210	RDH5	OGG:30000005959	MIM:601617
CRX	OGG:3000001406	MIM:602225	RHO	OGG:30000006010	MIM:180380
CYP4V2	OGG:3000285440	MIM:608614	RIMS1	OGG:3000022999	MIM:606629
DHDDS	OGG:3000079947	MIM:608172	RLBP1	OGG:30000006017	MIM:180090
EFEMP1	OGG:3000002202	MIM:601548	RPI	OGG:30000006101	MIM:3937
ELOVL4	OGG:30000006785	MIM:605512	RP2	OGG:30000006102	MIM:300757
EYS	OGG:3000346007	MIM:612424	RPE65	OGG:30000006121	MIM:180069
FAM161A	OGG:3000084140	MIM:613596	RPGR	OGG:30000006103	MIM:312610
GNAT1	OGG:3000002779	MIM:139330	RPGRIPI	OGG:300000057096	MIM:605446
GNAT2	OGG:3000002780	MIM:139340	RS1	OGG:30000006247	MIM:300839
GPR98	OGG:3000084059	MIM:602851	SAG	OGG:30000006295	MIM:181031
GRK1	OGG:3000006011	MIM:180381	SEMA4A	OGG:3000064218	MIM:607292
GUCA1A	OGG:3000002978	MIM:600364	SNRNP200	OGG:3000023020	MIM:601664
GUCA1B	OGG:3000002979	MIM:602275	SPATA7	OGG:30000005812	MIM:609868
GUCY2D	OGG:3000003000	MIM:600179	TIMP3	OGG:30000007078	MIM:188826
HGSNAT	OGG:3000138050	MIM:610453	TOPORS	OGG:3000010210	MIM:609507
IMPDH1 (RP10)	OGG:3000003614	MIM:146690	TULP1	OGG:30000007287	MIM:602280
IMPG1	OGG:3000003617	MIM:602870	USH1G	OGG:3000124590	MIM:607696
IMPG2	OGG:3000050939	MIM:607056	USH2A	OGG:30000007399	MIM:608400
IQCB1	OGG:3000009657	MIM:609237	VCAN	OGG:30000001462	MIM:118661
KCNV2	OGG:3000169522	MIM:607604	WDR19	OGG:30000005728	MIM:608151
KLHL7	OGG:3000055975	MIM:111119	Other	N/A	N/A
LCA5	OGG:3000167691	MIM:611408	Inconclusive	N/A	N/A

\*The user may select one, two or more genes in case clinically relevant variants are found in more than one gene. This list may be edited with newer additions in case other genes are found in the Portuguese population with IRDs.

**Table 4** Data set for the IRD-PT module, including the Human Phenotype Oncology (HPO) coding when applicable.

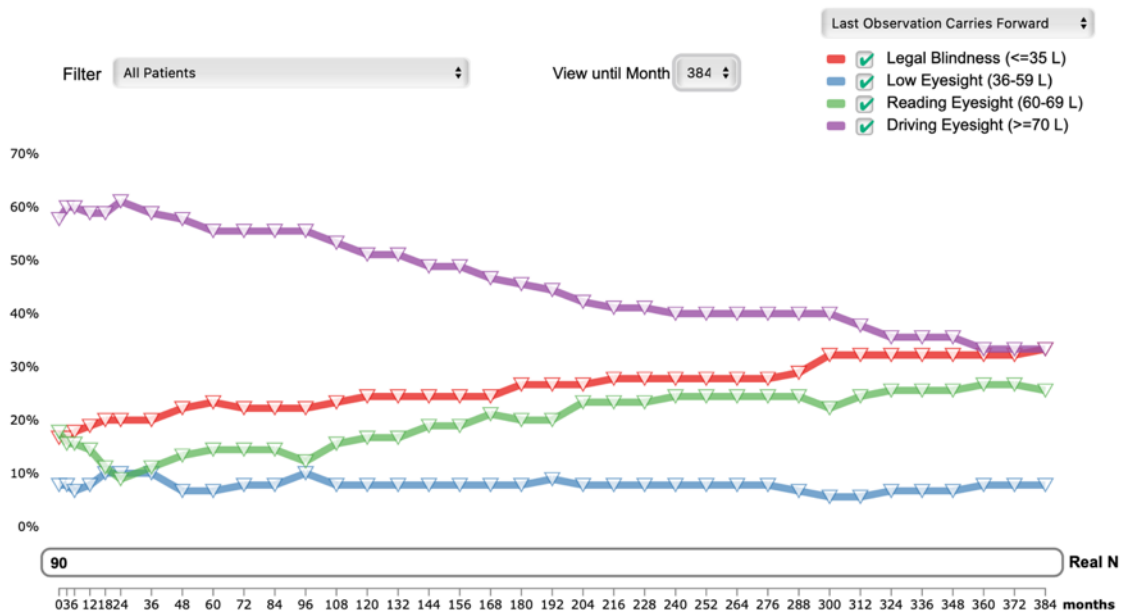
Field	Type of Entry	Answer	Available Options
<b>1. Patient ID</b>	Free text	Mandatory	
<b>2. Date of Birth</b>	Date format	Mandatory	
<b>3. Sex</b>	Select from list	Mandatory	Male; Female
<b>4. Date of Diagnosis</b>	Date format	Mandatory	
<b>5. Clinical Diagnosis</b>	Select from list (allows selection of more than one option)	Mandatory	see table 1
<b>6. Consanguinity</b>	Select from list	Mandatory	Yes; No; Suspected
<b>7. Family History</b>	Select from list	Mandatory	Yes; No; Suspected
<b>7.1. Family linkage section</b> (only shows if the user answered Yes to the previous question)	Allows introduction of one or multiple affected family members, including their family relation to the patient (brother; sister; mother; father; son; daughter; uncle; aunt; cousin; grandfather; grandmother; other) and Hospital ID which has a hyperlink to that patient's page in case he/she has consented to be part of the registry		
<b>8. Signs and Symptoms</b>	Select from list (allows selection of more than one option)	Mandatory	nyctalopia (HP:0000662); decreased VA (HP:0000529); photophobia (HP:0000613); color vision defects (HP:0000551); central scotoma (HP:0000603); constricted visual field (HP:0001133); photopsia (HP:0030786); nystagmus (HP:0000639); headache (HP:0002315); migraine (HP:0002076); visual hallucinations (HP:0002367); other
<b>9. Age of onset of symptoms</b>	Select from list	Mandatory	at birth ; <5; 6-10; 11-20; 21-30; 31-50; >51
<b>10. Syndromic Features</b>	Select from list	Mandatory	Yes/No
<b>10.1. Syndromic features list</b> (only shows if the user answered Yes to the previous question)	Select from list (allows selection of more than one option)	Optional	hearing loss/deafness (HP:0008527); obesity (HP:0001513); hypogonadism (HP:0000135); diabetes mellitus (HP:0000819); diabetes insipidus (HP:0000873); polydactyly (HP:0010442); other skeletal abnormalities (HP:0000924); cognitive impairment (HP:0100543); developmental delay (HP:0001263); seizures (HP:0001250); ataxia (HP:0001251); dysarthria (HP:0001260); renal insufficiency (HP:0000083); other
<b>11. Genetic Testing</b>	Select from list	Mandatory	Yes/No
<b>11.1. Type of test</b> (only shows if the user answered Yes to Genetic Testing)	Select from list (allows selection of more than one option)	Optional	Sanger sequencing; NGS panel; WES; MLPA; don't know; other
<b>11.2. Gene</b> (only shows if the user	Select from list (allows selection of more than one option)	Optional	see table 2

answered Yes to Genetic Testing)			
<b>11.3. Variants</b> \$ (only shows if the user answered Yes to Genetic Testing)	Free text	Optional	
<b>11.4. Classification of Variants (ACMG)</b> (only shows if the user answered Yes to Genetic Testing)	Select from list (for each introduced variant)	Optional	pathogenic; likely pathogenic; VUS
<b>BCVA</b> *	Select from list	Mandatory	From 20/1000 to 20/10
<b>IOP</b> *	Free text	Optional	Only accepts numbers from 01 to 99
<b>Additional diagnoses</b> *	Select from list (allows selection of more than one option)	Optional	amblyopia (HP:0000646); cataract (HP:0000518); CNV (HP:0011506); CME (HP:0011505); glaucoma (HP:0000501); ERM (HP:0100014); macular hole (HP:0011508); lamellar hole (HP:0001103); macular pseudohole (HP:0001103); vitreomacular traction (HP:0031151); retinal detachment (HP:0000541); keratoconus (HP:0000563); strabismus (HP:0000486); other
<b>Previous treatments</b> *	Select from list (allows selection of more than one option)	Optional	vitreoretinal surgery; strabismus surgery; glaucoma surgery; YAG laser capsulotomy; corneal transplant; cataract surgery; intravitreal injection; subretinal injection; laser photocoagulation; refractive surgery; other

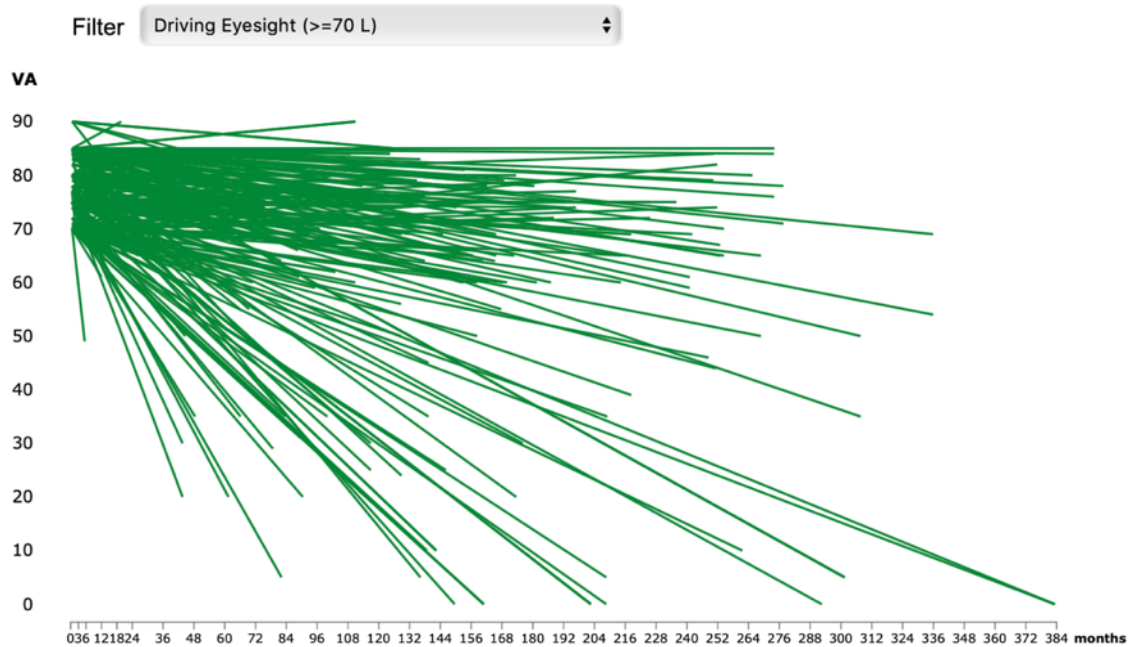
DOB – date of birth; NGS – next generation sequencing; WES – whole exome sequencing; MLPA – multiplex ligation-dependent probe amplification; ACMG – American College of Medical Genetics and Genomics; VUS – variant of uncertain significance; BCVA – best corrected visual acuity; IOP – intraocular pressure; CNV – choroidal neovascularization; CME – cystoid macular edema; ERM – epiretinal membrane. \$ - apart from listing the variants as free text, an icon is available for the upload of the raw sequencing file; \* - these fields appear separately for the right and left eye

### **Data Analysis and Graphical Displays**

Since the *retina.pt* was designed to be both a registry and a research tool, data export and analysis features are very important. A search engine that allows data filtering is available for the user to search specific anonymized data, such as the total number of affected patients or the total number of affected families with a certain disease-causing gene, clinical diagnosis, BCVA level, etc. Furthermore, the platform offers statistical tools for simple analyses and these are also available for the IRD-PT module (Figures 1 and 2). For more sophisticated analyses, users can export their own data on *excel* format and analyze it as they see fit. Data are aggregated in an anonymized fashion, without identification of the individual patients.



**Figure 1.** Variation in the percentage of eyes with different levels of BCVA (ETDRS letters) over time (last-observation carried forward) in the 45 patients (90 eyes) with Usher syndrome included in the IRD-PT registry so far. The graph is automatically provided by the platform. The user may select which parameters to show. It is also possible to select only one eye per patient.



**Figure 2** Progression of BCVA (ETDRS letters) over follow-up (last-observation carried forward) in eyes with any IRD that started with driving vision ( $\geq 70$  ETDRS letters). Each green line corresponds to an eye of an individual patient. The graph is automatically provided by the platform. The user may select which parameters to show.

### **Participant Characteristics**

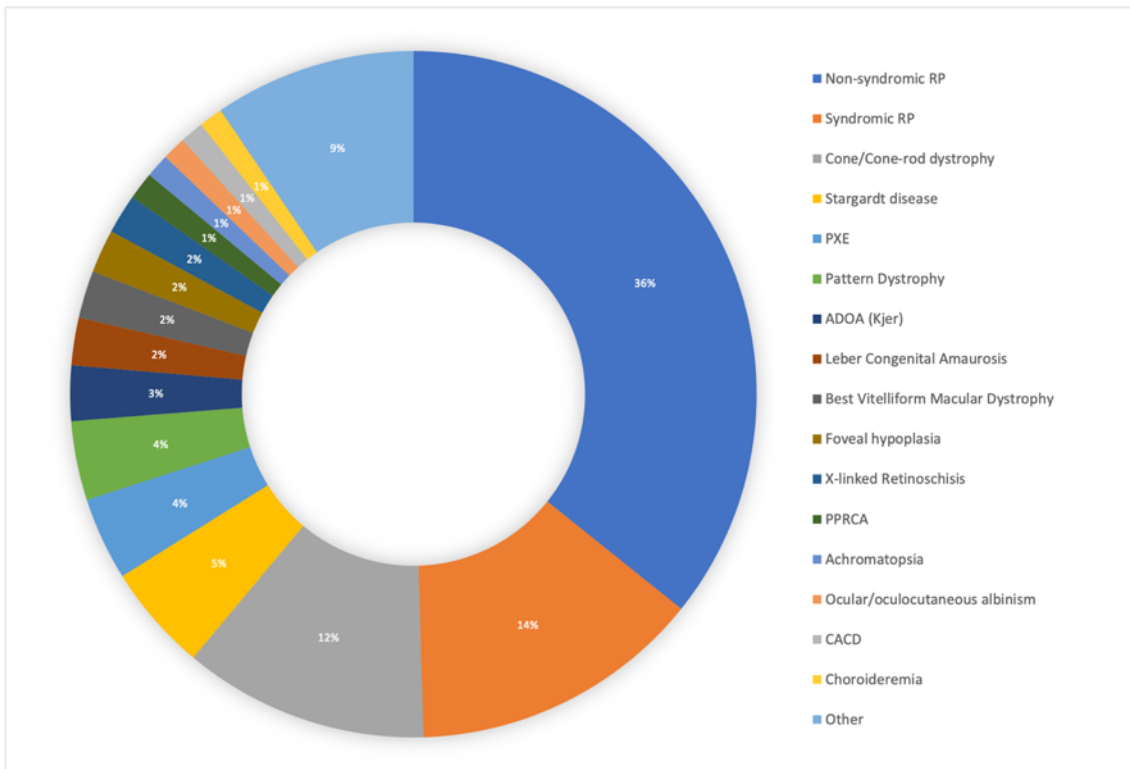
So far, the *retina.pt* platform has been approved by the Human Research Ethics Committee (HREC)/Institutional Review Board (IRB) of 52 health care providers across Portugal. Each of these hospitals/clinics has established the necessary infrastructure to support rapid rollout of site and patient recruitment, data collection, and data transfer. One-hundred and thirty five users (doctors/investigators) have applied for credentials to access the registry, and 58 of these have already included patient data. To date, there are over 1800 participants (patients) and over 30,000 consultations included in the registry. In mid 2019, the IRD-PT module was pre-launched at *Centro Hospitalar e Universitário de Coimbra* (CHUC), the only Portuguese health care provider (HCP) that is a member of the ERN-EYE, and the largest reference center for IRDs in Portugal. The idea of testing the registry in one dedicated center before its national debut was aimed to identify possible problems during data completion, test the time spent in data entry, and detect information gaps or system inaccuracies. The registry proved fully functional, fast and easy to use. As of April 1<sup>st</sup> 2020, finalized data from 537 participants were available for this preliminary analysis. Considering the Portuguese population (~10 million inhabitants), this number corresponds to roughly 1/6 of the total estimated cases of IRDs in Portugal. The distribution of the clinical diagnoses and their relative frequency among the included participants is shown in Table 4. As illustrated in Figure 3, syndromic (14%) and non-syndromic retinitis pigmentosa (36%) account for 50% of the clinical diagnoses. The percentage of genetically solved and unsolved cases of syndromic and non-syndromic RP is shown in Figure 4. Of all participants included in the IRD-PT registry to date, 57% are women and the mean age at the index visit was  $39.27 \pm 19.03$  years. Average baseline BCVA was  $54.36 \pm 27.22$  and final BCVA was  $47.64 \pm 28.92$  ETDRS letters.



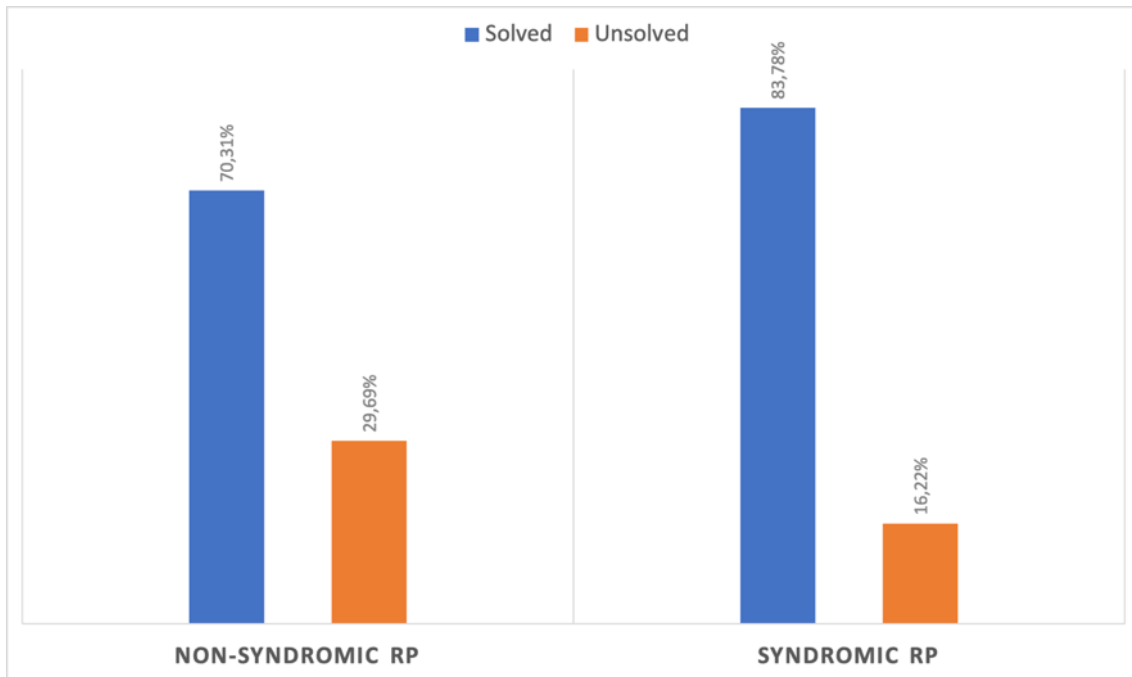
**Table 4** Distribution of the clinical IRD diagnoses and their relative frequency among the 537 subjects included in the IRD-PT registry

Clinical Diagnosis	n	Relative frequency (%)
Non-syndromic RP	192	35.75%
Syndromic RP	74	13.78%
Cone/Cone-rod dystrophy	62	11.55%
Stargardt disease	27	5.03%
PXE	21	3.91%
Pattern Dystrophy	20	3.72%
ADOA (Kjer)	14	2.61%
Leber Congenital Amaurosis	12	2.23%
Best Vitelliform Macular Dystrophy	12	2.23%
Foveal hypoplasia	11	2.05%
X-linked Retinoschisis	10	1.86%
PPRCA	7	1.30%
Achromatopsia	6	1.12%
Ocular/oculocutaneous albinism	6	1.12%
CACD	6	1.12%
Choroideremia	6	1.12%
CSNB	5	0.93%
Coloboma	5	0.93%
ARB	4	0.74%
Bietti Crystalline Dystrophy	4	0.74%
Fundus Albipunctatus	4	0.74%
MIDD	4	0.74%
Gyrate Atrophy of Choroid and Retina	3	0.56%
Goldmann-Favre syndrome/ESCS	3	0.56%
Stickler/Wagner syndrome	3	0.56%
Cuticular drusen/C3 Glomerulopathy	3	0.56%
LORD	3	0.56%
LHON	3	0.56%
ADVIRC	2	0.37%
Retinitis Punctata Albescens	2	0.37%
Alport Syndrome	2	0.37%
NCMD	1	0.19%

RP – Retinitis Pigmentosa; PXE – Pseudoxanthoma Elasticum; ADOA – Autosomal Dominant Optic Atrophy; PPRCA – Pigmented Paravenous Retinochoroidal Atrophy; CACD – Central Areolar Choroidal Dystrophy; CSNB – Congenital Stationary Night Blindness; ARB – Autosomal Recessive Bestrophinopathy; MIDD – Maternally Inherited Diabetes and Deafness; ESCS – Enhanced S-Cone Syndrome; LORD – Late-onset Retinal Degeneration; LHON – Leber Hereditary Optic Neuropathy; ADVIRC – Autosomal Dominant Vitreoretinopathopathy; NCMD – North Carolina Macular Dystrophy



**Figure 3** Graphical representation of the relative frequency of each clinical diagnosis in the 537 patients included in the IRD-PT registry. Those with <1% cases are expressed under the tag *Other*. RP – retinitis pigmentosa; PXE – pseudoxanthoma elasticum; ADOA – autosomal dominant optic atrophy; PPRCA – pigmented paravenous retinochoroidal atrophy; CACD – central areolar choroidal dystrophy.



**Figure 4** Graphical representation of the percentage of genetically solved and genetically unsolved cases of syndromic and non-syndromic retinitis pigmentosa in our cohort.

## DISCUSSION

Appropriate design, implementation and deployment of patient registries enables rapid decision making and ongoing data mining, ultimately leading to improved patient outcomes.<sup>7,19,20</sup> In the specific field of rare diseases, the use of registries increases research accessibility for individuals, while providing clinicians/investigators with a coherent data ecosystem necessary to boost research. The IRD-PT module of *retina.pt* will facilitate the efficient capture of accurate, longitudinal, country-wide data for IRDs. The registry will provide valuable information on disease prevalence, genomic landscape, genotype-phenotype correlations and natural history of IRDs, which is currently an unmet need in Portugal. Furthermore, the registry will facilitate patient selection for newly approved treatments or enrollment in clinical trials. The use of a web-based data storage system allows the registry to extend recruitment across multiple centers in the country. The modular design and scalable nature of the framework used to deploy the IRD-PT registry make it easily adaptable over time, ensuring its long-term sustainability. Furthermore, the use of domain-specific ontologies adds value to data, through an integrated knowledge base that is searchable and comparable by user and by machines.<sup>17,21</sup> In fact, by resorting to common data elements, core outcome sets, and standardized data structures, the IRD-PT module can support the exchange of data across datasets, facilitating the connection to other registries at an international level. The interoperability of this registry by means of data harmonization is a key feature pointing to its utility and scalability. Another important issue of a web-based registry is usability, i.e. the capacity of a software system to provide conditions for

its users to perform the tasks satisfactorily, effectively, and efficiently. Ophthalmologists have limited time with patients during office visits, and electronic health record (EHR) use requires a substantial portion of that time, therefore affecting productivity.<sup>22,23</sup> The *retina.pt* registry combines a user-friendly platform and reduced load of data entry with the possibility to generate a *pdf* document that can be saved, printed or copied to the hospital EHR system, thus eliminating the need for duplicate records. Additionally, there is also the possibility of EHR third party applications with structured information to deliver their data directly to specific subfields of the registry, thus enabling a quick fill in process. The detailed information provided on Table 3 regarding data capture for the IRD-PT may be used to modify EHR systems to allow for direct data transfer. Finally, the versatility of the platform, makes it possible to serve as electronic case report form (eCRF) for upcoming observational, natural-history or post-market authorization studies.

The IRD-PT is not exempt of limitations. An important principle in registry design is to reduce the load of data entry. This does not come without a price. By limiting the data that is considered mandatory to a minimum, there may be incomplete information/missing data for some included subjects concerning unanswered non-mandatory fields. Another limitation is that grading systems/levels for the symptoms or degree of impairment are not available. The fact that symptoms are simply marked as present/not present prevents a precise characterization of these symptoms during the disease course. Finally, since each user is responsible for its own data entry, we cannot be sure about the accuracy of its contents. This may be particularly problematic when a case is considered molecularly solved or unsolved. Misinterpretation of the genetic findings is not uncommon, which may lead to selection bias regarding the number of molecularly solved/unsolved cases.

## **CONCLUSIONS**

We have described here the principles behind the design, development and deployment of a web-based software tool that forms the basis of a nation-wide registry for IRDs. The pre-launch of the IRD-PT module in the largest Portuguese referral center for IRDs (CHUC), allowed to test the functionalities of the registry and enroll the first 537 IRD patients, roughly 1/6 of the total estimated cases of IRDs in Portugal. Now that the module is fully working, recruitment will be extended to other Portuguese hospitals. Judging from the enthusiasm and adherence observed with the launch of the *retina.pt* platform, we believe that the IRD-PT registry will be rapidly adopted by the Portuguese ophthalmologists managing IRD patients. Our hope is to generate important knowledge and collect high-quality data on the epidemiology, genomic landscape, genotype-phenotype correlations and natural history of IRDs in Portugal. This will

both boost and excel clinical research in the field of IRDs in our country, while facilitating patient access to clinical trials or new therapies.

## **METHODS**

### ***Registry Design***

The IRD-PT is a clinical/genetic research registry. Its main goal is to create a national, web-based registry of IRDs in Portugal that allows to study their prevalence, genomic profile, genotype-phenotype correlations and natural history. Also, the registry may assist in the recruitment of participants for new treatments/clinical trials, and provide support for the establishment of disease-specific standards and care. The IRD-PT registry is included in the *retina.pt* platform (<http://www.retina.com.pt>), which was developed by the Portuguese Retina Study Group (GER, [www.ger-portugal.com](http://www.ger-portugal.com)). The *retina.pt* registry deployed in 2017 to fulfil a vital component on patient-centered care for retinal diseases. It collects data on individuals diagnosed with retinal diseases, from several sites across Portugal, with over 1800 participants and over 30,000 consultations to date. The IRD-PT is a module interacting with the *retina.pt* core system. The core system provides a range of basic functions used for patient data management, while the IRD-PT module provides the user with the functionality to capture data for the specific purpose of IRDs.

### ***Recruitment and Informed Consent***

Both pediatric and adult patients with a genetic and/or clinical diagnosis of IRD living in Portugal and attending Ophthalmology clinics around the country are invited to participate. Participation in the registry is voluntary. Before enrollment, the participant (patient) or their legally authorized representative must provide informed consent for the collection, storage, and use of their personal health data. No costs or compensations are involved for participants or their family members as the data collected in the IRD-PT module refers to information routinely collected by the responsible physician. All included subjects are allowed to withdraw their consent at any time, without providing a reason. This does not impact their regular follow-up at the clinic.

### ***Ethics and Regulations***

The registry meets the necessary requirements for compliance with the General Data Protection Regulation (GDPR) of the European Union and all approvals were obtained prior to recruiting patients for the registry. Formal review and approval was obtained from the Portuguese Data Protection Authority (*Comissão Nacional de Proteção de Dados – CNPD*), HREC of *Centro Hospitalar e Universitário de Coimbra* (CHUC) and IRB of the Faculty of Medicine of the

University of Coimbra (FMUC). All these independent entities ensured that the study protocol, governance, protections, and methods were ethical and appropriate. Furthermore, each participating core center needs to obtain approval from the respective Ethics Committee. Documentation of approval from each center is copied to the central governing office to ensure currency of approval is maintained.

All investigators (users) are mandated to sign the Investigator Declaration Form before obtaining credentials to use the registry. Both the project investigators and their institutions permit project-related monitoring, audits, and regulatory inspections, providing direct access to source data/documents. This may include, but is not limited to, review by HREC and institutional governance review bodies.

### **Data Protection**

Proper handling of ethical, legal, social, and privacy issues must be a foundational component of the design, implementation, and long-term sustainability of a patient registry.<sup>7</sup> As part of the *retina.pt*, the IRD-PT module was designed to provide maximum data security and patient anonymity. Several well-defined procedures were put in place to protect individual patient data within the registry study. Data security, integrity, and availability is monitored and regulated.

All data transmissions between the user and the server are encrypted using 128-bit encryption (Secure Sockets Layer). The data are stored and backed up on secure servers at Portugal Telecom – Altice, TEAR 3 certified Datacenter. Anonymity of users is also closely guarded. Individual users can only see their own data. However, users may find other centers with included data on a specific disease and ask for research collaborations within the platform. Users can withdraw their data from the registry at any time, without providing a reason.

### **Registry Interface**

Drop-down menus, pop-up explanatory notes, and tab-to-jump ensures rapid and user friendly data entry. Furthermore, *retina.pt* is a web-based application that is able to run on different server operating systems. Any device with Internet access and a recent browser can be used to interact with the application. Additional software on the user's terminal is not required. When all mandatory fields have been filled, the User can "Finalize" the visit by pressing "Save". The system has been designed in such a way that it will not allow a visit to be finalized unless all the mandatory fields have been filled and all numerical data fall within prespecified ranges. Additionally, the platform allows data to be automatically filled in by third party EHR applications with identically structured information, or the possibility of the user to generate a

pdf document that can be printed/copied to the hospital EHR system. Moreover, storage and retrieval of clinical images is possible in the patient-specific page.

### **Data Quality**

High quality data of rare diseases registries is considered to be one of the most important elements in the establishment and maintenance of a registry.<sup>20</sup> Quality assurance includes quality improvement activities such as medical, clinical, and record audit and observational studies, to which the ethical principles of research apply.

### **Interoperability**

Upon the development of the *retina.pt* platform, interoperability was a key issue. First, the registry has two available languages to choose from: Portuguese and English. Second, the age-related macular degeneration (AMD) module of *retina.pt* is already linked to the Fight Retinal Blindness! (FRB!) Project registry<sup>2</sup> and efforts are in place to connect it to the International Consortium for Health Outcomes Measurement (ICHOM) AMD registry. Third, the platform is serving as the eCRF for an upcoming post-market authorization clinical trial. Rare diseases are a prime example of a research area that can strongly profit from coordination on a European and international scale. To allow interoperability of the IRD-PT module with other IRD registries across the world, all the diseases are coded accordingly to ICD9, ICD10, ICD11, and ORDO (ORPHA codes) numbers. Furthermore, the genes are coded according to the OGG and MIM, and patient signs and symptoms are coded according to HPO. This is in accordance with the eye-specific dataset of the Clinical Patient Management System (CPMS) of the ERN-EYE.<sup>17</sup> Notably, ORDO, HPO, OGG and MIM are open-access, interoperable, community-driven, available in multiple languages and regularly updated.

## **REFERENCES**

1. Gliklich RE, Dreyer NA, Leavy MB, Quintiles Outcome (Firm), United States. Agency for Healthcare Research and Quality, Effective Health Care Program (U.S.). Registries for evaluating patient outcomes : a user's guide. AHRQ publication no 13(14)-EHC111. Third edition. ed. Rockville, MD: Agency for Healthcare Research and Quality,; 2014:1 online resource (2 PDF files (2 volumes)).
2. Gillies MC, Walton R, Liong J, et al. Efficient capture of high-quality data on outcomes of treatment for macular diseases: the fight retinal blindness! Project. *Retina* 2014;34(1):188-95. DOI: 10.1097/IAE.0b013e318296b271.

3. Chiang MF, Sommer A, Rich WL, Lum F, Parke DW, 2nd. The 2016 American Academy of Ophthalmology IRIS((R)) Registry (Intelligent Research in Sight) Database: Characteristics and Methods. *Ophthalmology* 2018;125(8):1143-1148. DOI: 10.1016/j.ophtha.2017.12.001.
4. Lundstrom M, Manning S, Barry P, Stenevi U, Henry Y, Rosen P. The European registry of quality outcomes for cataract and refractive surgery (EUREQUO): a database study of trends in volumes, surgical techniques and outcomes of refractive surgery. *Eye Vis (Lond)* 2015;2:8. DOI: 10.1186/s40662-015-0019-1.
5. Lum F, Schachat AP, Jampel HD. The development and demise of a cataract surgery database. *Jt Comm J Qual Improv* 2002;28(3):108-14. DOI: 10.1016/s1070-3241(02)28010-4.
6. Tan JCK, Ferdi AC, Gillies MC, Watson SL. Clinical Registries in Ophthalmology. *Ophthalmology* 2019;126(5):655-662. DOI: 10.1016/j.ophtha.2018.12.030.
7. Boulanger V, Schlemmer M, Rossov S, Seebald A, Gavin P. Establishing Patient Registries for Rare Diseases: Rationale and Challenges. *Pharmaceut Med* 2020. DOI: 10.1007/s40290-020-00332-1.
8. Broadgate S, Yu J, Downes SM, Halford S. Unravelling the genetics of inherited retinal dystrophies: Past, present and future. *Prog Retin Eye Res* 2017;59:53-96. DOI: 10.1016/j.preteyeres.2017.03.003.
9. Sharon D, Ben-Yosef T, Goldenberg-Cohen N, et al. A nationwide genetic analysis of inherited retinal diseases in Israel as assessed by the Israeli inherited retinal disease consortium (IIRDC). *Hum Mutat* 2020;41(1):140-149. DOI: 10.1002/humu.23903.
10. Gao FJ, Li JK, Chen H, et al. Genetic and clinical findings in a large cohort of Chinese patients with suspected retinitis pigmentosa. *Ophthalmology* 2019. DOI: 10.1016/j.ophtha.2019.04.038.
11. Holtan JP, Selmer KK, Heimdal KR, Bragadottir R. Inherited retinal disease in Norway - a characterization of current clinical and genetic knowledge. *Acta Ophthalmol* 2020;98(3):286-295. DOI: 10.1111/aos.14218.
12. Haer-Wigman L, van Zelst-Stams WA, Pfundt R, et al. Diagnostic exome sequencing in 266 Dutch patients with visual impairment. *Eur J Hum Genet* 2017;25(5):591-599. DOI: 10.1038/ejhg.2017.9.
13. Patel N, Alkuraya H, Alzahrani SS, et al. Mutations in known disease genes account for the majority of autosomal recessive retinal dystrophies. *Clin Genet* 2018;94(6):554-563. DOI: 10.1111/cge.13426.



14. Kim MS, Joo K, Seong MW, et al. Genetic Mutation Profiles in Korean Patients with Inherited Retinal Diseases. *J Korean Med Sci* 2019;34(21):e161. DOI: 10.3346/jkms.2019.34.e161.
15. Motta FL, Martin RP, Filippelli-Silva R, Salles MV, Sallum JMF. Relative frequency of inherited retinal dystrophies in Brazil. *Sci Rep* 2018;8(1):15939. DOI: 10.1038/s41598-018-34380-0.
16. Stone EM, Andorf JL, Whitmore SS, et al. Clinically Focused Molecular Investigation of 1000 Consecutive Families with Inherited Retinal Disease. *Ophthalmology* 2017;124(9):1314-1331. DOI: 10.1016/j.ophtha.2017.04.008.
17. Sergouniotis PI, Maxime E, Leroux D, et al. An ontological foundation for ocular phenotypes and rare eye diseases. *Orphanet J Rare Dis* 2019;14(1):8. DOI: 10.1186/s13023-018-0980-6.
18. Wilkinson MD, Dumontier M, Aalbersberg IJ, et al. The FAIR Guiding Principles for scientific data management and stewardship. *Sci Data* 2016;3:160018. DOI: 10.1038/sdata.2016.18.
19. Bellgard MI, Render L, Radochonski M, Hunter A. Second generation registry framework. *Source Code Biol Med* 2014;9:14. DOI: 10.1186/1751-0473-9-14.
20. Kodra Y, Posada de la Paz M, Coi A, et al. Data Quality in Rare Diseases Registries. *Adv Exp Med Biol* 2017;1031:149-164. DOI: 10.1007/978-3-319-67144-4\_8.
21. Sernadela P, Gonzalez-Castro L, Carta C, et al. Linked Registries: Connecting Rare Diseases Patient Registries through a Semantic Web Layer. *Biomed Res Int* 2017;2017:8327980. DOI: 10.1155/2017/8327980.
22. Read-Brown S, Hribar MR, Reznick LG, et al. Time Requirements for Electronic Health Record Use in an Academic Ophthalmology Center. *JAMA Ophthalmol* 2017;135(11):1250-1257. DOI: 10.1001/jamaophthalmol.2017.4187.
23. Sinsky C, Colligan L, Li L, et al. Allocation of Physician Time in Ambulatory Practice: A Time and Motion Study in 4 Specialties. *Ann Intern Med* 2016;165(11):753-760. DOI: 10.7326/M16-0961.



Manuscript 4

**2.4. Challenges, facilitators and barriers to the adoption and use of a web-based national IRD registry: lessons learned from the IRD-PT registry**

João Pedro Marques

Sara Vaz-Pereira

José Costa

Ana Marta

José Henriques

Rufino Silva

*Published in: Orphanet J Rare Dis. 2022 Aug 26;17(1):323.*

## **ABSTRACT**

Rare disease registries increase research accessibility for patients, while providing clinicians/investigators with a coherent data ecosystem necessary to boost research and patient care. The IRD-PT registry is a national, web-based, interoperable registry for inherited retinal degenerations (IRDs) designed to generate scientific knowledge and collect high-quality data on the epidemiology, genomic landscape and natural history of IRDs in Portugal. In two years, the number of enrolled patients almost doubled (537 to 1060). Still, the registry has a lower-than-expected adoption rate, with only 4 centers across Portugal actively enrolling patients. This highlights a strong need to understand factors that may be hindering the registry's nationwide adoption. The purpose of this manuscript is to analyze challenges, facilitators and barriers to the adoption and use of the IRD-PT registry, and to discuss avenues for improvement, focusing on keeping the registry sustainable in the long run. We believe that this exercise may help other rare disease registries to improve user adherence and engagement, ultimately contributing to develop more sustainable and successful registries in the field.

## **Background**

The development of multicenter patient registries promotes the generation of scientific knowledge by using real-world data. Whilst rare diseases gain visibility as a public health priority and the marketplace expands, acknowledgement of the importance of building collaborative relationships in rare disease research increases.<sup>1</sup> Having data stored in a registry will reflect local workloads and burdens of disease, so as to support facilities' needs for appropriate allocation of human and infrastructure resources. Rare disease registries increase research accessibility for patients, while providing clinicians/investigators with a coherent data ecosystem necessary to boost research and patient care. Inherited retinal dystrophies/degenerations (IRDs) are a clinically and genetically heterogeneous group of diseases with an estimated prevalence of 1 in 3,000 individuals.<sup>2</sup> Despite some common ground, genetic profiles vary considerably among regions and ethnic groups, thus highlighting the importance of obtaining reference population-based data. The IRD-PT registry<sup>3</sup> is a national, web-based, interoperable registry for IRDs designed to generate scientific knowledge and collect high-quality data on the epidemiology, genomic landscape and natural history of IRDs in Portugal. The IRD-PT pre-launched in mid-2019 at *Centro Hospitalar Universitário de Coimbra (CHUC)*, the only Portuguese health care provider (HCP) that integrates the European Reference Network for Rare Eye Diseases (ERN-EYE) and the largest IRD reference center in Portugal. Testing the registry in a pilot center before its national debut aimed to identify possible problems during data completion, test the time spent in data entry, and detect information gaps or system inaccuracies. The registry proved fully functional and easy to use. As of April 30<sup>th</sup> 2022, data from 1049 IRD patients is now included in the registry, approximately twice the number of patients enrolled in April 2020 (n=537).<sup>3</sup> Considering the Portuguese population (~10 million inhabitants), this number corresponds to roughly 1/3 of the total estimated cases of IRDs in Portugal. Other than CHUC (n=890 patients included), 3 centers are actively enrolling patients in the registry: *Centro Hospitalar Universitário Lisboa Norte (CHULN)*, n=58 patients included), *Hospital de Braga (HB)*, n=58 patients included) and *Centro Hospitalar Universitário do Porto (CHUP)*, n=54 patients included). While the numbers are satisfactory, the registry has a lower-than-expected adoption rate.

Based on user feedback and peer-to-peer discussion, we decided to conduct a critical analysis to understand factors that may be hindering the registry's nationwide adoption. Thus, the purpose of this manuscript is to analyze challenges, facilitators and barriers to the adoption and use of the IRD-PT registry, and to discuss avenues for improvement, focusing on keeping the registry sustainable in the long run.

## **Challenges, facilitators and barriers**

In a rapidly evolving field such as IRDs, there is an urge to improve quality of care to conform to standards. An IRD patient registry helps align IRD specialists from different departments and facilities towards one uniform format of data recording. Yet, there are challenges to embrace and barriers to overcome when adopting a registry. Recognizing and understanding the nature of such challenges and barriers is imperative to be well equipped to devise strategies to overcome them.

Lack of time is probably the most significant hindrance to the adoption and use of a registry. Ophthalmologists have limited time with patients during office visits, and electronic health record (EHR) use requires a substantial portion of that time, therefore affecting productivity.<sup>4,5</sup> To promote acceptance and use, registries must be able to adequately interface with other IT systems and exchange information.<sup>6</sup> Unfortunately, there are several EHR vendors operating in Portugal, each with different data capturing systems. Due to the lack of structure and standardization of EHR data, most registries still operate in a mixed data collection environment with continued dependence on manual data entry through clinical chart abstraction.<sup>7</sup> Thus, improvement in semantic interoperability between registries and source data systems is highly needed. The IRD-PT registry<sup>3</sup> allows EHR third-party applications with structured information to deliver their data directly to specific subfields of the registry, thus enabling a quick fill-in process and promoting workplace efficiency. Additionally, by adopting a minimum mandatory data set, the IRD-PT registry<sup>3</sup> helps reduce the proportion of missing data on a patient file and improve the care process by providing guidance and prompt on necessary elements of the clinical history. Still, the balance between record completeness and user burden is not easy to achieve. On the one hand, end-user engagement increases when mandatory data is kept to a minimum. On the other hand, this means that there might be incomplete information/missing data for some enrolled subjects regarding unanswered, non-mandatory fields. We are currently testing data mining from EHR as a strategy to decrease the dependence on manual data entry.

Individual attitudes and beliefs have been reported to act as both facilitators and barriers to implementation and acceptance of e-health systems across all e-health domains.<sup>6</sup> Interest in technology, perceived usefulness and motivation are positive attitudes associated with increased acceptance and implementation. Conversely, general resistance to change, distrust in the system, concerns over patient privacy and security being compromised, or doubts that the registry can actually improve patient care, clinical outcomes or quality of practice act as barriers. Many healthcare professionals believe e-health systems disrupt workflows and the delivery of care.<sup>8</sup> A change of mindset is needed at the practice level in order for clinicians to gain value from their registry participation.<sup>7</sup> Demographic factors such as age, education, sex, nationality, and clinical experience may also influence healthcare professionals' attitudes towards e-health systems.<sup>9</sup>

Interestingly, all doctors actively enrolling patients in the IRD-PT registry<sup>3</sup> are  $\leq 40$  years old. As millennials, their generation is marked by elevated usage of and familiarity with the internet, mobile devices, and social media. Higher technological literacy is likely to potentiate quicker adoption and engagement. Financial incentives may be used as strategies to overcome resistance and stimulate participation.<sup>6</sup> These include financial sponsorship (e.g.: society membership fee reduction or congress fee reduction for adopters), reimbursements for adoption, and pay-for-performance initiatives. Although we believe these interventions may make data introduction more appealing for some users at first, we are not convinced that this is sustainable in the long run. Alternatively, we are working on the integration of the IRD-PT registry<sup>3</sup> with other IRD international registries [Rare Eye Disease Registry (REDgistry) from the ERN-EYE and Fight Inherited Retinal Blindness (FIRB!) registry from the Save Sight Registries project], aiming to motivate users by the possibility to have their name featured in relevant publications or easing access to clinical trials. Interoperability has always been a key issue during the development of the IRD-PT registry<sup>3</sup>. All diagnoses are coded according to the International Statistical Classification of Diseases and Related Health Problems (ICD) 9, 10, 11, and Orphanet Rare Disease Ontology (ORPHA) numbers. Furthermore, genes are coded according to the Ontology of Genes and Genomes (OGG) and Mendelian Inheritance in Man (MIM), and patient signs and symptoms are coded according to the Human Phenotype Ontology (HPO). By resorting to common data elements, core outcome sets, and standardized data structures, the IRD-PT can support the exchange of data across datasets, facilitating its connection to other registries at an international level.

Appropriate, high-quality, and easily available training is a facilitator to the implementation of a registry, whereas it can be considered a barrier when it is non-existent or existent but inadequate.<sup>6,10</sup> With this in mind, we recently developed short *how-to* videos aiming to explain basic functions of the registry such as: creation of a new patient, retrospective data introduction, new clinic or treatment visit, or data analysis. These videos were made available at the Portuguese Society of Ophthalmology website for all members to access. Additionally, the registry has been advertised in national congresses and meetings and a manuscript detailing its design, development and deployment was published in an open access journal.<sup>3</sup>

Complexity factors such as slow system performance, data handling, reliability, unplanned downtime and connectivity issues negatively influence the adoption and use of systems in healthcare settings.<sup>6</sup> Fortunately, this is not the case with the IRD-PT registry.<sup>3</sup> End-users were involved in its design and development, thus selecting IRD specific information for a smooth data capture. Additionally, the platform is user-friendly, web-based (thus available anywhere, including mobile platforms), and is managed by an IT team that provides end-user technical support around the clock.

Blumenthal<sup>7</sup> identified cost as the most significant barrier to the long-term sustainability of clinical registries. As part of the *retina.pt* platform (<https://www.retina.com.pt>), developed by the Portuguese Retina Study Group (GER, [www.ger-portugal.com](http://www.ger-portugal.com)), the registry receives annual funding from industry stakeholders (Novartis®, Bayer®, Allergan® and Alimera®), making its use available to all members of the Portuguese Society of Ophthalmology at no extra cost. Funding is used for data management activities, IT support, layout improvements and legal support. However, these companies have no proprietary interest in the generated data.

### ***Avenues for improvement***

Despite the high number of enrolled patients, only 4 centers across Portugal have adopted and are currently using the registry. Lack of time, individual attitudes and beliefs and low technological literacy are the most significant challenges and barriers to a nationwide embracement of the registry. Our approach for the future involves making data capture easier and less time-consuming for the users with the development of additional training materials like the how-to videos and the implementation of data mining from EHR to decrease dependence on manual data entry. Additionally, we aim to make the adoption and use of the registry more appealing with the integration in other international IRD registries, and the publication of multicenter studies with data from the registry. We hope that combining these strategies with the existing strengths of the IRD-PT (user-friendly interface, minimum mandatory data set, web-based format, around the clock IT support, and robust funding to ensure long-term sustainability) will attract and fixate new users.

In conclusion, we provide insight into factors whose interplay may lead to improved end-user adoption and engagement in a national IRD patient registry. Sustainability in the long run can only be met by fostering a culture of communication and cooperation between users and adopting realistic strategies to overcome challenges and barriers. We believe the implementation of the above mentioned strategies will make the IRD-PT more functional, pervasive and sustainable. Additionally, we hope that this exercise may help other rare disease registries to improve user adherence and engagement, ultimately contributing to develop more sustainable and successful registries in the field.



## REFERENCES

1. Boulanger V, Schlemmer M, Rossov S, Seebald A, Gavin P. Establishing Patient Registries for Rare Diseases: Rationale and Challenges. *Pharmaceut Med* 2020. DOI: 10.1007/s40290-020-00332-1.
2. Broadgate S, Yu J, Downes SM, Halford S. Unravelling the genetics of inherited retinal dystrophies: Past, present and future. *Prog Retin Eye Res* 2017;59:53-96. DOI: 10.1016/j.preteyeres.2017.03.003.
3. Marques JP, Carvalho AL, Henriques J, Murta JN, Saraiva J, Silva R. Design, development and deployment of a web-based interoperable registry for inherited retinal dystrophies in Portugal: the IRD-PT. *Orphanet J Rare Dis* 2020;15(1):304. DOI: 10.1186/s13023-020-01591-6.
4. Read-Brown S, Hribar MR, Reznick LG, et al. Time Requirements for Electronic Health Record Use in an Academic Ophthalmology Center. *JAMA Ophthalmol* 2017;135(11):1250-1257. DOI: 10.1001/jamaophthalmol.2017.4187.
5. Sinsky C, Colligan L, Li L, et al. Allocation of Physician Time in Ambulatory Practice: A Time and Motion Study in 4 Specialties. *Ann Intern Med* 2016;165(11):753-760. DOI: 10.7326/M16-0961.
6. Ross J, Stevenson F, Lau R, Murray E. Factors that influence the implementation of e-health: a systematic review of systematic reviews (an update). *Implement Sci* 2016;11(1):146. DOI: 10.1186/s13012-016-0510-7.
7. Blumenthal S. The Use of Clinical Registries in the United States: A Landscape Survey. *EGEMS (Wash DC)* 2017;5(1):26. DOI: 10.5334/egems.248.
8. Gagnon MP, Desmartis M, Labrecque M, et al. Systematic review of factors influencing the adoption of information and communication technologies by healthcare professionals. *J Med Syst* 2012;36(1):241-77. DOI: 10.1007/s10916-010-9473-4.
9. Yarbrough AK, Smith TB. Technology acceptance among physicians: a new take on TAM. *Med Care Res Rev* 2007;64(6):650-72. DOI: 10.1177/1077558707305942.
10. Boonstra A, Broekhuis M. Barriers to the acceptance of electronic medical records by physicians from systematic review to taxonomy and interventions. *BMC Health Serv Res* 2010;10:231. DOI: 10.1186/1472-6963-10-231.



Manuscript 5

**2.5. Instagram as a vehicle to promote disease awareness and medical education in  
#retinaldystrophies**

João Pedro Marques

*Published in: Postgrad Med J. 2022 May;98(e3):e167.*

Inherited retinal dystrophies/degenerations (IRDs) are a clinically and genetically heterogeneous group of rare eye diseases. Despite their low prevalence (~1:3000 individuals), IRDs are an important cause of severe visual impairment and blindness in children and young adults. Remarkable progress in understanding the genetics of IRDs resulted in the identification of roughly 300 disease-causing genes (<https://sph.uth.edu/retnet/>). However, this wealth of information is only slowly being translated into genetic diagnoses for individual patients, as significant barriers to testing still exist all over the world. Recently, the subretinal administration of voretigene neparvovec has been approved by the Food and Drug Administration (FDA) and the European Medicines Agency (EMA) as a one-time gene augmentation therapy to treat *RPE65*-associated retinal degeneration. Improved light sensitivity, visual field, and navigational ability under dim lighting conditions were reported, with preservation of the clinically meaningful effect for at least 4 years.<sup>1</sup> Not only has this new treatment changed lives of individuals previously destined to live a life of blindness, but it has fueled interest in developing additional gene therapy reagents targeting other genetic forms of inherited retinal disease.<sup>2</sup> Nevertheless, IRDs remain largely unknown among decision/policy-makers, the general public, medical students, clinicians, and other healthcare workers. Early recognition of clinical clues/red flags like abnormal visual behavior and nystagmus in preverbal children; or low vision, constricted visual fields, nyctalopia and photophobia in children, adolescents or young adults is crucial for a timely referral to an IRD expert center where patients can be adequately diagnosed, genotyped and ultimately treated. Obtaining a genetic diagnosis for every IRD patient is a vital goal for moving the field forward and the single most important factor for gaining access to an approved treatment or clinical trial based on gene therapy. It is of the utmost importance to fight the dis- and/or misinformation that exists towards IRDs so that patients can be granted full clinical, familial, and socioeconomic support.

Medical education has grown beyond the boundaries of the classroom. The explosive rise of social media platforms revolutionized the learning experience, creating different ways of sharing knowledge and making it readily and widely available. Nowadays, academic departments, medical associations, and medical journals use social media to broadcast research advances, increase visibility and engage with a global audience. Since its 2010 debut, Instagram (San Francisco, CA, USA) has become one of the most popular mobile social media channels, with more than one billion monthly registered active users and high levels of user engagement.<sup>3</sup> Instagram rapidly gained popularity among medical students,<sup>4,5</sup> and is currently used as a vehicle for delivering educational content across diverse fields of medicine,<sup>3</sup> including ophthalmology.<sup>6,7</sup> As a medical specialty that relies heavily on imaging, the primary photo-oriented concept of Instagram is a well-fit for ophthalmology. In the particular field of IRDs, the visually captivating nature of multimodal imaging features make image-based communication highly effective, offering

unlimited potential to engage with the target audience. Despite the online presence of several outstanding Instagram accounts dedicated to retina education,<sup>6</sup> there was none exclusively devoted to IRDs. In July 2019 I started the @retinaldystrophies Instagram account (<https://www.instagram.com/retinaldystrophies>) to fill this gap, aiming to raise awareness and create an educational platform specific for IRDs. The content is original and consists of de-identified cases with a brief explanation of the disease and the genetics behind it. Nineteen months after its launch and 72 posts later, the @retinaldystrophies Instagram account has a broad and diverse global audience with more than 5750 followers. The most represented countries are Brazil (18%), the United States of America (12.8%), India (6.4%), Turkey (4.2%) and Mexico (3.8%). The follower breakdown shows a similar number of male and female followers (51.7% vs 48.3%, respectively) and a predominantly young audience: 85.1% are between 25 and 44 years old (63.3% between 25 and 34 and 21.8% between 24 and 44 years of age).

Despite the benefits of free and easily accessible learning content, the reliability of educational material shared through social media should always be analyzed carefully to avoid misinformation. Since content is not moderated, users should exercise caution when interpreting posts and should continue to follow guidelines from trusted sources. Social media learning platforms must still be regarded as a complement to conventional teaching methods and do not replace clinical experience and peer to peer teaching offered during medical school, residency and fellowship training.

In conclusion, social media channels offer an avenue to engage with audiences in an unprecedented manner, allowing for communication and education on a larger and more rapid scale than traditional print methods.<sup>7</sup> Taking advantage of its popularity and high levels of user engagement, Instagram can be effectively used to promote disease awareness and medical education in IRDs, hopefully allowing more patients to be appropriately diagnosed, genotyped and ultimately treated.

## REFERENCES

1. Maguire AM, Russell S, Wellman JA, et al. Efficacy, Safety, and Durability of Voretigene Neparvovec-rzyl in RPE65 Mutation-Associated Inherited Retinal Dystrophy: Results of Phase 1 and 3 Trials. *Ophthalmology* 2019;126(9):1273-1285. DOI: 10.1016/j.opht.2019.06.017.

2. Maguire AM, Bennett J, Aleman EM, Leroy BP, Aleman TS. Clinical Perspective: Treating RPE65-Associated Retinal Dystrophy. *Mol Ther* 2020 (Epub ahead of print). DOI: 10.1016/j.ymthe.2020.11.029.
3. Kauffman L, Weisberg EM, Eng J, Fishman EK. Is a Picture Really Worth More than a Thousand Words? Which Instagram Post Types Elicit the Best Response for Radiology Education. *J Digit Imaging* 2020;33(4):1053-1057. DOI: 10.1007/s10278-020-00344-y.
4. Thomas RB, Johnson PT, Fishman EK. Social Media for Global Education: Pearls and Pitfalls of Using Facebook, Twitter, and Instagram. *J Am Coll Radiol* 2018;15(10):1513-1516. DOI: 10.1016/j.jacr.2018.01.039.
5. El Bialy S, Jalali A. Go Where the Students Are: A Comparison of the Use of Social Networking Sites Between Medical Students and Medical Educators. *JMIR Med Educ* 2015;1(2):e7. DOI: 10.2196/mededu.4908.
6. Leitao Guerra RL. A perspective on retina education through social media. *Int J Retina Vitreous* 2020;6:44. DOI: 10.1186/s40942-020-00244-x.
7. Tsui E, Rao RC. Navigating Social Media in #Ophthalmology. *Ophthalmology* 2019;126(6):779-782. DOI: 10.1016/j.ophtha.2019.02.015.

Manuscript 6

**2.6. Treating the first Portuguese patient with Luxturna: A small step for world science, a giant leap for Portuguese Ophthalmology**

João Pedro Marques

Miguel Raimundo

Catarina Paiva

João Figueira

Mário Alfaiate

Rufino Silva

Joaquim Murta

*Published in: Revista Sociedade Portuguesa de Oftalmologia 2021;45(2):67-69.*

After a bumpy start with decades of disputed results and treatment failures, the first ever gene therapy drug (Gendicine®), a recombinant adenovirus engineered to express wildtype-p53) was approved by the China Food and Drug Administration in 2003 to treat head and neck cancer.<sup>1</sup> However, it was not until 2015 that the U.S. Food and Drug Administration (FDA) approved one of these medicines – talimogene laherparepvec (T-VEC, or Imlygic®), the first oncolytic virus therapy for patients with metastatic melanoma that cannot be surgically removed. In 2017, tisagenlecleucel (Kymriah®) was granted FDA approval for the treatment of B-cell lymphoblastic leukemia. Later that year, voretigene neparvovec (Luxturna®) became the first gene therapy for inherited blindness to receive FDA approval. This was a significant milestone for ophthalmology in particular and modern medicine in general, as Luxturna was also the first *in vivo* gene therapy ever approved. Treatment is directed at RPE65-associated retinal degeneration, a severe form of inherited retinal blindness. Gene augmentation therapy delivers a normal copy of the native human RPE65 cDNA to the diseased retinal pigment epithelium (RPE) cells after subretinal injection of a recombinant adeno-associated virus (AAV).<sup>2</sup> Improved light sensitivity, visual field, and navigational ability under dim lighting conditions were reported, with preservation of the clinically meaningful effect for at least 4 years.<sup>3</sup> In November 2018, the European Medicines Agency (EMA) granted Novartis AG marketing authorization for the use of Luxturna in Europe, but the high cost and country-specific regulations hampered its widespread use. After cost-effectiveness for the national healthcare systems was reviewed,<sup>4-7</sup> several countries around the world started treating patients.

The RPE65 gene is expressed in the RPE and plays a key role in the retinoid cycle as it encodes retinoid isomerohydrolase, an enzyme that regenerates *11-cis* retinal.<sup>8</sup> Biallelic loss-of-function mutations in the RPE65 gene result in either a lack of RPE65 protein or protein that is non-functional. Without this important protein, phototransduction in photoreceptor cells is impaired, resulting in severe photoreceptor degeneration and ultimately death.<sup>2</sup> Like many inherited retinal dystrophies/degenerations (IRDs), RPE65 mutation-associated retinal degeneration can be heterogenous, with a phenotypic continuum modulated by disease severity. Severe visual impairment or blindness is usually present from birth or in early childhood, a clinical presentation that falls within the Leber congenital amaurosis (LCA)/early-onset retinal degeneration (EORD) spectrum. Although the true prevalence of RPE65-associated disease is unknown, estimates point towards an overall prevalence of 1 per 300,000 individuals.<sup>9-11</sup> RPE65 is believed to account for 5-6% of LCA cases and 2-5% of autosomal recessive retinitis pigmentosa cases. In Portugal, for a population of approximately 10 million, estimates anticipate an overall number of between 33 and 67 RPE65 mutation-associated IRD patients, which is considerably higher than what was reported in a recent multinational survey by the European Vision Institute Clinical Research Network (EVICR.net).<sup>9</sup> Two possible explanations are 1)



patients who are currently followed at centers that are not members of the EVICR.net consortium and/or 2) patients that remain unidentified because genetic testing is not routinely performed (or available) in all Portuguese centers. Nevertheless, since most patients are blind by the end of the third or fourth decade,<sup>12,13</sup> the number of individuals who might benefit from gene therapy with voretigene neparvovec in Portugal is probably much lower. Given the degenerative nature of *RPE65*-associated disease, a window of opportunity for gene therapy exists and gene therapy candidates must be identified as early as possible. Early diagnosis and rapid referral of these patients to specialized centers cannot be overemphasized as *time is vision*.

May 2021 will be forever remembered as the date of the first gene therapy treatment of a Portuguese patient with inherited retinal blindness. In a small country like Portugal, being able to treat patients with this innovative therapy is a milestone that should make all ophthalmologists proud. Currently, *Centro Hospitalar e Universitário de Coimbra* (CHUC) is the only Portuguese Luxturna treatment center. Patient referral pathways are in place so that no patient is left behind.

Despite remarkable advances witnessed in the field, complex challenges remain. IRDs are still largely unknown among decision-makers, policy-makers, the general public, clinicians and other healthcare workers.<sup>14</sup> Even among ophthalmologists, it is crucial to raise awareness and fight the dis- and/or misinformation that exists towards IRDs so that patients can be granted full clinical, familial and socioeconomic support. Furthermore, obtaining a genetic diagnosis for every IRD patient is a vital step in moving the field forward and the single most important factor for gaining access to an approved treatment or gene therapy-based clinical trial.<sup>15</sup> To improve care for IRD patients in Portugal, we need to urgently address four pivotal unmet needs<sup>14</sup>: 1) improve disease awareness and education; 2) provide equitable access to genetic testing and genetic counselling; 3) establish referral pathways and minimize time to diagnosis; and 4) join forces to have all patients included in the IRD-PT registry.<sup>16</sup>

In conclusion, inherited retinal blindness was deemed incurable for a long time. Luxturna has changed the lives of individuals previously destined to live a life of blindness, but most importantly, it has fueled interest in developing additional gene therapy reagents targeting other genetic forms of inherited retinal disease. The field is currently in an exciting phase of expanding possibilities and the future has never looked brighter.

## REFERENCES

1. Zhang WW, Li L, Li D, et al. The First Approved Gene Therapy Product for Cancer Ad-p53 (Gendicine): 12 Years in the Clinic. *Hum Gene Ther* 2018;29(2):160-179. DOI: 10.1089/hum.2017.218.
2. Maguire AM, Bennett J, Aleman EM, Leroy BP, Aleman TS. Clinical Perspective: Treating RPE65-Associated Retinal Dystrophy. *Mol Ther* 2020 (Epub ahead of print). DOI: 10.1016/j.ymthe.2020.11.029.
3. Maguire AM, Russell S, Wellman JA, et al. Efficacy, Safety, and Durability of Voretigene Neparvovec-rzyl in RPE65 Mutation-Associated Inherited Retinal Dystrophy: Results of Phase 1 and 3 Trials. *Ophthalmology* 2019;126(9):1273-1285. DOI: 10.1016/j.ophtha.2019.06.017.
4. Johnson S, Buessing M, O'Connell T, Pitluck S, Ciulla TA. Cost-effectiveness of Voretigene Neparvovec-rzyl vs Standard Care for RPE65-Mediated Inherited Retinal Disease. *JAMA Ophthalmol* 2019. DOI: 10.1001/jamaophthalmol.2019.2512.
5. Uhrmann MF, Lorenz B, Gissel C. Cost Effectiveness of Voretigene Neparvovec for RPE65-Mediated Inherited Retinal Degeneration in Germany. *Transl Vis Sci Technol* 2020;9(9):17. DOI: 10.1167/tvst.9.9.17.
6. Viriato D, Bennett N, Sidhu R, et al. An Economic Evaluation of Voretigene Neparvovec for the Treatment of Biallelic RPE65-Mediated Inherited Retinal Dystrophies in the UK. *Adv Ther* 2020;37(3):1233-1247. DOI: 10.1007/s12325-020-01243-y.
7. Zimmermann M, Lubinga SJ, Banken R, et al. Cost Utility of Voretigene Neparvovec for Biallelic RPE65-Mediated Inherited Retinal Disease. *Value Health* 2019;22(2):161-167. DOI: 10.1016/j.jval.2018.09.2841.
8. Redmond TM, Yu S, Lee E, et al. Rpe65 is necessary for production of 11-cis-vitamin A in the retinal visual cycle. *Nat Genet* 1998;20(4):344-51. DOI: 10.1038/3813.
9. Lorenz B, Tavares J, van den Born LI, Marques JP, Scholl HPN, Group EVn. Current management of patients with RPE65 mutation-associated inherited retinal degenerations (IRDs) in Europe. Results of a multinational survey by the European Vision Institute Clinical Research Network EVICR.net. *Ophthalmic Res* 2021. DOI: 10.1159/000515688.
10. Galvin O, Chi G, Brady L, et al. The Impact of Inherited Retinal Diseases in the Republic of Ireland (ROI) and the United Kingdom (UK) from a Cost-of-Illness Perspective. *Clin Ophthalmol* 2020;14:707-719. DOI: 10.2147/OPHTH.S241928.
11. Pontikos N, Arno G, Jurkute N, et al. Genetic Basis of Inherited Retinal Disease in a Molecularly Characterized Cohort of More Than 3000 Families from the United Kingdom. *Ophthalmology* 2020;127(10):1384-1394. DOI: 10.1016/j.ophtha.2020.04.008.

12. Chung DC, Bertelsen M, Lorenz B, et al. The Natural History of Inherited Retinal Dystrophy Due to Biallelic Mutations in the RPE65 Gene. *Am J Ophthalmol* 2019;199:58-70. DOI: 10.1016/j.ajo.2018.09.024.
13. Pierrache LHM, Ghafaryasl B, Khan MI, et al. Longitudinal Study of Rpe65-Associated Inherited Retinal Degenerations. *Retina* 2020;40(9):1812-1828. DOI: 10.1097/IAE.0000000000002681.
14. Marques JP, Pires J, Costa J, Murta J, Silva R. Inherited Retinal Degenerations in Portugal: Addressing the Unmet Needs. *Acta Med Port* 2021. DOI: 10.20344/amp.15802.
15. Thompson DA, Ali RR, Banin E, et al. Advancing therapeutic strategies for inherited retinal degeneration: recommendations from the Monaciano Symposium. *Invest Ophthalmol Vis Sci* 2015;56(2):918-31. DOI: 10.1167/iovs.14-16049.
16. Marques JP, Carvalho AL, Henriques J, Murta JN, Saraiva J, Silva R. Design, development and deployment of a web-based interoperable registry for inherited retinal dystrophies in Portugal: the IRD-PT. *Orphanet J Rare Dis* 2020;15(1):304. DOI: 10.1186/s13023-020-01591-6.



## **CHAPTER 3: CLINICAL AND MOLECULAR STUDIES**



Manuscript 7

**3.1. Clinical/demographic, functional testing and multimodal imaging differences between genetically solved and unsolved Retinitis Pigmentosa**

João Pedro Marques

Ana Marta

Ana Luísa Carvalho

Pedro Menéres

Joaquim Murta

Jorge Saraiva

Rufino Silva

*Published in: Ophthalmologica. 2022;245(2):134-143.*

## **ABSTRACT**

### **Introduction**

The purpose of this study was to compare clinical/demographic, functional testing and multimodal imaging features between genetically solved and genetically unsolved non-syndromic retinitis pigmentosa (nsRP) patients.

### **Methods**

Cross-sectional study conducted at an inherited retinal dystrophies reference center. Consecutive patients with nsRP and available genetic testing results performed between 2018 and 2020 were included. Genetic testing was clinically-oriented and variants were classified according to the American College of Medical Genetics and Genomics. Only class IV or V variants were considered disease-causing. Clinical/demographic, functional and imaging features were compared between genetically unsolved (G1) and genetically solved (G2) patients.

### **Results**

A total of 175 patients (146 families) were included: 68 patients (59 families) in G1 and 107 patients (87 families) in G2. First symptoms <25 years, consanguinity, evidence for a particular inheritance pattern and absence of indicators for phenocopies were significantly more prevalent in G2. No significant differences were observed on best-corrected visual acuity. The visual field index and mean central retinal layer thickness were significantly higher in G1. The frequency of atypical features on multimodal imaging did not differ between groups.

### **Conclusion**

Individual clinical/demographic, functional testing and multimodal imaging features should be considered when counselling patients about the probability of identifying disease-causing variants.



## INTRODUCTION

Retinitis pigmentosa (RP) is the most common inherited retinal degeneration/dystrophy (IRD), with a worldwide prevalence of approximately 1:4000 individuals.<sup>1</sup> Three clinical features — bone spicule hyperpigmentation, attenuation of retinal vessels, and the waxy pallor of the optic nerve — are the hallmark signs of RP.<sup>1,2</sup> These changes are usually bilateral with a high degree of inter-eye symmetry.<sup>3</sup> However, phenotypic variability is common and several atypical RP phenotypes have been described, including unilateral or asymmetric cases.<sup>3-5</sup> One contributing factor is genetic heterogeneity, but the influence of disease modifiers cannot be excluded in face of the variable expressivity observed both between and within families. Despite state-of-the-art genetic testing, a substantial number (30-50%)<sup>6-10</sup> of RP cases remain genetically unsolved. Undetected/unknown genotypes (e.g. inappropriate genetic test selection; hypomorphic variants; variants within non-coding regions or variants in genes that have not yet been associated with RP)<sup>11-13</sup> or an incorrect clinical diagnosis (i.e. disease entities that mimic RP such as paraneoplastic retinopathy, inflammation, infection or autoimmune disease)<sup>14-18</sup> are possible explanations. Additionally, a higher diagnostic yield has been reported in association with a younger age of onset of symptoms, consanguinity, family history/evidence for an inheritance pattern or a typical RP phenotype.<sup>13,19-21</sup> With new therapeutic options and a growing number of gene therapy trials, the importance of deep phenotyping and genetic testing cannot be overemphasized.

The aim of this study was to compare clinical/demographic, functional testing and multimodal imaging features between genetically solved and unsolved non-syndromic RP (nsRP) patients.

## MATERIALS AND METHODS

### *Study Design and Diagnostic Criteria*

Cross-sectional study conducted at the Ophthalmology Unit and Medical Genetics Unit of *Centro Hospitalar e Universitário de Coimbra* (CHUC). The IRD-PT registry<sup>22</sup> was used to identify consecutive patients with ns RP and available genetic testing results. Clinical/demographic, functional and imaging features were compared between genetically unsolved (Group 1) and genetically solved (Group 2) patients. The study was approved by the local Ethics Committee and followed the tenets of the Declaration of Helsinki for biomedical research.

### *Clinical/demographic features*

Age at diagnosis, age of onset of symptoms, consanguinity, family history, evidence for a

particular inheritance pattern, and indicators for phenocopies were collected from the patient file. Age of onset of symptoms was categorized as: first months of life (<12 months); early childhood (1-3 years); childhood (4-12 years); adolescence (13-17 years); early adulthood (18-25 years); adulthood (26-64 years); and elderly (>65 years). We considered evidence for a particular inheritance pattern when family history/pedigree was indicative of autosomal recessive (AR), autosomal dominant (AD) or X-linked (XL) disease. Phenocopies were defined as non-hereditary phenodeviations that may closely mimic RP mutant phenotypes (e.g. post-inflammatory conditions and neoplastic or non-neoplastic autoimmune retinopathy).<sup>13,18</sup>

### ***Ophthalmic Examination, Functional Testing and Multimodal Imaging***

All patients underwent a comprehensive ophthalmologic examination including best-corrected visual acuity (BCVA, ETDRS letters), dilated slit-lamp anterior segment and fundus biomicroscopy performed by a single IRD specialist (JPM). Functional testing and multimodal imaging included: seven standard 45°-field colour fundus photographs (CFP) (Nikon Digital SLR Camera D7000, Nikon Corporation, Japan), ultrawidefield (UWF) fundus and fundus autofluorescence (FAF) imaging (Optos California, Optos GmbH, Germany), spectral-domain optical coherence tomography (SD-OCT, Spectralis, Heidelberg Engineering, Heidelberg, Germany or Avanti RTVue-XR 100, Optovue Inc, Fremont, CA, USA), OCT-Angiography (OCTA, Avanti RTVue-XR 100, Optovue Inc, Fremont, CA, USA), FAF (HRAII, Heidelberg Engineering, Heidelberg, Germany), 24-2 or 10-2 Humphrey visual field (VF) testing (Zeiss 750i, Carl Zeiss, Germany) and electrophysiology testing using the RETIscan system (Roland Consult, Germany) with DTL-Plus electrodes. Prior to genetic testing, a clinical diagnosis of RP was established based on history along with compatible structural and functional retinal changes.

All eyes were classified as typical or atypical based on multimodal imaging features. Typical RP was considered in the setting of an overall bilateral and symmetric presentation, mid-peripheral bone spicule pigmentation affecting all retinal quadrants, narrowed/attenuated vessels, a waxy pallor of the optic nerve head (ONH), a parafoveal hyperAF ring on FAF imaging, and an eccentric thinning (or loss) of the outer retinal layers (with or without thinning of the outer nuclear layer) on SD-OCT.<sup>1,13,23,24</sup> When atypical findings were observed in at least one imaging modality, cases were classified as mildly atypical, while cases with atypical features in 2 or 3 imaging modalities were classified as highly atypical.

Additional features collected from CFP and/or UWF fundus imaging included presence, amount and distribution of bone spicule pigmentation; vessel appearance; ONH pallor and presence of ONH drusen; and presence and location of chorioretinal atrophy. FAF and/or UWF FAF images were analyzed for symmetry; presence/absence, size and shape (regular/concentric or irregular/arc) of the parafoveal ring of hyperAF; presence/absence of ONH drusen; and

presence/absence of central hypoAF (macular atrophy). On SD-OCT, the presence/absence of cystoid macular edema (CME), status of the vitreomacular interface, and status of the outer retinal layers were evaluated. The central retinal layer thickness (RLT), corresponding to the distance from the inner limiting membrane to the *retinal pigment epithelium* (ILM-RPE), and the central retinal inner layer thickness (ILT), *corresponding to the distance from the ILM to the inner plexiform layer* (ILM-IPL), were also evaluated. The pattern observed in the VF was analyzed as “normal”, “isolated scotoma around 20°”, “peripheral upper and/or lower scotoma”, “ring scotoma in the mid periphery”, “small central island” and “almost complete scotoma”. Finally, mean deviation (MD) and visual field index (VFI) values were collected for every subject.

On OCT-A, macular vascular density of superficial capillary plexus (SMVD) was collected.

All images were graded by two independent medical graders (AM and JPM). Disagreement was resolved by open adjudication.

### **Genetic testing**

Genetic testing was clinically-oriented in all probands and coordinated by a medical geneticist from the Medical Genetics Unit of CHUC. A next-generation sequencing (NGS) approach was used, complemented by multiplex ligation-dependent probe amplification (MLPA) and/or sequencing of *RPGR-ORF15* when deemed necessary. Peripheral blood samples were collected from all probands and available relatives for genetic analysis. The genomic DNA was extracted using a genomic DNA extraction and purification kit based on the manufacturer’s protocol. Variants were classified in accordance with the American College of Medical Genetics and Genomics (ACMG).<sup>25</sup> All variants classified as pathogenic (class V) or likely pathogenic (class IV) were further confirmed by Sanger sequencing. Whenever possible, segregation analysis was performed in family members. Published cDNA sequences for the identified genes were compared with the sequencing results. Sanger sequencing and NGS were performed at a certified diagnostic lab (CGC Genetics) with good quality control at the raw data stage, the alignment and the variant calling. The diagnostic yield was calculated from the number of variants classified as pathogenic or likely pathogenic. Genetic counselling provided by a medical geneticist was granted to all subjects.

### **Statistical analysis**

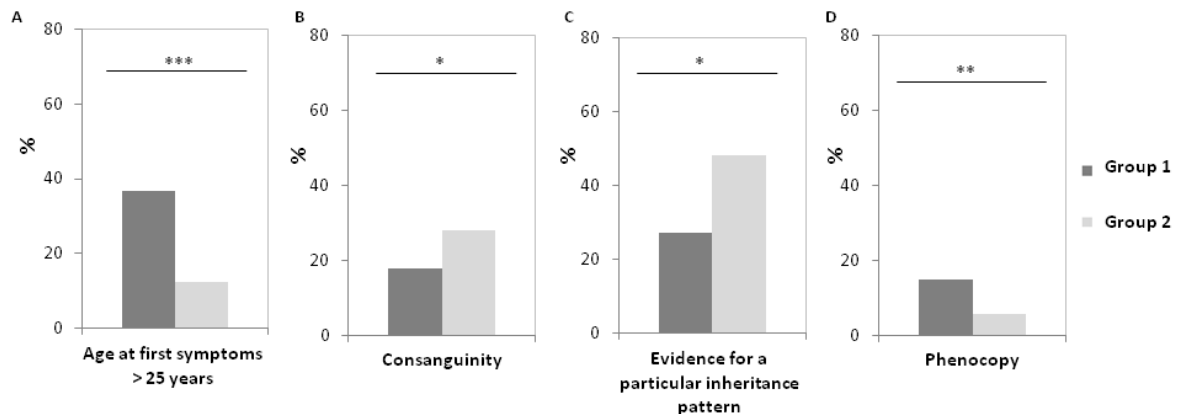
Statistical analysis was performed using the SPSS program (SPSS Statistics, version 22.0 for Windows, SPSS Inc., IBM, Somers, NY). The normality of the variables was evaluated by the Kolmogorov-Smirnov test. The comparison between continuous variables was performed using the T-Student test. The comparison between categorical variables was performed using the chi-

square test. Pearson's and Spearman's bivariate correlation tests were used to studying linear correlations. Binary logistic regression was performed to verify which factors were predictors of solved genetic testing in cases of nsRP. ROC curve was used to find the optimal cut-off values for VFI. P values less than 0.05 were considered statistically significant.

## RESULTS

### Clinical/demographic features

The study included 175 patients (350 eyes) of 146 families: 68 patients (59 families; 136 eyes) in group 1 and 107 patients (87 families; 214 eyes) in group 2. All patients were Portuguese and Caucasian. Twenty-five different genes were identified as the cause of nsRP in group 2. The 6 most prevalent disease-causing genes (72.1% of the families) were *EYS* (31.8%), *RPGR* (17.8%), *CNGBI* (7.5%), *NR2E3* (5.6%), *RPE65* (4.7%) and *IMPG2* (4.7%). There were no gender differences between groups ( $p=0.582$ ). The average age at diagnosis was significantly higher in group 1 ( $43 \pm 17$  vs.  $36 \pm 18$  years,  $p<0.001$ ). Regarding age of onset of symptoms, differences between groups were also statistically significant ( $p<0.001$ ). Age of first symptoms above 25 years was more frequently ( $p<0.001$ ) observed in group 1 (36.1%) than in group 2 (12.5%) (shown in Fig. 1A). On the other hand, childhood onset of symptoms was significantly more frequent ( $p=0.024$ ) in group 2 (44.8%) than in group 1 (36.7%).



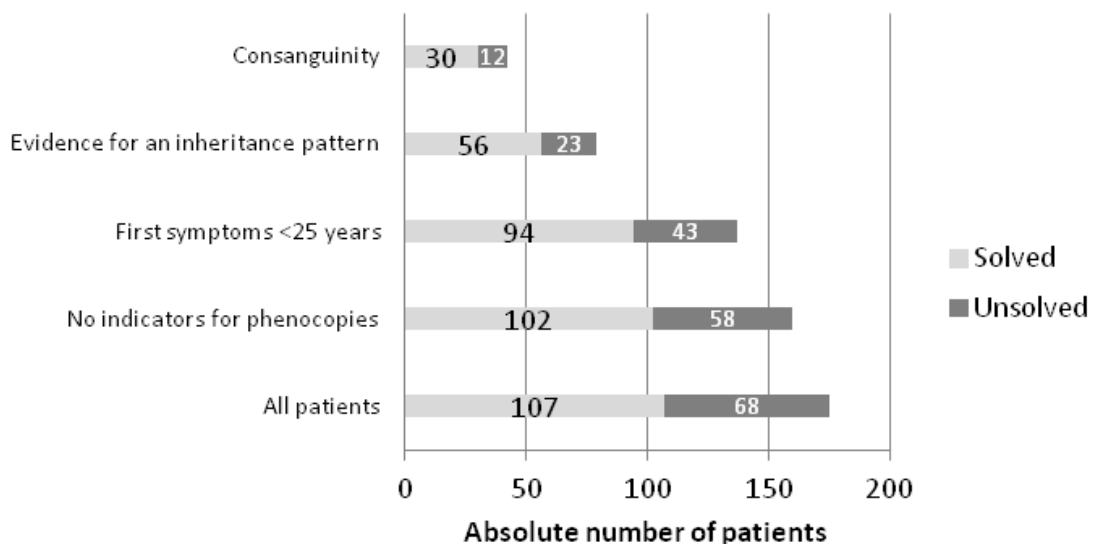
**Figure 1.** Four clinical/demographic parameters significantly differ between genetically unsolved (dark grey) and genetically solved (light grey) patients: age at first symptoms > 25 years (A), consanguinity (B), evidence for a particular inheritance pattern (C) and indicators for phenocopies (D). \* $p<0.05$ ; \*\* $p<0.01$ ; \*\*\* $p<0.001$

Consanguinity was significantly less frequent ( $p=0.019$ ) in group 1 (17.9%) than in group 2 (28.0%) (shown in Fig. 1B). Family history of RP was present in 48.5% and 57.0% in groups 1 and 2, respectively ( $p=0.149$ ).

Evidence for a particular inheritance pattern was more prevalent in group 2 than in group 1 ( $p=0.044$ ) (shown in Fig. 1C). In group 1, a pedigree suggesting a particular mode of inheritance was present in 16 (27.1%) families (7 AD, 7 AR and 2 XL), while in group 2 such characteristics were present in 42 (48.3%) families (6 AD, 27 AR, and 9 XL). After genetic testing, an AD disease-causing gene was found in 6 families, an AR disease-causing gene was found in 72 families and an XL disease-causing gene was found in 9 families in group 2.

The potential for phenocopies was significantly more prevalent in group 1 than 2 ( $p=0.007$ ) (shown in Fig. 1D). In group 1, 10 patients (14.7%) had a relevant personal history: 8 with autoimmune disease and 2 with neoplastic disease. In group 2, the potential for phenocopies was identified in 5 patients (5.6%): 3 with autoimmune thyroid disease, 1 with uveal melanoma, and 1 with systemic sclerosis.

The onset of symptoms in childhood ( $OR=1.650$ ;  $IC\ 95\%=1.021-2.665$ ), history of consanguinity in the family ( $OR=1.821$ ;  $IC\ 95\%=1.040-3.191$ ) and absence of potential for phenocopies ( $OR=2.689$ ;  $IC\ 95\%=1.215-5.951$ ) were predictors of a solved case in our nsRP cohort ( $\chi^2(1)=16.101$ ;  $p=0.001$ ,  $R^2_{Negekerke}=0.064$ ). A set of baseline clinical/demographic parameters may prove useful in determining those probands with a higher pre-test probability (Figure 2).

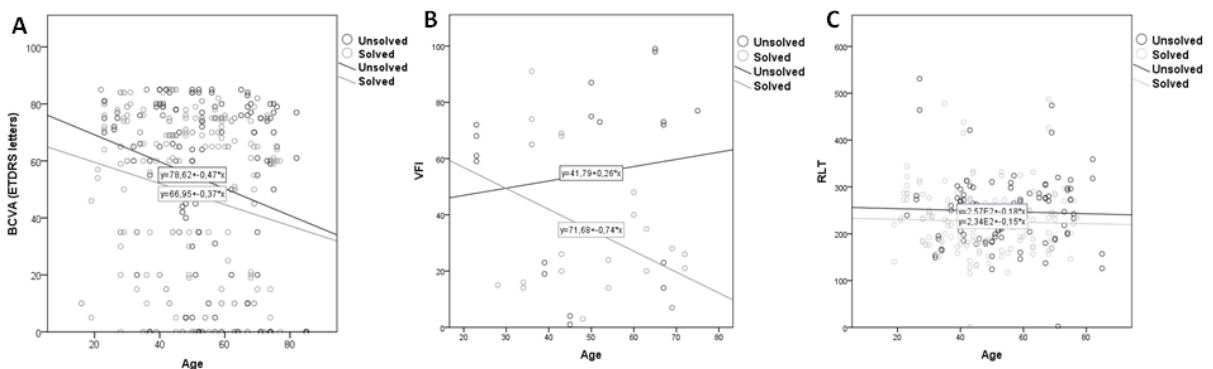


**Figure 2.** Baseline clinical/demographic parameters significantly associated with a higher pre-test probability.

## Functional Testing

No significant differences ( $p=0.099$ ) were observed on BCVA between group 1 ( $53 \pm 31$  ETDRS letters) and group 2 ( $49 \pm 30$  ETDRS letters), even excluding age as a possible confounder ( $\beta=-6.377$ ,  $p=0.059$ ). Correlations between age and BCVA were equally significant in both groups (shown in Table 1). The variation of BCVA according to age is shown in Figure 3A.

VF patterns significantly differ between groups ( $p=0.010$ ). The 3 milder patterns [“isolated scotoma around  $20^\circ$ ”, “peripheral upper and/or lower scotoma (not a ring)” and “ring scotoma in the mid periphery”] were more frequent in group 1 (57.5% of eyes) than group 2 (36.1%); while the 2 more advanced patterns (“small central island” and “almost total scotoma”) were more frequent in group 2 (63.8%) than group 1 (42.5%). The mean MD did not differ between group 1 ( $-20 \pm 8$  dB and  $-23 \pm 8$  dB for the 24-2 and 10-2 strategies, respectively) and group 2 ( $-24 \pm 7$  dB for both the 24-2 and 10-2 strategies), neither for the 24-2 nor for the 10-2 strategy ( $p=0.149$  and  $p=0.680$ , respectively). However, the VFI was significantly higher ( $p=0.020$ ) in group 1 ( $54.42 \pm 31.65\%$ ) than in group 2 ( $33.46 \pm 25.40\%$ ). The variation of VFI according to age is shown in Figure 3B. VFI (AUC=0.688,  $p=0.037$ , 95%CI=0.518-0.857) was able to identify solved and unsolved cases with  $<53.50\%$  as the optimal cut-off (75% sensitivity and 63% specificity). Overall, correlations between VF features and BCVA were more significant in group 2 (shown in Table 1).



**Figure 3.** Average variation of three functional/anatomical parameters with age in genetically solved and unsolved groups: (A) Best-corrected Visual Acuity (BCVA); (B) Visual field index (VFI); and (C) Central Retinal Layer Thickness (RLT). VFI was the only parameter showing statistically significant differences between groups.

**Table 1.** Correlation between BCVA and functional and morphological parameters in group 1 and 2.

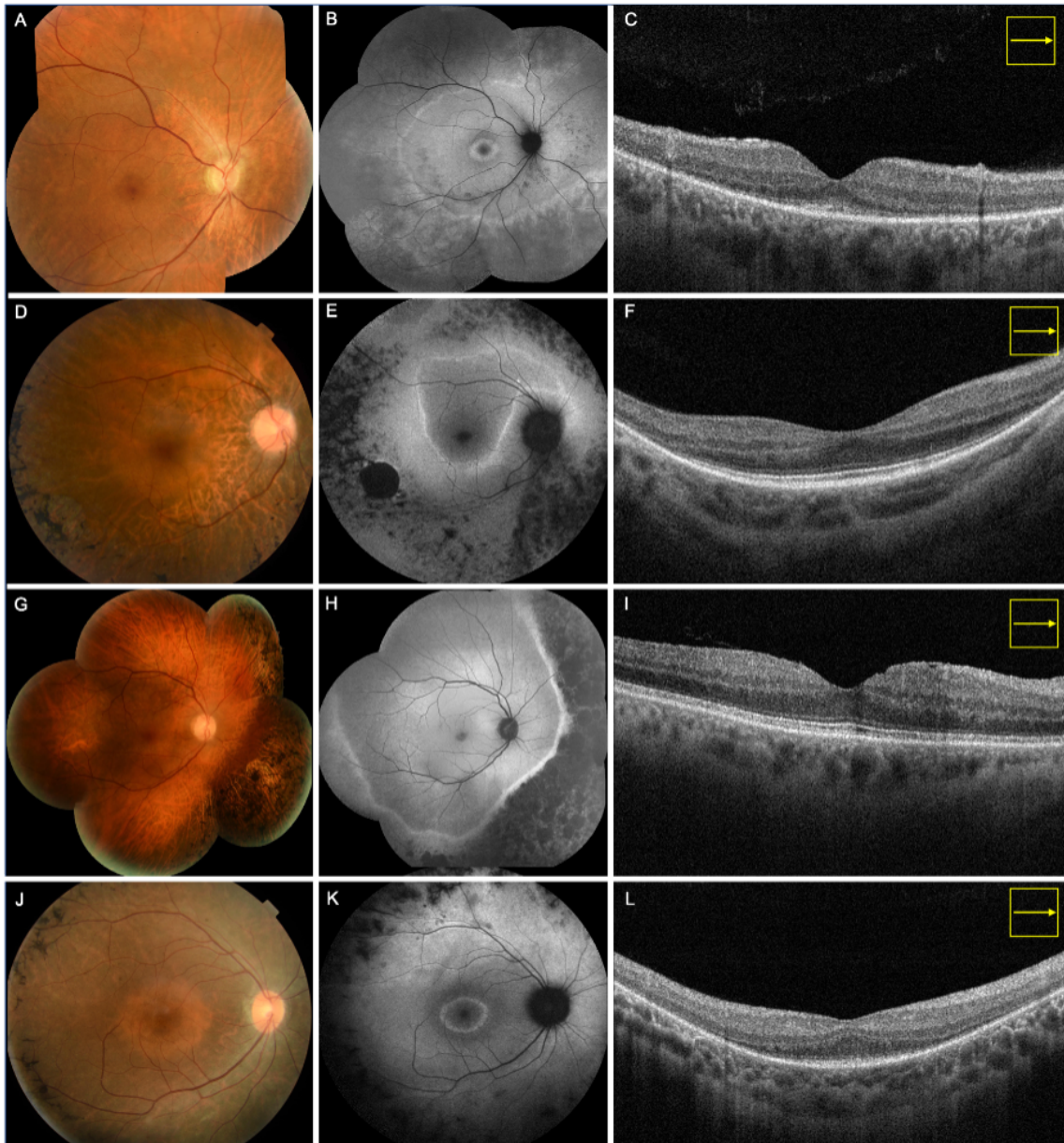
	BCVA			
	Group 1 (Unsolved)		Group 2 (Solved)	
	R	p value	R	p value
<b>Age</b>	-0.233	<b>0.007</b>	-0.190	<b>0.005</b>
<b>Functional testing</b>				
<i>Visual Fields</i>				
VFI	-0.114	0.641	0.762	<b>&lt;0.001</b>
MD	0.355	<b>0.021</b>	0.475	<b>0.001</b>
VF pattern severity increasing	-0.277	0.084	-0.506	<b>&lt;0.001</b>
<b>Multimodal imaging</b>				
<i>FAF</i>				
Ring size	0.495	<b>&lt;0.001</b>	0.274	<b>0.007</b>
<i>OCT and OCT-A</i>				
RLT	0.469	<b>&lt;0.001</b>	0.499	<b>&lt;0.001</b>
SMVD	0.165	0.105	0.192	<b>0.019</b>

Bold values are significant. VF, visual field; MD, mean deviation; VFI, visual field index; FAF, fundus autofluorescence; OCT, optical coherence tomography; OCT-A, optical coherence tomography-angiography; RLT, retinal layer thickness; SMVD, macular vascular density of superficial capillary plexus; BCVA, best-corrected visual acuity.

## Multimodal Imaging

### *Atypical Morphological Features*

Atypical findings in at least one imaging modality (mildly atypical cases) were present in 67.2% of cases in group 1 and 58.8% in group 2 ( $p=0.157$ ). Highly atypical cases were present in 26.7% in group 1 and 33.7% in group 2 ( $p=0.214$ ). For the labeling of atypical cases, different imaging modalities had different contributions. Atypical cases had an atypical FAF pattern in 82.9% and 83.2%; atypical fundus features in 43.9% and 57.7%; and atypical SD-OCT features in 30% and 30.9% , in groups 1 and 2, respectively. Asymmetric disease presentation was observed in 3.2% and 6.1% of cases in groups 1 and 2, respectively ( $p=0.298$ ). In group 2, these were associated with *EYS*, *RPGR*, *NR2E3*, and *USH2A* disease-causing variants. Intrafamilial phenotypic variability was found in 8 families: 2 in group 1 and 6 in group 2. Multimodal imaging examples of genetically solved and unsolved cases are shown in Figures 4 and 5.



**Figure 4.** Multimodal imaging examples of genetically unsolved cases. Each line represents one patient. Only one eye is shown in all cases due to high inter-eye symmetry. All examples display (from left to right) color fundus photography (CFP), fundus autofluorescence (FAF) and spectral-domain optical coherence tomography (SD-OCT). The yellow arrows indicate the orientation of the b-scan. Figures A, B, G and H are mosaic photographs of either CFP or FAF created from multiple individual photographs using the i2k Retina Pro (DualAlign, New York, NY). A-C are from a patient with late-onset (>50 years of age) complaints of decreased vision and visual field constriction. CFP shows absence of bone spicule hyperpigmentation (A). On FAF, a small parafoveal hyperautofluorescent ring is seen, along with a second midperipheral hyperautofluorescent incomplete ring (B). SD-OCT shows eccentric loss of the outer retinal layers (C), a typical finding in retinitis pigmentosa (RP). Whole exome sequencing did not identify clinically significant variants. All additional investigation was negative, including a positron



emission tomography (PET) scan to exclude occult malignancy and antiretinal antibody testing. The only remarkable aspect of this patient's personal history is a difficult-to-treat psoriasis. D-F represent an atypical presentation in an otherwise healthy woman with an affected brother. A next generation sequencing (NGS) panel for RP did not identify clinically significant variants. On FAF (E) a parafoveal hyperautofluorescent irregularly shaped arc is observed. The outer retinal layers are preserved in the central 3 millimeters (F). G-I are from an asymptomatic patient with restriction of retinal atrophy to the far periphery where no clinically significant variants were found on whole exome sequencing. The patient has a personal history of skin melanoma. J-L represent a rather typical RP phenotype in a 26 year old male with no family history of RP. A NGS panel for retinitis pigmentosa (RP) revealed a variant of uncertain significance in a RP-associated gene. Despite segregation analysis, the case remains unsolved.

#### *Color Fundus Photography*

The amount of bone spicule pigmentation was different between group 1 and 2 with significantly more patients in group 2 showing absence/paucity of pigmentation ( $p=0.003$ ), even excluding age as a possible confounder ( $p=0.048$ ). The pattern of bone spicule distribution ( $p=0.509$ ), vessel appearance ( $p=0.360$ ), ONH appearance ( $p=0.497$ ), and presence of chorioretinal atrophy ( $p=0.398$ ) were similar between groups.

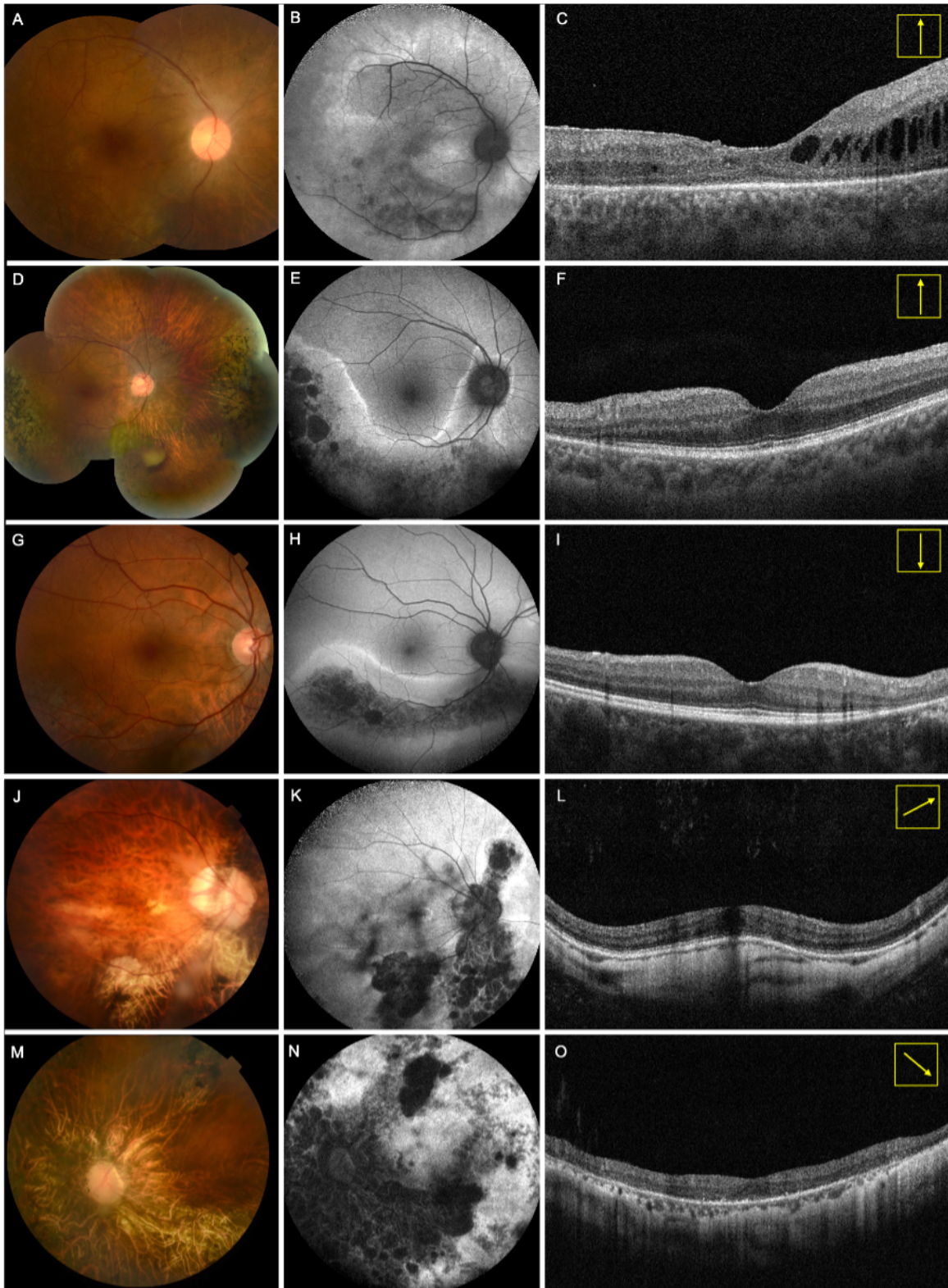
#### *Fundus Autofluorescence*

No significant differences ( $p=0.484$ ) were observed in the frequency of the parafoveal hyperautofluorescent ring [55/121 eyes (43.8%) in group 1 and in 94/188 eyes (50%) in group 2]. The average size of the ring was also similar between groups ( $p=0.551$ ) and correlated positively with BCVA in both groups (shown in Table 1). A regularly-shaped ring was more frequently observed in group 1 ( $p=0.029$ ). ONH drusen were only observed in 1 patient (both eyes) of group 2, in association with disease-causing variants in *BBS2*. No significant differences ( $p=0.784$ ) were observed in the frequency of central hypoAF secondary to macular atrophy.

#### *OCT and OCT-A*

There were no statistically significant differences in the prevalence of CME ( $p=0.245$ ), ERM ( $p=0.068$ ), and VMT ( $p=1.000$ ) between groups. The qualitative evaluation of the ORL was also similar in both groups ( $p=0.276$ ). The mean RLT was higher ( $p=0.032$ ) in group 1 ( $247.37\pm 77.53\mu\text{m}$ ) than in group 2 ( $226.36\pm 73.25\mu\text{m}$ ) and the mean ILT was similar ( $p=0.990$ ) between group 1 ( $42.37\pm 21.94\mu\text{m}$ ) and group 2 ( $42.41\pm 21.65\mu\text{m}$ ). The variation of RLT according to age is shown in Figure 3C, both for group 1 and group 2. Average SMVD was similar

( $p=0.820$ ) between group 1 ( $17.84\pm 24.44$ ) and group 2 ( $17.31\pm 11.19$ ). A positive correlation between SMVD and BCVA was found but only in group 2 (shown in Table I).



**Figure 5.** Multimodal imaging examples of genetically solved cases. All examples display (from left to right) color fundus photography (CFP), fundus autofluorescence (FAF) and spectral-domain optical coherence tomography (SD-OCT). The yellow arrows indicate the orientation

of the b-scan. Figure D is a mosaic photograph created from multiple individual fundus photographs using the i2k Retina Pro (DualAlign, New York, NY). A-C illustrates an atypical presentation associated with two compound heterozygous class IV variants in the *EYS* gene. Note the absence of bone spicule hyperpigmentation (A) and the uncharacteristic FAF pattern (B). Cystic changes are observed on SD-OCT (C). Only one eye is shown due to high inter-eye symmetry. D-F and G-I are both examples of sector retinitis pigmentosa (RP). The first case is associated with *EYS*, while the second is associated with *RHO*. Only one eye is shown due to high inter-eye symmetry. J-O represent the right (J-L) and left (M-O) eye of a female carrier of X-linked RP associated with a class IV variant in *RPGR*. The intereye asymmetry is evident both on CFP (J and M) and on FAF (K and N).

## DISCUSSION

Overall, our study provides evidence that clinical/demographic, functional testing and multimodal imaging differences exist between genetically solved and unsolved retinitis pigmentosa. We have shown that a younger age of symptom onset, presence of consanguinity in the family, evidence for a particular inheritance pattern and absence of indicators for phenocopies positively impact the diagnostic yield in patients with nsRP. Despite no changes in BCVA were noted between groups, unsolved cases were more likely to present larger fields, a VFI>53.5% and a higher RLT.

Currently available NGS panels make it possible to identify the genetic basis of nsRP in 25-80% of patients.<sup>6,7,9,19,21,26-29</sup> Nevertheless, a large proportion of patients still remain genetically unsolved. Early-onset of symptoms, consanguinity or family history/evidence for an inheritance pattern have been identified as clinical/demographic features associated with a higher diagnostic yield.<sup>13,19-21</sup> Additionally, in a cohort of 112 consecutive nsRP patients (77 solved and 35 unsolved), Birtel et al<sup>13</sup> reported that atypical morphological fundus features and the presence of indicators for phenocopies were significantly more frequent in genetically unsolved cases. In the present study, detailed medical history data along with deep phenotyping were used to thoroughly characterize genetically solved and genetically unsolved cases of nsRP.

First, we observed that early onset of symptoms, consanguinity, evidence for a particular inheritance pattern and absence of indicators for phenocopies were significantly more prevalent in genetically solved cases. These findings are in agreement with previous studies.<sup>13,20,21</sup> Furthermore, a statistical model including onset of symptoms in childhood, history of consanguinity and absence of potential phenocopies was able to predict a solved case in our nsRP cohort ( $\chi^2(1)=16.101$ ;  $p=0.001$ ,  $R^2_{\text{Negelkerke}}=0.064$ ).

Second, we looked at objective measures of vision or functional ability. BCVA did not prove useful to differentiate solved from unsolved cases. However, VF testing revealed significant

differences between groups. The visual field index (VFI) is a global metric that represents the entire visual field as a single number. It is estimated by calculating age corrected defect depth at the test points identified as significantly depressed in pattern deviation maps. It is expressed in percentage, where 100% represents a normal visual field and 0% represents a perimetrically blind field.<sup>30</sup> Our results showed that unsolved cases have larger fields and a significantly higher VFI, thus translating in less severe disease. This cannot be captured by BCVA testing alone. In fact, among different measures of visual function, VF size has been shown to be the best predictor of poor mobility in patients with RP.<sup>31</sup> We found that more advanced VF patterns were more frequently seen in genetically solved cases and identified a VFI <53.50% as the optimal cut-off to differentiate solved from unsolved cases (75% sensitivity; 63% specificity). The worse visual field in solved cases may be explained by the earlier onset of symptoms in this group and consequently, longer disease duration. Despite the similar BCVA between groups, the correlation between VF parameters and BCVA was stronger in genetically solved cases than in unsolved cases (shown in Table 1), thus suggesting that other factors must be involved.

Third, we used multimodal imaging to deeply characterize the retinal phenotype of solved and unsolved cases. Atypical findings in at least one imaging modality were present in similar frequency between genetically solved and unsolved cases, thus emphasizing the phenotypic heterogeneity that characterizes nsRP. However, these results conflict with the findings of Birtel et al<sup>13</sup> The authors reported that phenotypic variation from RP-defining fundus features were identified in 8% (6/77) and 49% (17/35) of genetically solved and unsolved cases, respectively. Differences in the genetic landscape of nsRP between Portugal and Germany may be responsible for this discrepancy. Asymmetric disease presentation has been recognized in 3.7 to 14% of nsRP cases. Both Jauregui et al<sup>5</sup> and Sujirakul et al<sup>3</sup> reported that disease asymmetry was highest in AD-RP, especially in association with *RPI* and *RHO* disease-causing variants. In our cohort, asymmetric disease presentation was observed in 3.2% and 6.1% of cases in groups 1 and 2, respectively. Interestingly, asymmetric cases in the solved group were associated with *EYS*, *RPGR*, *NR2E3*, and *USH2A* disease-causing variants and not with AD genes. On the one hand, this reflects the phenotypical heterogeneity that characterizes nsRP and the importance of deep phenotyping to establish genotype-phenotype correlations. On the other hand, it evidences that genetic profiles vary among regions and ethnic groups, highlighting the importance of obtaining reference population-based data. On SD-OCT, genetically solved patients had a lower average RLT. Since the ILT was similar between groups, the lower RLT must be secondary to outer retinal layer thinning which probably reflects more advanced disease.

Limitations of this study include the subjective nature of grading atypical features; challenges to establish a definite diagnosis of a phenocopy; and the dependence on the patient/family to obtain precise history information. Additionally, we did not include grading of

electrophysiology testing results as a substantial proportion of patients had the testing performed only at baseline, ie several years before. Nevertheless, we were able to collect detailed clinical/demographic, functional and multimodal imaging features in a cohort of 175 patients with nsRP. Unlike Birtel et al,<sup>13</sup> we excluded variants of unknown significance from the solved cases population, thus eliminating a possible overestimation of the genetically solved group.

In conclusion, careful medical history taking and deep phenotyping were shown to impact the genetic diagnostic yield and prognosis in nsRP. Individual clinical/demographic, functional testing and multimodal imaging features should be considered when counselling patients about the probability of identifying disease-causing variants.

## REFERENCES

1. Verbakel SK, van Huet RAC, Boon CJF, et al. Non-syndromic retinitis pigmentosa. *Prog Retin Eye Res* 2018;66:157-186. DOI: 10.1016/j.preteyeres.2018.03.005.
2. Schuerch K, Marsiglia M, Lee W, Tsang SH, Sparrow JR. Multimodal Imaging of Disease-Associated Pigmentary Changes in Retinitis Pigmentosa. *Retina* 2016;36 Suppl 1:S147-S158. DOI: 10.1097/IAE.0000000000001256.
3. Sujirakul T, Davis R, Erol D, et al. Bilateral Concordance of the Fundus Hyperautofluorescent Ring in Typical Retinitis Pigmentosa Patients. *Ophthalmic Genet* 2015;36(2):113-22. DOI: 10.3109/13816810.2013.841962.
4. Farrell DF. Unilateral retinitis pigmentosa and cone-rod dystrophy. *Clin Ophthalmol* 2009;3:263-70. DOI: 10.2147/oph.s5130.
5. Jauregui R, Chan L, Oh JK, Cho A, Sparrow JR, Tsang SH. Disease asymmetry and hyperautofluorescent ring shape in retinitis pigmentosa patients. *Sci Rep* 2020;10(1):3364. DOI: 10.1038/s41598-020-60137-9.
6. Gao FJ, Li JK, Chen H, et al. Genetic and Clinical Findings in a Large Cohort of Chinese Patients with Suspected Retinitis Pigmentosa. *Ophthalmology* 2019;126(11):1549-1556. DOI: 10.1016/j.ophtha.2019.04.038.
7. Perea-Romero I, Gordo G, Iancu IF, et al. Genetic landscape of 6089 inherited retinal dystrophies affected cases in Spain and their therapeutic and extended epidemiological implications. *Sci Rep* 2021;11(1):1526. DOI: 10.1038/s41598-021-81093-y.
8. Birtel J, Gliem M, Mangold E, et al. Next-generation sequencing identifies unexpected genotype-phenotype correlations in patients with retinitis pigmentosa. *PLoS One* 2018;13(12):e0207958. DOI: 10.1371/journal.pone.0207958.

9. Weisschuh N, Obermaier CD, Battke F, et al. Genetic architecture of inherited retinal degeneration in Germany: A large cohort study from a single diagnostic center over a 9-year period. *Hum Mutat* 2020;41(9):1514-1527. DOI: 10.1002/humu.24064.
10. Bravo-Gil N, Gonzalez-Del Pozo M, Martin-Sanchez M, et al. Unravelling the genetic basis of simplex Retinitis Pigmentosa cases. *Sci Rep* 2017;7:41937. DOI: 10.1038/srep41937.
11. Huang XF, Wu J, Lv JN, Zhang X, Jin ZB. Identification of false-negative mutations missed by next-generation sequencing in retinitis pigmentosa patients: a complementary approach to clinical genetic diagnostic testing. *Genet Med* 2015;17(4):307-11. DOI: 10.1038/gim.2014.193.
12. Eisenberger T, Neuhaus C, Khan AO, et al. Increasing the yield in targeted next-generation sequencing by implicating CNV analysis, non-coding exons and the overall variant load: the example of retinal dystrophies. *PLoS One* 2013;8(11):e78496. DOI: 10.1371/journal.pone.0078496.
13. Birtel J, Gliem M, Oishi A, et al. Genetic testing in patients with retinitis pigmentosa: Features of unsolved cases. *Clin Exp Ophthalmol* 2019;47(6):779-786. DOI: 10.1111/ceo.13516.
14. Sekimoto M, Hayasaka S, Noda S, Setogawa T. Pseudoretinitis pigmentosa in patients with systemic lupus erythematosus. *Ann Ophthalmol* 1993;25(7):264-6.
15. Lotery AJ, McBride MO, Larkin C, Sharkey JA. Pseudoretinitis pigmentosa due to sub-optimal treatment of neurosyphilis. *Eye (Lond)* 1996;10 ( Pt 6):759-60. DOI: 10.1038/eye.1996.182.
16. Heckenlively JR, Fawzi AA, Oversier J, Jordan BL, Aptsiauri N. Autoimmune retinopathy: patients with antirecoverin immunoreactivity and panretinal degeneration. *Arch Ophthalmol* 2000;118(11):1525-33. DOI: 10.1001/archopht.118.11.1525.
17. Makiyama Y, Kikuchi T, Otani A, et al. Clinical and immunological characterization of paraneoplastic retinopathy. *Invest Ophthalmol Vis Sci* 2013;54(8):5424-31. DOI: 10.1167/iovs.13-11868.
18. Marsiglia M, Duncker T, Peiretti E, Brodie SE, Tsang SH. Unilateral retinitis pigmentosa: a proposal of genetic pathogenic mechanisms. *Eur J Ophthalmol* 2012;22(4):654-60. DOI: 10.5301/ejo.5000086.
19. Branham K, Schlegel D, Fahim AT, Jayasundera KT. Genetic testing for inherited retinal degenerations: Triumphs and tribulations. *Am J Med Genet C Semin Med Genet* 2020;184(3):571-577. DOI: 10.1002/ajmg.c.31835.

20. Shanks ME, Downes SM, Copley RR, et al. Next-generation sequencing (NGS) as a diagnostic tool for retinal degeneration reveals a much higher detection rate in early-onset disease. *Eur J Hum Genet* 2013;21(3):274-80. DOI: 10.1038/ejhg.2012.172.
21. Colombo L, Maltese PE, Castori M, et al. Molecular Epidemiology in 591 Italian Proband With Nonsyndromic Retinitis Pigmentosa and Usher Syndrome. *Invest Ophthalmol Vis Sci* 2021;62(2):13. DOI: 10.1167/iovs.62.2.13.
22. Marques JP, Carvalho AL, Henriques J, Murta JN, Saraiva J, Silva R. Design, development and deployment of a web-based interoperable registry for inherited retinal dystrophies in Portugal: the IRD-PT. *Orphanet J Rare Dis* 2020;15(1):304. DOI: 10.1186/s13023-020-01591-6.
23. Popovic P, Jarc-Vidmar M, Hawlina M. Abnormal fundus autofluorescence in relation to retinal function in patients with retinitis pigmentosa. *Graefes Arch Clin Exp Ophthalmol* 2005;243(10):1018-27. DOI: 10.1007/s00417-005-1186-x.
24. Hood DC, Lazow MA, Locke KG, Greenstein VC, Birch DG. The transition zone between healthy and diseased retina in patients with retinitis pigmentosa. *Invest Ophthalmol Vis Sci* 2011;52(1):101-8. DOI: 10.1167/iovs.10-5799.
25. Richards S, Aziz N, Bale S, et al. Standards and guidelines for the interpretation of sequence variants: a joint consensus recommendation of the American College of Medical Genetics and Genomics and the Association for Molecular Pathology. *Genet Med* 2015;17(5):405-24. DOI: 10.1038/gim.2015.30.
26. Koyanagi Y, Akiyama M, Nishiguchi KM, et al. Genetic characteristics of retinitis pigmentosa in 1204 Japanese patients. *J Med Genet* 2019;56(10):662-670. DOI: 10.1136/jmedgenet-2018-105691.
27. Zhao L, Wang F, Wang H, et al. Next-generation sequencing-based molecular diagnosis of 82 retinitis pigmentosa probands from Northern Ireland. *Hum Genet* 2015;134(2):217-30. DOI: 10.1007/s00439-014-1512-7.
28. Xu Y, Guan L, Shen T, et al. Mutations of 60 known causative genes in 157 families with retinitis pigmentosa based on exome sequencing. *Hum Genet* 2014;133(10):1255-71. DOI: 10.1007/s00439-014-1460-2.
29. Wang J, Zhang VW, Feng Y, et al. Dependable and efficient clinical utility of target capture-based deep sequencing in molecular diagnosis of retinitis pigmentosa. *Invest Ophthalmol Vis Sci* 2014;55(10):6213-23. DOI: 10.1167/iovs.14-14936.
30. Iutaka NA, Grochowski RA, Kasahara N. Correlation between Visual Field Index and Other Functional and Structural Measures in Glaucoma Patients and Suspects. *J Ophthalmic Vis Res* 2017;12(1):53-57. DOI: 10.4103/jovr.jovr\_98\_16.

31. Costela FM, Pesudovs K, Sandberg MA, Weigel-DiFranco C, Woods RL. Validation of a vision-related activity scale for patients with retinitis pigmentosa. *Health Qual Life Outcomes* 2020;18(1):196. DOI: 10.1186/s12955-020-01427-8.



Manuscript 8

**3.2. EYS-associated Sector Retinitis Pigmentosa**

João Pedro Marques

Fernanda Belga Ottoni Porto

Ana Luísa Carvalho

Emmanuel Neves

Rui Chen

Shirley Aparecida Madureira Sampaio

Joaquim Murta

Jorge Saraiva

Rufino Silva

*Published in: Graefes Arch Clin Exp Ophthalmol. 2022 Apr;260(4):1405-1413.*

## **ABSTRACT**

### **Purpose**

Sector retinitis pigmentosa (RP) is a rare form of rod-cone degeneration typically associated with mutations in the *RHO* gene. We describe six unrelated patients presenting with this atypical phenotype in association with biallelic mutations in *EYS* gene.

### **Methods**

Multinational, multicentre cross-sectional case series. Patients with biallelic disease-causing variants in *EYS* and a clinical diagnosis of sector RP were recruited from specialized centres in Portugal and Brazil. All patients underwent a comprehensive ophthalmologic examination complemented by deep phenotyping. Peripheral blood samples were collected from all probands and available relatives for genetic analysis. Genetic counselling was provided to all subjects.

### **Results**

Seven disease-causing variants (4 pathogenic; 3 likely pathogenic) were identified in 6 unrelated female patients. Best-corrected visual acuity ranged from 75 to 85 ETDRS letters. All eyes showed bilateral and symmetrical areas of outer retinal atrophy distributed along the inferior vascular arcades and extending temporally and/or nasally in a crescent-shaped pattern. On fundus autofluorescence (AF), a foveal-sparing curvilinear band of hyperAF encroaching the optic nerve head and extending temporally was seen in 4 patients. The remaining 2 presented bilateral and symmetrical patches of hypoAF inside crescent-shaped areas of hyperAF along the inferior temporal vascular arcade. Visual field testing revealed superior visual field defects of varying extents, always in close association with the fundus AF findings.

### **Conclusions**

Even though *EYS* has only recently been listed as a cause of the sector RP phenotype, we believe that this presentation is not infrequent and should be considered an important differential for sector RP.

## INTRODUCTION

Sector retinitis pigmentosa (RP) is a rare, atypical and milder form of rod-cone degeneration in which only one or two quadrants of the retina are involved.<sup>1,2</sup> The disorder is characterized by bilateral and symmetrical regionalized areas of retinal pigment epithelium (RPE) atrophy and bone spicule hyperpigmentation, usually in the inferior or inferonasal quadrants, corresponding to superior defects on visual field testing.<sup>3,4</sup> This peculiar pattern of degeneration is most noticeable on fundus autofluorescence (FAF) imaging with hypoautofluorescent (hypoAF) regions corresponding to the areas of RPE atrophy and bone spicule hyperpigmentation, and a thick, crescent-shaped band of hyperautofluorescence (hyperAF) separating these areas from the unaffected, iso-autofluorescent retina.<sup>4,6</sup> Nevertheless, unilateral or asymmetrical involvement, as well as predominantly nasal, superotemporal, or superior quadrants degeneration have been reported.<sup>7</sup> Affected individuals may be asymptomatic or present with nyctalopia, mild visual loss and/or visual field defects of varying extent, depending on the affected regions of the retina.<sup>4,5</sup> Although historically considered a stationary to slowly progressive RP phenotype, sector RP may ultimately lead to a more severe, diffuse rod-cone degeneration.<sup>8,9</sup>

Most cases of sector RP are inherited in an autosomal dominant pattern and are caused by missense mutations in the rhodopsin gene (*RHO*, 3q22.1, MIM \*180380),<sup>4,5,8,10</sup> Nevertheless, mutations in the usherin (*USH1C*, 11p15.1, MIM \*605242),<sup>10,11</sup> cadherin 23 (*CDH23*, 10q22.1, MIM \*605516),<sup>10,12</sup> retinol dehydrogenase 5 (*RDH5*, 12q13.2, MIM \*601617),<sup>13</sup> arrestin (*SAG*, 2q37.1, MIM \*181031),<sup>14,15</sup> and in the RP GTPase Regulator (*RPGR*, Xp11.4, MIM \*312610)<sup>4,10</sup> genes have also been reported in association with this unique phenotype. Recently, Georgiou et al<sup>10</sup> further expanded the mutational spectrum of sector RP by identifying causative variants in 5 genes that were not previously implicated (*PRPS1*, *MYO7A*, *EYS*, *IMPDH1*, and *RPI*). Biallelic mutations in one of these genes, the eyes shut homolog gene (*EYS*, 6q12, MIM \*612424) are among the most commonly found disease-causing variants in autosomal-recessive RP in Asian and European populations.<sup>16-19</sup> With 44 exons, spanning 2.0 Mb of genomic DNA, *EYS* is the largest-known retina-specific gene and encodes a product 3165 amino acids in length.<sup>20,21</sup> High phenotypic and genetic heterogeneity exists in *EYS*-related retinal degeneration.<sup>17,19,22-24</sup> However, a clear association with the sector RP phenotype was only recently established.<sup>10</sup>

We describe the genotypes and phenotypes of six unrelated patients with *EYS*-related sector RP and provide a review of previously reported mutations in *EYS* associated with phenotypic descriptions that fall into the spectrum of this clinical entity.

## METHODS

### *Study design and Diagnostic Criteria*

Multinational, multicenter cross-sectional case series. Patients with biallelic disease-causing variants in *EYS* gene and a clinical diagnosis of sector RP were recruited from the IRD-PT registry<sup>25</sup> in Portugal and from the INRET *Clínica e Centro de Pesquisa* in Brazil. The clinical diagnosis of sector RP was based on the presence of regionalized areas of RPE atrophy ( $\pm$  bone spicule hyperpigmentation), with corresponding FAF abnormalities and visual field defects, and the exclusion of any known reasons, such as trauma, infection or inflammation, for the RP-like appearance of the fundus.

The study was conducted at the Retinal Dystrophies Clinic and Medical Genetics Unit of *Centro Hospitalar e Universitário de Coimbra (CHUC)*, Coimbra, Portugal (*patients 1, 2 and 3*), and *INRET Clínica e Centro de Pesquisa*, Belo Horizonte, Brazil (*patients 4, 5 and 6*). Informed consent was obtained for every included subject. The study was approved by the local Ethics Committee and followed the tenets of the Declaration of Helsinki for biomedical research.

### **Ophthalmic Examination and Imaging**

All patients underwent a comprehensive ophthalmologic examination including best-corrected visual acuity (BCVA, ETDRS letters), dilated slit-lamp anterior segment and fundus biomicroscopy, seven standard 45°-field color fundus photographs (CFP) taken with a Nikon Digital SLR Camera D7000 (Nikon Corporation, Japan) mounted on either a TRC-NW7SF or TRC-NW8 Mark II Retinal Camera (Topcon Corporation, Japan), spectral-domain optical coherence tomography (SD-OCT) (Spectralis, Heidelberg Engineering, Heidelberg, Germany or Avanti RTVue-XR 100, Optovue Inc, Fremont, CA, USA), FAF (HRAII, Heidelberg Engineering, Heidelberg, Germany), and Humphrey visual field testing (Zeiss 750i, Carl Zeiss, Germany). Four probands (Patients 2, 4, 5 and 6) underwent full-field electroretinogram (ffERG) using the RETIscan system (Roland Consult, Germany) or UTAS Sunburst (LKC Technologies, USA), with DTL-Plus electrodes, according to the International Society for Clinical Electrophysiology of Vision (ISCEV) standards in photopic and scotopic states.<sup>26</sup>

### **Genetic Testing**

Peripheral blood samples were collected from all probands and available relatives for genetic analysis. The genomic DNA was extracted using a genomic DNA extraction and purification kit based on the manufacturer's protocol. Variants were classified in accordance with the American College of Medical Genetics and Genomics (ACMG). The genetic study of patients 1, 2 and 3 was coordinated by a medical geneticist (ALC) from the Medical Genetics Unit of CHUC. In these patients, genetic studies were carried out at different times. Therefore, different tests were performed according to their availability. In patient 1, a NGS panel for RP (187 genes) was used. Patient 2 initially underwent Sanger sequencing for the *RHO* gene. Since

no clinically significant variants were found, a NGS panel for retinal dystrophies (309 genes) was then used. In patient 3 targeted mutation analysis (Sanger sequencing and MLPA) was used to confirm the pathogenic variants previously identified in a family member (a sister in whom *EYS*-related pathogenic variants causing a typical RP phenotype had previously been identified using the 187 genes NGS panel for RP). Patients 4, 5 and 6 were genotyped using a NGS panel of 224 genes known to cause retinal disease. Captured DNA was sequenced on the Illumina HiSeq platform and NGS data was processed by an in-house bioinformatics pipeline leading to annotated variant calls.<sup>27</sup> All clinically significant variants were further confirmed by Sanger sequencing. A published cDNA sequence for *EYS* (GenBank NM\_001142800.1) was compared with the sequencing results. Sanger sequencing and next-generation sequencing (NGS) were performed at diagnostic labs, with good quality control at the raw data stage, the alignment and the variant calling. Regarding raw data of Sanger sequencing, there were not any artifacts, peaks were well-resolved and with acceptable heights, data start points were not deviated from others, length of the read was the expected, and baseline noise was very little or not present. Genetic counselling provided by a medical geneticist was granted to all subjects.

## RESULTS

### *Clinical phenotypes*

Demographic and genetic information is presented in Table 1. The average age at diagnosis was 45 years (range 29-58 years), and all patients were female. Parental consanguinity ( $r = 1/8$ ) was reported in patient 2, while a positive family history of RP was identified both in patient 2 and in patient 3. Patient 2 has 1 affected brother and had 1 sister (now deceased) with a clinical diagnosis of RP. Unfortunately, they were never observed at our center. Patient 3 has an affected sister presenting with a typical RP phenotype (thus not included in this cohort).

Three patients (1, 4 and 5) had obvious symptoms at presentation. Patient 1 complained of nyctalopia from age 30; patient 4 presented loss of central vision and difficulties while reading; and patient 6 described an upper visual field restriction. The other 3 patients (patients 2, 3 and 6) were asymptomatic and the abnormal appearance of the fundus was noted upon routine ophthalmic examination.

All patients had a relatively good BCVA, ranging from 20/32 to 20/20 (Table 1). Posterior subcapsular lens opacification was observed in 3 patients (patients 1, 2 and 6). On CFP, all eyes showed bilateral and symmetrical areas of outer retinal atrophy distributed along the inferior vascular arcades and extending temporally and/or nasally in a crescent-shaped pattern (Figure 1). Peripapillary atrophy was also present in all eyes. Intraretinal pigment migration in the form of bone-spicule hyperpigmentation was observed in both eyes of patients 1, 2 and 6. On FAF,

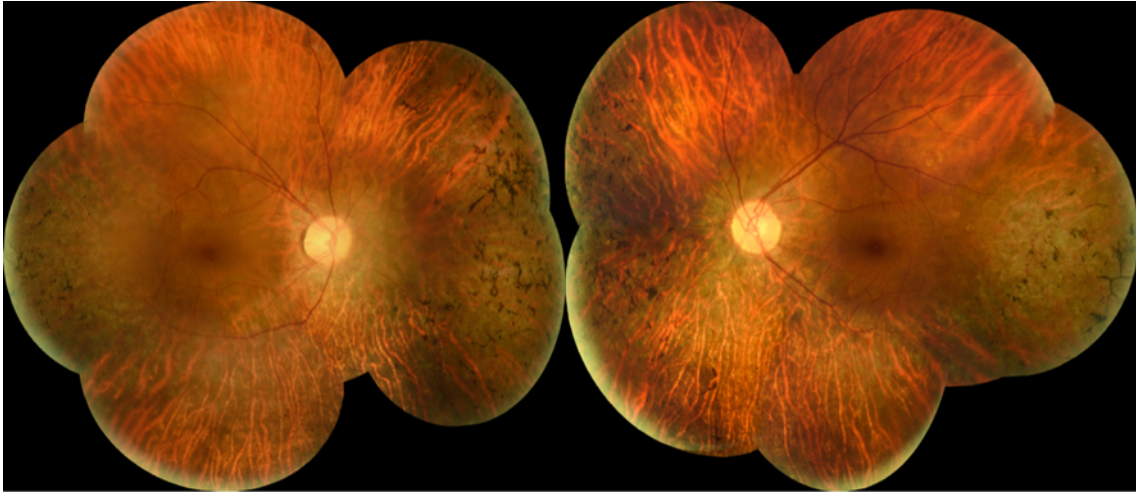
patients 1, 2, 4 and 5 showed bilateral and symmetrical hypoAF regions corresponding to the regionalized retinal degeneration seen on CFP, along with a foveal-sparing curvilinear band of hyperAF encroaching the optic nerve head and extending temporally (Figures 2A, 2B, 4A and 4B). Patients 3 and 6 presented bilateral and symmetrical patches of hypoAF inside crescent-shaped areas of hyperAF along the inferior temporal vascular arcade, even though the FAF changes did not encroach the optic nerve head (Figure 2C). Visual field testing revealed superior visual field defects of varying extents, always in close association with the observed FAF findings (Figure 2). The horizontal cross-scan of the SD-OCT showed a normal foveal architecture in all but patient 4 who presented bilateral, centre-involving cystoid macular edema (Figure 4C and 4D). Outer retinal atrophy and RPE thinning were noted in scans over the affected areas of retinal degeneration (Figures 3C, 3D, 4C and 4D). The ffERG of patients 2 (Figure 1), 4, 5 and 6 (Supplemental Figure 1) revealed marginally recordable, albeit significantly decreased, scotopic and photopic responses.

**Table 1.** Demographic and genetic information of the cohort

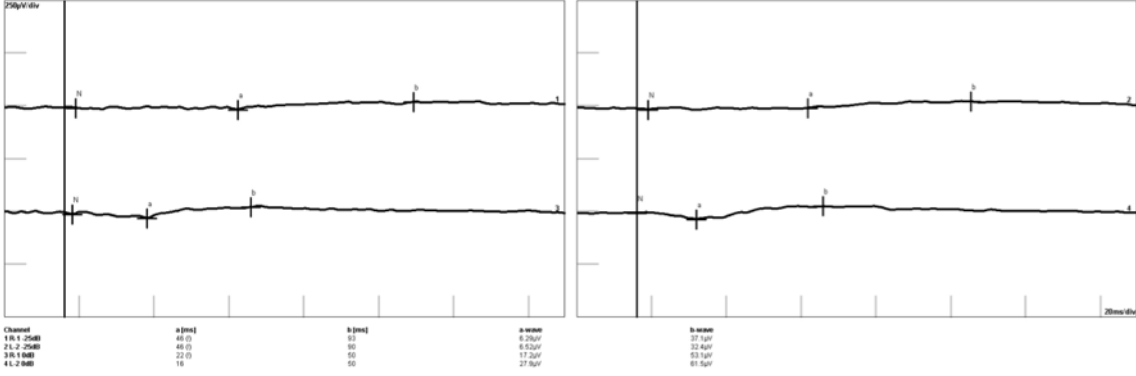
ID	Age	Sex	FH	Consanguinity	BCVA <sup>§</sup>		Genotype - EYS (NM_001142800.1)	
					OD	OS	Variant 1	Variant 2
P1	66	F	N	N	83 (20/25+3)	76 (20/32+1)	c.2225del p.(Cys742Leufs*36)	c.2225del p.(Cys742Leufs*36)
P2	58	F	Y	Y	75 (20/32)	75 (20/32)	c.5928-2A>G p.?	c.5928-2A>G p.?
P3	35	F	Y	N	85 (20/20)	85 (20/20)	c.2225del p.(Cys742Leufs*36)	c.(2023+1_2024-1) _(2259+1_2260-1)del
P4	55	F	N	N	85 (20/20)	85 (20/20)	c.5928-2A>G p.?	c.6794del p.(Pro2265fs)
P5	39	F	N	N	75 (20/32)	75 (20/32)	c.5928-2A>G p.?	c.2820_2824delTGGAA p.(Gly941Metfs*11)
P6	64	F	N	N	75 (20/32)	75 (20/32)	c.9122C>T p.(Ile3041Thr)	c.8897A>G p.(Gly2966Glu)

<sup>§</sup> expressed in ETDRS letters and Snellen equivalent

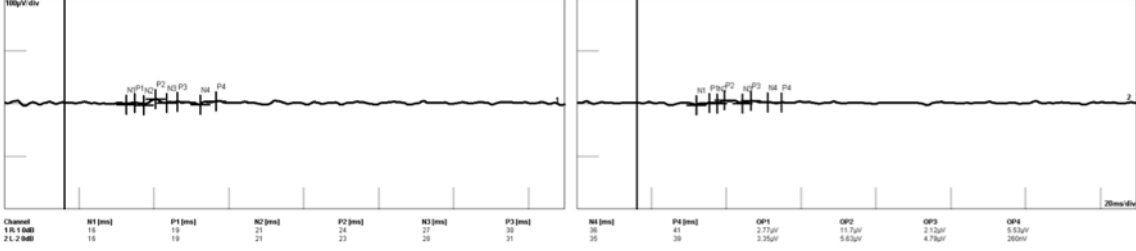
F – female; FH – family history; N – no; Y – yes; BCVA – best-corrected visual acuity



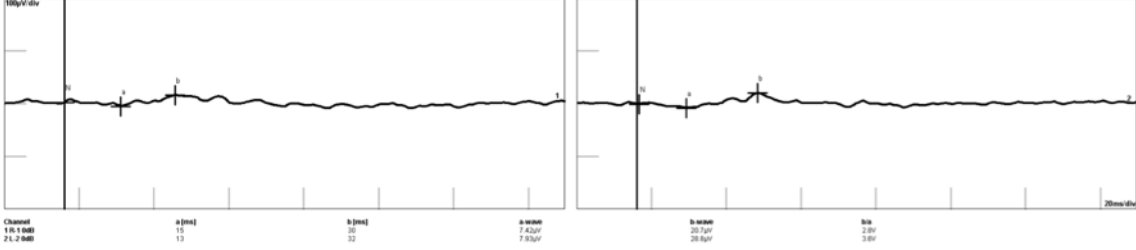
scot. ERG



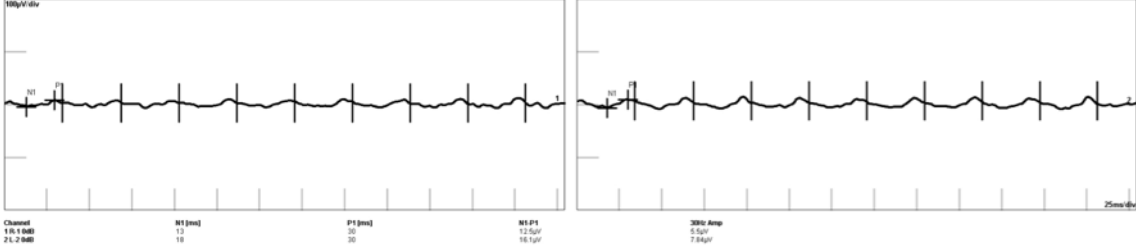
Oscillatory-P.



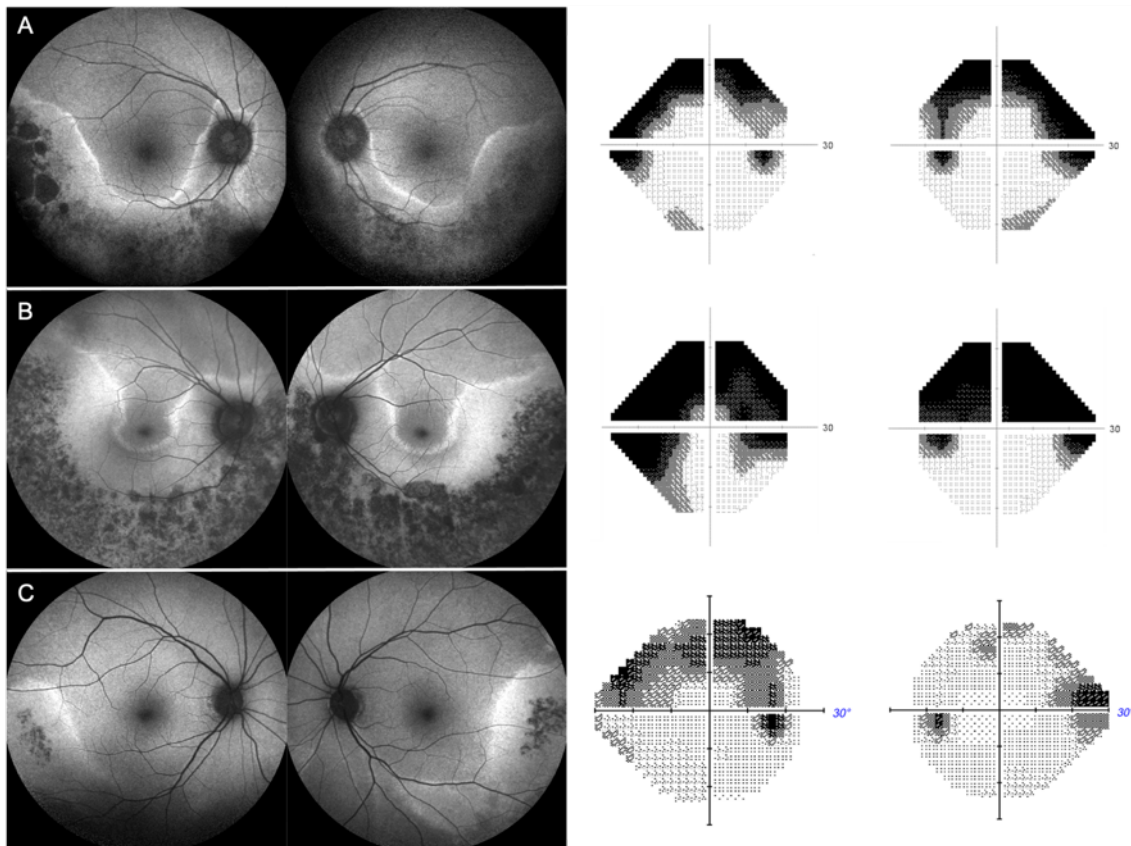
phot. ERG



30Hz Flicker



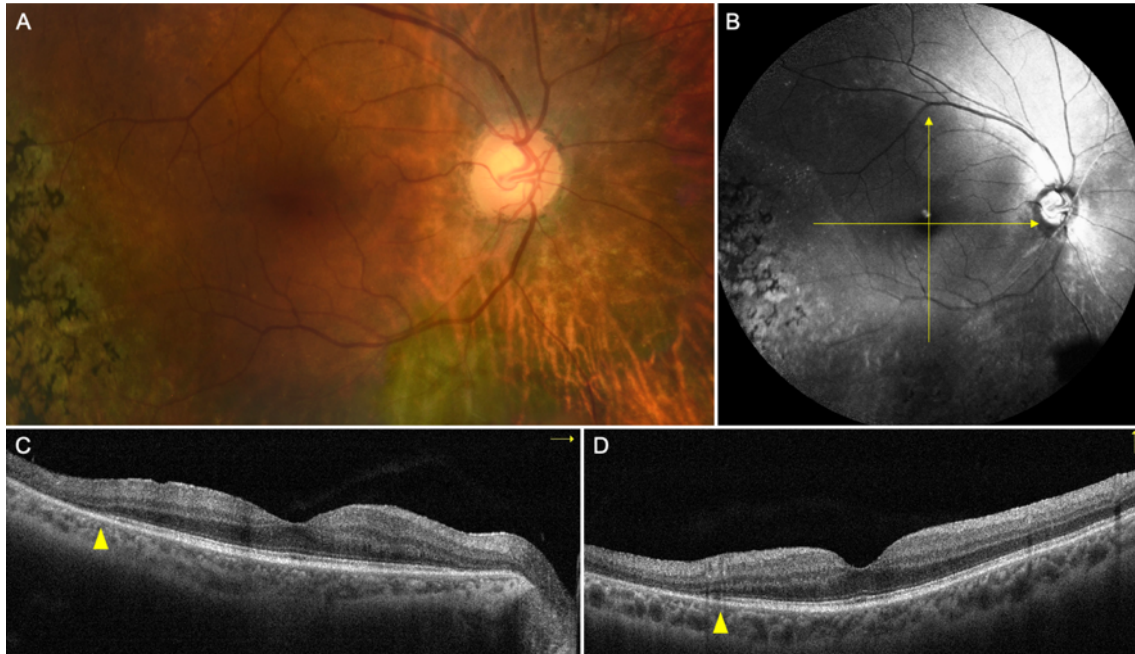
**Figure 1** Montage color fundus photography (CFP) and full field electroretinography (ffERG) from Patient 2 (right and left eye, respectively). On CFP, bilateral and symmetrical areas of outer retinal atrophy distributed along the inferior vascular arcades and extending temporally and nasally in a crescent-shaped pattern can be observed. Vascular attenuation and intraretinal pigment migration in the form of bone-spicule hyperpigmentation are also seen. Mild peripapillary atrophy is present in both eyes. The following ffERG waves are shown from top to bottom (for the right and left eye, respectively): dark-adapted (DA) 0.01 cd.s.m<sup>-2</sup>; DA 3.0 cd.s.m<sup>-2</sup>; DA oscillatory potentials; light-adapted (LA) 3.0 cd.s.m<sup>-2</sup>; and LA 30 Hz flicker ERG. The ffERG was non-recordable for the DA 0.01 and DA oscillatory potentials waveforms, while very residual electrical activity (low amplitude and poorly defined waves) was observed for the DA 3.0, LA 3.0 and LA 30 Hz flicker ERG waveforms.



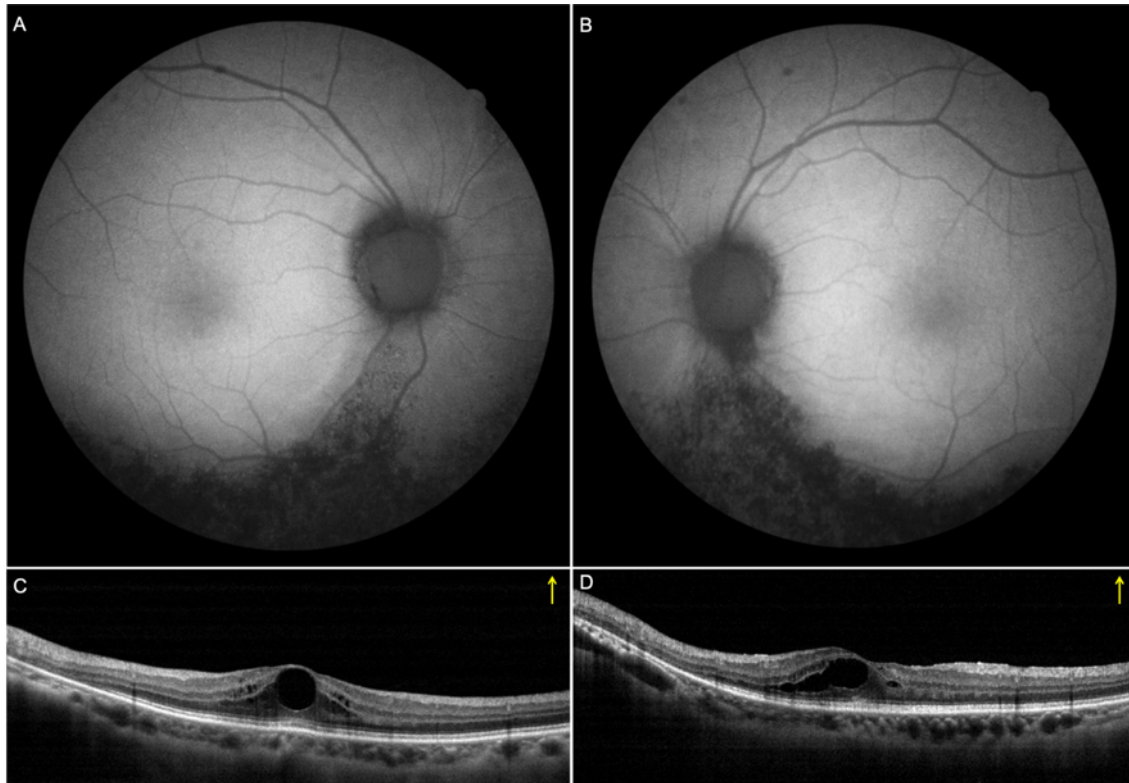
**Figure 2** Fundus autofluorescence (FAF) and corresponding Humphrey 24-2 grayscale visual field maps. In patients 1 (**A**) and 2 (**B**), hypoautofluorescent regions corresponding to the areas of regionalized retinal degeneration are seen along with a thick curvilinear band of hyperautofluorescence separating the unaffected, iso-autofluorescent retina from the affected regions. In both cases, the affected area encroaches the optic nerve head and extends temporally, although sparing the fovea. In patient 3 (**C**), bilateral and symmetrical patches of



hypoautofluorescence are observed inside crescent-shaped areas of hyperautofluorescence along the inferior temporal vascular arcade. In all cases, the anatomic-functional correlation can be appreciated in the 24-2 Humphrey visual fields.



**Figure 3** Color Fundus Photography (CFP), near-infrared (NIR) imaging and spectral-domain optical coherence tomography (SD-OCT) of the right eye of patient 1. **(A)** On CFP, outer retinal atrophy distributed along the inferior temporal vascular arcade in a crescent-shaped pattern is seen along with intraretinal pigment migration in the form of bone-spicule hyperpigmentation. Mild peripapillary atrophy is also observed. **(B)** The demarcation area between normal and abnormal retina is better appreciated on NIR imaging. **(C)** Horizontal SD-OCT scan shows normal foveal anatomy and preservation of the subfoveal inner and outer retinal layers and retinal pigment epithelium (RPE)/Bruch membrane complex. Loss of the ellipsoid zone, external limiting membrane and outer nuclear layer is observed temporally (yellow arrowhead). In the same area, thinning of the RPE/Bruch membrane complex is also observed. **(D)** Vertical SD-OCT scan shows similar findings but with loss of the outer retinal layers and thinning of the RPE/Bruch membrane complex in the inferior macula (yellow arrowhead).



**Figure 4** Fundus autofluorescence (FAF) and vertical spectral-domain optical coherence tomography (SD-OCT) scans of patient 4. Bilateral areas of hypoautofluorescence along the inferior temporal vascular arcade can be observed in OD (**A**) and OS (**B**). A subtle hyperautofluorescent band is also present. Bilateral, center-involving cystoid macular oedema is seen on the SD-OCT scans of OD (**C**) and OS (**D**). Loss of integrity of the outer retinal layers and the retinal pigment epithelium/Bruch membrane complex is present over the regionalized atrophy seen inferiorly on FAF.

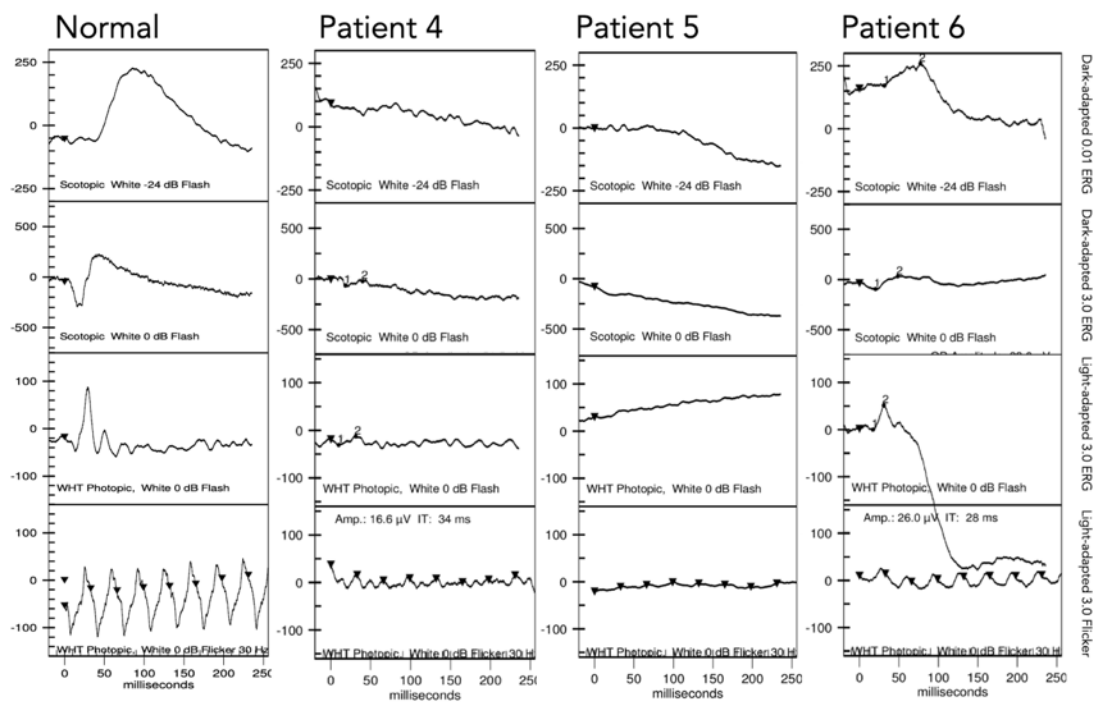
### ***Mutational spectrum***

Seven different disease-causing variants were identified across 12 alleles of 6 unrelated patients (Table 1). Four novel *EYS* variants are herein reported for the first time: 1 pathogenic, 1 likely pathogenic and 2 variants of uncertain significance (VUS) according to the ACMG classification. In the case of the latter 2 variants, family studies allowed reclassification of the variants as likely pathogenic. Detailed information of all variants is shown on Table 2. Except for the above reported *EYS* variants, no additional clinically significant variants (ACMG classes IV or V) were found in genes associated with inherited retinal dystrophies.

**Table 2.** Detailed description of the identified *EYS* variants

Variant <i>EYS</i> (NM_001142800.1)	Location	Variant type	gnomAD	ACMG classification	ACMG criteria	References
c.2225del p.(Cys742Leufs*36)	Exon 14	Frameshift	Variant not found	Likely Pathogenic	PVS1, PM2	Novel; Clinvar/HGMD: NA
c.5928-2A>G p.?	Intron 28	Splicing	0,0026% (exome)	Pathogenic	PVS1, PP5, PM2, PP3	PMID: 22164218, 27874104, 28704921
c.(2023+1_2024-1)_(2259+1_2260-1)del	Exon 13 and 14	Deletion	0,012% (genome)	Pathogenic	1A, 2B, 2E, 3A, 4O, 4L	PMID: 21519034
c.6794del p.(Pro2265fs)	Exon 34	Deletion	0,0275% (genome)	Pathogenic	PVS1, PM2, PM3, PP5	PMID: 29550188, 20333770 18836446, 25412400
c.2820_2824delTGGAA p.(Gly941Metfs*11)	Exon 18	Frameshift deletion	Variant not found	Pathogenic	PVS1, PM2, PP5	Novel; Clinvar/HGMD: NA
c.9122C>T p.(Ile304I Thr)	Exon 43	Missense	Variant not found	VUS	PM2, PP3	Novel; Clinvar/HGMD: NA
c.8897A>G p.(Gly2966Glu)	Exon 43	Missense	Variant not found	VUS	PM2, PP3	Novel; Clinvar/HGMD: NA

ACMG – American College of Medical Genetics and Genomics; VUS – variant of uncertain significance



**Supplemental Figure I** Full-field electroretinogram (ffERG) of Patients 4, 5 and 6. On patients 4 and 5, bilateral marginally recordable scotopic and photopic responses were recorded. Patient 6 presented a subnormal scotopic and photopic ffERG.

## DISCUSSION

The mutational spectrum of sector RP is evolving, with recent additions<sup>4,10</sup> to the list of associated genes. One of these genes is *EYS*, a frequent cause of autosomal-recessive retinal degeneration in Asian and European populations.<sup>16-19</sup> Phenotypic heterogeneity exists in *EYS*-related disease<sup>17,19,22-24</sup> but despite previous clinical descriptions compatible with a sectoral phenotype, the gene has only recently been listed in a publication reviewing the genomic landscape of sector RP.<sup>10</sup> In 2010, Audo et al<sup>17</sup> reported a case where distinct fundus abnormalities with predominance of pigmentary changes in the inferior retina were found in an Egyptian-descent patient with a homozygous deletion of exon 12: p.(Cys590TyrfsX4). Interestingly, ERG responses were not detectable for this patient, consistent with severe generalized rod-cone dysfunction, which is unusual for *RHO*-related sector RP. A similar phenotype was described by Muciullo et al<sup>24</sup> in an Italian patient with compound heterozygosity for the c.8133\_8137del p.(Phe2712Cysfs\*33) and c.9383\_9387del p.(Lys3128Argfs\*7) variants.

Here, recordable scotopic rod-specific B-waves were present in both eyes, which is more consistent to what has been described for *RHO*-related sector RP.<sup>28</sup> Additionally, Bandah-Rozenfeld et al<sup>29</sup> described a patient homozygous for the p.His2740TyrfsX27 variant in *EYS* that initially presented with sector RP at the age of 25 (based on funduscopy and visual field findings) and later progressed to widespread, generalized retinal involvement. Recently, Cundy et al<sup>30</sup> reported one asymptomatic patient with a phenotype consistent with inferior sector RP. The patient was homozygous for the c.5834delA variant. In a Japanese cohort of *EYS*-related retinal degeneration,<sup>19</sup> FAF imaging of a patient harbouring homozygous c.2528 G > A, p.(Gly843Glu) variants is also consistent with sector RP, even though this was not acknowledged by the authors. Two recent studies<sup>22,23</sup> highlighted the presence of crescent-shaped hyperAF changes in patients with *EYS*-related RP, advancing most from the temporal and inferior quadrants and whose edge encroached on the central macula. As expected, these patients had larger visual fields, longer ellipsoid zones on macular SD-OCT and, therefore, milder disease. It seems from these descriptions that sector RP is not an infrequent finding in association with disease-causing variants in *EYS*. However, the individual cases previously reported were either diluted in large *EYS* cohorts,<sup>17,24,29</sup> or given a different name,<sup>22,23</sup> thus losing visibility as a distinctive molecular cause for the sector RP phenotype. We are deeply convinced that *EYS* is a frequent cause of sector RP, thus meriting scientific awareness. We identified seven different disease-causing variants in 6 unrelated female patients. The female predominance in our cohort is unexpected but probably just fortuitous. Intriguingly, the case reported by Georgiou et al<sup>10</sup> was also of a female patient. Further studies are needed to clarify if there is a correlation between *EYS*-related sector RP and female sex.

Despite the small cohort, two variants were identified in 33% (4/12) and 25% (3/12) of the alleles: the c.5982-2A>G p.? and the c.2225del p.(Cys742Leufs\*36) variants, respectively. According to the literature and patient registries of the two centres, none of these variants is particularly frequent in Portuguese or Brazilian populations. The c.5982-2A>G p.? variant has been reported in association with retinitis pigmentosa across different populations,<sup>31,32</sup> including a Spanish cohort.<sup>33</sup> The c.2225del p.(Cys742Leufs\*36) variant is a frameshift variant leading to a premature stop codon and is not present in population databases (dbSNP and gnomAD). This variant has not been reported in the literature, but has been identified in Portuguese patients with *EYS*-related retinitis pigmentosa (CHUC cohort; unpublished data). The fact that all variants reported in our cohort have been identified in association with a typical RP phenotype highlight the interfamilial phenotypic heterogeneity associated with disease-causing variants in *EYS*. Furthermore, the fact that patient 3 has an affected sibling with a typical *EYS*-related RP phenotype, demonstrates the intrafamilial heterogeneity.

Our study shows that the phenotypic resemblances to *RHO*-related sector RP are evident, and physicians should keep in mind *EYS* as an important differential for this atypical presentation. Understanding the characteristics of mutant proteins and establishing genotype-phenotype correlations is not always an easy task. Sengillo et al<sup>23</sup> was able to correlate the presence of typical parafoveal hyperAF rings and atypical crescent-shaped hyperAF rings with variants in the distal portion, or C-terminal one-third of the *EYS* protein. The authors concluded that the position of the variant within the gene could explain disease severity among patients. This was not the case in our cohort, where only 3 out of 7 variants were located in the distal portion of the *EYS* protein.

Although the exact mechanisms involved in sector RP remain unidentified, the fact that intra- and interfamily phenotypic variability exists in the presence of the same mutations, suggests the influence of external factors.<sup>9</sup> Some evidence indicates that the direct action of incident light on rhodopsin (Rho) may trigger retinal degeneration, thus contributing to the observed sector phenotype.<sup>9</sup> In fact, a disease-exacerbating role for incident light has been proposed, based on a theoretical model showing that light exposure is greatest in the inferior retina.<sup>34</sup> The *EYS* protein is important for photoreceptor morphology but its precise function in photoreceptor biology is still unknown. It has been hypothesized that it could be involved in maintaining the stability of the ciliary axoneme in both rods and cones. Nevertheless, the variability of its isoform structure suggests that other roles are also possible and yet to be established.<sup>35</sup> Even though no accurate explanations exist, it can be speculated that *EYS* interacts or influences Rho expression as a genetic modifier, thus triggering the sectoral phenotype.<sup>17</sup>

There are limitations to this study. First, electrophysiology testing was only performed in patients 2, 4, 5 and 6 and was limited to the ffERG strategy. Given the pattern of retinal involvement associated with sector RP, it would be interesting to have multifocal ERG data, as recently described by Giambene et al.<sup>28</sup> Second, the small number of subjects and the study design preclude the establishment of genotype-phenotype correlations and evaluation of disease progression. Further genetic analyses of larger cohorts are needed to better understand the pathophysiology of *EYS*-related sector RP and longitudinal natural history studies with functional testing will be useful to understand if progression does exist in *EYS*-related sector RP. Nevertheless, by using multimodal imaging and functional testing, and providing a review of the current literature, this study provides robust evidence to establish *EYS* as a cause for the sector RP phenotype.

In conclusion, we have described here a phenotype of sector RP in 6 unrelated patients harbouring disease-causing mutations in *EYS*. Even though *EYS* has only recently been listed as a cause of the sector RP phenotype, we believe that this presentation is not infrequent and it should be considered an important differential for this distinctive phenotype.

## REFERENCES

1. Massof RW, Finkelstein D. Vision threshold profiles in sector retinitis pigmentosa. *Arch Ophthalmol* 1979;97(10):1899-904. DOI: 10.1001/archophth.1979.01020020347012.
2. Van Woerkom C, Ferrucci S. Sector retinitis pigmentosa. *Optometry* 2005;76(5):309-17. DOI: 10.1016/s1529-1839(05)70314-6.
3. Napier ML, Durga D, Wolsley CJ, et al. Mutational Analysis of the Rhodopsin Gene in Sector Retinitis Pigmentosa. *Ophthalmic Genet* 2015;36(3):239-43. DOI: 10.3109/13816810.2014.958862.
4. Coussa RG, Basali D, Maeda A, DeBenedictis M, Traboulsi EI. Sector retinitis pigmentosa: Report of ten cases and a review of the literature. *Mol Vis* 2019;25:869-889.
5. Xiao T, Xu K, Zhang X, Xie Y, Li Y. Sector Retinitis Pigmentosa caused by mutations of the RHO gene. *Eye (Lond)* 2019;33(4):592-599. DOI: 10.1038/s41433-018-0264-3.
6. Oliveira MA, Neves E, Marques JP. Genetic, Anatomical, and Functional Correlation of Sector Retinitis Pigmentosa. *JAMA Ophthalmol* 2020;138(6):e193133. DOI: 10.1001/jamaophthalmol.2019.3133.
7. Bisantis C. [G.B. Bietti's sectorial pigmentary retinopathy. Contribution to the knowledge of its various clinical aspects]. *Ann Ocul (Paris)* 1971;204(9):907-54.
8. Nguyen XT, Talib M, van Cauwenbergh C, et al. CLINICAL CHARACTERISTICS AND NATURAL HISTORY OF RHO-ASSOCIATED RETINITIS PIGMENTOSA: A Long-Term Follow-Up Study. *Retina* 2020. DOI: 10.1097/IAE.0000000000002808.
9. Ramon E, Cordomi A, Aguila M, et al. Differential light-induced responses in sectorial inherited retinal degeneration. *J Biol Chem* 2014;289(52):35918-28. DOI: 10.1074/jbc.M114.609958.
10. Georgiou M, Grewal PS, Narayan A, et al. Sector Retinitis Pigmentosa: Extending the Molecular Genetics Basis and Elucidating the Natural History. *Am J Ophthalmol* 2020. DOI: 10.1016/j.ajo.2020.08.004.
11. Saihan Z, Stabej Ple Q, Robson AG, et al. Mutations in the USH1C gene associated with sector retinitis pigmentosa and hearing loss. *Retina* 2011;31(8):1708-16. DOI: 10.1097/IAE.0b013e31820d3fd1.
12. Branson SV, McClintic JI, Stamper TH, Haldeman-Englert CR, John VJ. Sector Retinitis Pigmentosa Associated With Novel Compound Heterozygous Mutations of CDH23. *Ophthalmic Surg Lasers Imaging Retina* 2016;47(2):183-6. DOI: 10.3928/23258160-20160126-14.

13. Sato M, Oshika T, Kaji Y, Nose H. A novel homozygous Gly107Arg mutation in the RDH5 gene in a Japanese patient with fundus albipunctatus with sectorial retinitis pigmentosa. *Ophthalmic Res* 2004;36(1):43-50. DOI: 10.1159/000076109.
14. Nakamachi Y, Nakamura M, Fujii S, Yamamoto M, Okubo K. Oguchi disease with sectoral retinitis pigmentosa harboring adenine deletion at position 1147 in the arrestin gene. *Am J Ophthalmol* 1998;125(2):249-51. DOI: 10.1016/s0002-9394(99)80100-7.
15. Pappalardo J, Heath Jeffery RC, Thompson JA, et al. Progressive sector retinitis pigmentosa due to c.440G>T mutation in SAG in an Australian family. *Ophthalmic Genet* 2020;1-9. DOI: 10.1080/13816810.2020.1832533.
16. Arai Y, Maeda A, Hiramami Y, et al. Retinitis Pigmentosa with EYS Mutations Is the Most Prevalent Inherited Retinal Dystrophy in Japanese Populations. *J Ophthalmol* 2015;2015:819760. DOI: 10.1155/2015/819760.
17. Audo I, Sahel JA, Mohand-Said S, et al. EYS is a major gene for rod-cone dystrophies in France. *Hum Mutat* 2010;31(5):E1406-35. DOI: 10.1002/humu.21249.
18. Barragan I, Borrego S, Pieras JI, et al. Mutation spectrum of EYS in Spanish patients with autosomal recessive retinitis pigmentosa. *Hum Mutat* 2010;31(11):E1772-800. DOI: 10.1002/humu.21334.
19. Yang L, Fujinami K, Ueno S, et al. Genetic Spectrum of EYS-associated Retinal Disease in a Large Japanese Cohort: Identification of Disease-associated Variants with Relatively High Allele Frequency. *Sci Rep* 2020;10(1):5497. DOI: 10.1038/s41598-020-62119-3.
20. Abd El-Aziz MM, Barragan I, O'Driscoll CA, et al. EYS, encoding an ortholog of *Drosophila* spacemaker, is mutated in autosomal recessive retinitis pigmentosa. *Nat Genet* 2008;40(11):1285-7. DOI: 10.1038/ng.241.
21. Collin RW, Littink KW, Klevering BJ, et al. Identification of a 2 Mb human ortholog of *Drosophila* eyes shut/spacemaker that is mutated in patients with retinitis pigmentosa. *Am J Hum Genet* 2008;83(5):594-603. DOI: 10.1016/j.ajhg.2008.10.014.
22. Pierrache LHM, Messchaert M, Thiadens A, et al. Extending the Spectrum of EYS-Associated Retinal Disease to Macular Dystrophy. *Invest Ophthalmol Vis Sci* 2019;60(6):2049-2063. DOI: 10.1167/iovs.18-25531.
23. Sengillo JD, Lee W, Nagasaki T, et al. A Distinct Phenotype of Eyes Shut Homolog (EYS)-Retinitis Pigmentosa Is Associated With Variants Near the C-Terminus. *Am J Ophthalmol* 2018;190:99-112. DOI: 10.1016/j.ajo.2018.03.008.
24. Mucciolo DP, Sodi A, Passerini I, et al. Fundus phenotype in retinitis pigmentosa associated with EYS mutations. *Ophthalmic Genet* 2018;39(5):589-602. DOI: 10.1080/13816810.2018.1509351.



25. Marques JP, Carvalho AL, Henriques J, Murta JN, Saraiva J, Silva R. Design, development and deployment of a web-based interoperable registry for inherited retinal dystrophies in Portugal: the IRD-PT. *Orphanet J Rare Dis* 2020;15(1):304. DOI: 10.1186/s13023-020-01591-6.
26. McCulloch DL, Marmor MF, Brigell MG, et al. ISCEV Standard for full-field clinical electroretinography (2015 update). *Doc Ophthalmol* 2015;130(1):1-12. DOI: 10.1007/s10633-014-9473-7.
27. Porto FBO, Jones EM, Branch J, et al. Molecular Screening of 43 Brazilian Families Diagnosed with Leber Congenital Amaurosis or Early-Onset Severe Retinal Dystrophy. *Genes (Basel)* 2017;8(12). DOI: 10.3390/genes8120355.
28. Giambene B, Verdina T, Pennino M, Fabbrucci M, Cavallini GM, Menchini U. Multifocal electroretinographic responses in sector retinitis pigmentosa. *Int Ophthalmol* 2020;40(3):703-708. DOI: 10.1007/s10792-019-01231-4.
29. Bandah-Rozenfeld D, Littink KW, Ben-Yosef T, et al. Novel null mutations in the EYS gene are a frequent cause of autosomal recessive retinitis pigmentosa in the Israeli population. *Invest Ophthalmol Vis Sci* 2010;51(9):4387-94. DOI: 10.1167/iovs.09-4732.
30. Cundy O, Broadgate S, Halford S, et al. "Genetic and clinical findings in an ethnically diverse retinitis pigmentosa cohort associated with pathogenic variants in EYS". *Eye (Lond)* 2020. DOI: 10.1038/s41433-020-1105-8.
31. McGuigan DB, Heon E, Cideciyan AV, et al. EYS Mutations Causing Autosomal Recessive Retinitis Pigmentosa: Changes of Retinal Structure and Function with Disease Progression. *Genes (Basel)* 2017;8(7). DOI: 10.3390/genes8070178.
32. Habibi I, Chebil A, Falfoul Y, et al. Identifying mutations in Tunisian families with retinal dystrophy. *Sci Rep* 2016;6(1):37455. DOI: 10.1038/srep37455.
33. Gonzalez-del Pozo M, Borrego S, Barragan I, et al. Mutation screening of multiple genes in Spanish patients with autosomal recessive retinitis pigmentosa by targeted resequencing. *PLoS One* 2011;6(12):e27894. DOI: 10.1371/journal.pone.0027894.
34. Schwartz L, Boelle PY, D'Hermies F, Ledanois G, Virmont J. Blue light dose distribution and retinitis pigmentosa visual field defects: an hypothesis. *Med Hypotheses* 2003;60(5):644-9. DOI: 10.1016/s0306-9877(02)00391-2.
35. Alfano G, Kruczek PM, Shah AZ, et al. EYS Is a Protein Associated with the Ciliary Axoneme in Rods and Cones. *PLoS One* 2016;11(11):e0166397. DOI: 10.1371/journal.pone.0166397.



Manuscript 9

**3.3. Eyes Shut Homolog-Associated Retinal Degeneration: Natural History, Genetic Landscape, and Phenotypic Spectrum**

Ricardo Machado Soares

Ana Luísa Carvalho

Sílvia Simão

Célia Azevedo Soares

Celso Henrique Alves

António Francisco Ambrósio

Joaquim Murta

Jorge Saraiva

Rufino Silva

João Pedro Marques

*Published in: Ophthalmol Retina. 2023 Feb 9;S2468-6530(23)00054-4. Online ahead of print.*

## ABSTRACT

**Purpose:** To describe the natural history, genetic landscape and phenotypic spectrum of *EYS*-associated retinal degeneration (*EYS*-RD)

**Design:** Retrospective cohort study complemented by a cross-sectional examination.

**Methods:** Single-center study conducted at an inherited retinal degeneration (IRD) referral center in Portugal. Patients with biallelic *EYS* variants were invited to participate. Every patient underwent a cross-sectional examination comprising a comprehensive ophthalmologic examination including best-corrected visual acuity (BCVA), dilated slit-lamp anterior segment and fundus biomicroscopy; ultra-widefield (UWF) color fundus photography (UWF-CFP) and fundus autofluorescence (UWF-FAF) imaging; and spectral-domain optical coherence tomography (SD-OCT). Additional information was collected from the patient file. Main outcome measures included clinical/demographic, genetic, and multimodal imaging data. BCVA variation during follow-up was used as an endpoint to describe *EYS*-RD natural history.

**Results:** Fifty-eight patients (59% males; mean age  $52 \pm 14$  years) from 48 Caucasian families of Portuguese ancestry were included. Twenty distinct *EYS* variants were identified, eight of which are novel. In 32.8% patients, onset of symptoms was in early adulthood (21-30 years). On UWF imaging, 75.0% patients ( $n=41$ ) were graded as typical, while 25.0% were atypical. Overall, a negative correlation was found between age and BCVA ( $r=-0.50$ ;  $p<0.001$ ), with an average loss of 1.45 letters per year of follow-up. Higher BCVA and larger ellipsoid zone (EZ) widths were found in atypical cases (both  $p<0.001$ ).

**Conclusions:** This study expands the genetic spectrum of *EYS*-RD by reporting 8 novel variants. A high frequency of atypical phenotypes was identified. These patients have better BCVA and larger EZ widths, thus presenting an overall better prognosis.

## INTRODUCTION

First described in 1853 by Dr. van Trigt<sup>1</sup>, retinitis pigmentosa (RP, OMIM #268000) is the most common inherited retinal disease (IRD), with an estimated worldwide prevalence of 1:4000<sup>2</sup>.

Eyes shut homolog (*EYS*, MIM \*612424) is the human ortholog of *Drosophila melanogaster* "eyes shut" protein and was first associated with autosomal recessive RP (arRP) in 2008<sup>3,4</sup>. Located on chromosome 6p12 (RP25 locus), with 44 exons spanning over 2 Mb of genomic DNA, *EYS* is the largest gene expressed in the retina. It encodes four protein isoforms, with its canonical isoform 4 coding for 3165 amino acids, harboring 27 epidermal growth factor-like domains and five laminin G-like domains<sup>3-6</sup>. Although the concrete function of these isoforms is uncertain, it is suggested that *EYS* protein plays an essential role in retinal morphogenesis, architecture, and ciliary transport<sup>5,6</sup>.

Due to its worldwide prevalence<sup>7-9</sup>, biallelic *EYS* deleterious variants are an important cause of retinal degeneration (*EYS*-RD). Even though initial reports have claimed *EYS* is associated with a relatively homogeneous and slowly progressive form of RP, recent studies have highlighted its high genetic, phenotypic, and clinical heterogeneity<sup>10-15</sup>. Nevertheless, data from large cohorts detailing genetic-phenotypic traits and clinical characteristics of *EYS*-RD are currently scarce<sup>10,12,16,17</sup>. Given the lack of a representative rodent model and the high worldwide prevalence of deleterious variants in this gene, evidence from natural history studies is paramount to provide targeted patient care and establish an accurate disease-related prognosis<sup>5,12</sup>. In light of this, the purpose of this study was to describe the natural history, genetic landscape and phenotypic spectrum in a large Portuguese cohort of *EYS*-RD patients.

## METHODS

### ***Study design and diagnostic criteria***

Single-center, retrospective cohort study complemented by a cross-sectional examination. The study was conducted at the Ophthalmology and Medical Genetics Units of Centro Hospitalar e Universitário de Coimbra (CHUC), Portugal's largest IRD referral center. Patients with biallelic variants in the *EYS* gene were identified using the IRD-PT registry<sup>18</sup>. Every patient provided written informed consent. The study was approved by CHUC's ethics committee and complied with the tenets of the Declaration of Helsinki for biomedical research.

### ***Clinical/demographic features and main outcome measures***

Baseline demographics (age, gender, ethnicity), age at onset of symptoms, family history, history of consanguinity, symptoms, age at diagnosis, best-corrected visual acuity (BCVA, ETDRS letters) at baseline and throughout follow-up, and follow-up time were collected from each

patient's medical records. Ascribing to the possible effect of recall bias, age at onset of symptoms was categorized into a timeframe: childhood (6-10 years); adolescence (11-20 years); early adulthood (21-30 years); adulthood (31-50 years); and elderly (>51 years).

Main outcome measures included clinical/demographic, genetic, and multimodal imaging data. BCVA variation during follow-up was used as an endpoint to describe EYS-RD natural history. BCVA of eyes with coexisting conditions that were not inherent to the natural history of the disease were excluded from the analysis.

### ***Ophthalmic examination, functional testing, and multimodal imaging***

Every patient underwent a cross-sectional examination comprising of the following: (1) a comprehensive ophthalmologic examination including BCVA, dilated slit-lamp anterior segment, and fundus biomicroscopy performed by a single IRD specialist (J.P.M.); (2) ultra-widefield (UWF) color fundus photography (UWF-CFP) and fundus autofluorescence (UWF-FAF) imaging (Optos California, Optos GmbH, Germany); and (3) spectral-domain optical coherence tomography (SD-OCT, Spectralis, Heidelberg Engineering, Heidelberg, Germany). UWF-CFP were evaluated for symmetry; presence, amount (absent/scarce, moderate, or dense), and distribution (number of quadrants) of bone spicule hyperpigmentation; vessel thinning; optic nerve head (ONH) pallor; and presence and location of chorioretinal atrophy. Features analyzed and collected from UW-FAF included presence/absence, shape (regular/concentric or irregular/arc) of the hyperautofluorescent (hyperAF) parafoveal ring, presence/absence of central hyperAF, and presence/absence of macular, mid-peripheral and peripheral hypoautofluorescence (hypoAF).

All eyes were blindly graded (irrespective of patient name, genetic testing results, or visual acuity) as typical or atypical RP, according to the conjunction of findings on multimodal imaging by two independent medical graders (J.P.M. and R.M.S.). Disagreement was resolved by open adjudication. Typical RP was considered in cases with an overall bilateral and symmetrical presentation, marked by bone spicule pigmentation in the mid/far periphery, narrowing and attenuation of retinal vessels, and waxy pallor of the ONH<sup>2,19</sup>. On UW-FAF, cases classified as typical RP presented bilateral and symmetrical parafoveal hyperAF rings, central hyperAF without a parafoveal hyperAF ring, or central hypoAF (macular atrophy), and the presence of hypoAF lesions surrounding the macula (retinal pigment epithelium and outer retinal atrophy)<sup>2,19</sup>. Eyes were graded as atypical RP in the setting of (1) unilateral/asymmetrical presentation; (2) presence of regionalized areas of bone spicule pigmentation sparring one or more quadrants of the retina on UW-FAF imaging; and (3) crescent-shaped macular atrophy with an hyperAF arc/band.

SD-OCT was used to evaluate the status of the outer retinal layers in the central 3 millimeters. A blinded grader (S.S.) measured the EZ width in the superior, inferior, nasal and temporal macular quadrants according to a predefined protocol<sup>20</sup>.

### **Genetic Testing**

Prior to genetic testing, all probands had a clinical diagnosis of IRD based on history and compatible structural and functional retinal changes. Genetic testing and pre-test genetic counseling was coordinated by a medical geneticist from the Medical Genetics Unit of CHUC. Peripheral blood samples were collected, and genomic DNA was isolated using a DNA extraction and purification kit based on the manufacturer's protocol. A next-generation sequencing (NGS) approach was used, comprising whole-exome sequencing (WES) or WES-based NGS panels, complemented by multiplex ligation-dependent probe amplification (MLPA) when deemed necessary. Variants were classified according to the American College of Medical Genetics and Genomics (ACMG)<sup>21</sup>. All variants classified as pathogenic (class V) or likely pathogenic (class IV) were further confirmed by Sanger sequencing. Whenever possible, segregation analysis was performed on family members. Published cDNA sequence for *EYS* (GenBank NM\_001142800.2) was compared with the sequencing results. Genetic counseling provided by a medical geneticist was granted to all subjects.

### **Genotype classification**

Similarly to other studies<sup>22,23</sup>, patients were divided into three genotype groups according to the severity of the bi-allelic variants identified: genotype A (severe):  $\geq 2$  severe/null variants; genotype B: one severe/null variant and one variant that is missense or in-frame insertion/deletion; or genotype C: patients with no severe/null variant, but  $\geq 2$  variants that are missense or in-frame insertion/deletion. Null variants were defined as those predicted to affect splicing or introduce a premature truncating codon in the protein, such as nonsense, frameshift, exonic, or intronic variants with significant splice-site alteration.

### **Statistical Analysis**

Statistical analysis was conducted using SPSS statistical software (IBM SPSS statistics package version 28, Armonk, NY, USA). For descriptive purposes of the study sample, counts and proportions were presented. The Shapiro-Wilk test was performed to evaluate the normality of the distributions. Symmetrical variables were described using means and standard deviation, and non-symmetrical distributions were described using median and interquartile range. Comparisons between independent variables were performed using Mann-Whitney U, ANOVA and Kruskal-Wallis tests. Categorical variables were compared by using Fisher's exact

test. Pearson's and Spearman's bivariate correlation tests were performed to study linear correlations. Linear regression analysis was used to model the relationship between two continuous variables. For BCVA and ellipsoid zone (EZ) width analysis, one eye was randomly selected using a random number sequence generator. Resulting p-values were adjusted using Bonferroni and Dunn corrections based on the number of comparisons in each analysis. Significance level was set at  $\alpha=0.05$ .

## RESULTS

### **Clinical/demographic data**

A total of 58 patients (59% males) from 48 Caucasian families of Portuguese ancestry were included. The mean age of the included patients was  $52 \pm 14$  years (range from 23 to 86), with a mean age at diagnosis of  $43 \pm 13$  years. The onset of symptoms was most frequent in early adulthood (21-30 years) – 32.8% (n=19 patients), followed by adolescence (11-20 years) – 29.3% (n=17), childhood (6-10 years) – 22.4% (n=13), and adulthood (30-50 years) – 10.3% (n=6). Only one patient (1.7%) presented symptoms onset after 51 years of age, and two patients (3.4%) did not report symptoms at the time of examination. Almost every patient reported nyctalopia (94.8%) and visual field constriction (91.4%). Family history of RP was present in 57% of patients (n=33; 22 families), and history of consanguinity in 22% of patients (n=13; 9 families). Demographic and clinical data stratification is represented in Table 1.

**Table 1.** Demographic and clinical characteristics of the cohort

<b>Number of families (N)</b>	48
<b>Number of patients (N)</b>	58
<b>Sex (number, %)</b>	
Male	34 (51.6)
Female	24 (41.4)
<b>Age, years (mean <math>\pm</math> SD)</b>	51.6 (14.1)
<b>Age of onset of symptoms (number, %)</b>	
Childhood (6-10 years)	13 (22.4)
Adolescence (11-20 years)	17 (29.3)
Early adulthood (21-30 years)	19 (32.8)
Adulthood (30-50 years)	6 (10.3)
Elderly (>51 years)	1 (1.7)
No symptoms	2 (3.4)
<b>Age diagnosis, years (mean <math>\pm</math> SD)</b>	43.3 (13.3)



<b>Follow-up, years (median, IQR 25-75)</b>	4.1	(2.2-13.9)
<b>Family History (number, %)</b>	33	(56.9)
<b>Consanguinity (number, %)</b>	13	(22.4)
<b>Symptoms (number, %)</b>		
Nyctalopia	55	(94.8)
VF constriction	53	(91.4)
<b>BCVA, ETDRS letters (median, IQR)</b>	66	(21)
<b>EYS phenotype (number, %)</b>		
Typical RP	40	(68.9)
Atypical RP	15	(25.9)
Cone-rod dystrophy	1	(1.7)
<b>Genotype (number, %)</b>		
A	47	(81.0)
B	9	(15.5)
C	2	(3.5)

BCVA - best-corrected visual acuity; ETDRS - Early Treatment Diabetic Retinopathy Study; IQR - interquartile range; RP - retinitis pigmentosa; SD - standard deviation; VF - visual field

### **EYS variants and genetic analysis**

Twenty distinct variants (Fig. I A, B) were identified in the cohort, eight of which were novel. A detailed analysis of EYS variants identified in the cohort and the pathogenicity of each variant assessed with predictive programs are summarized in Table 2. According to the ACMG classification<sup>21</sup>, five variants were pathogenic, thirteen likely pathogenic, and two variants were of uncertain significance. Concerning variant type, most patients (47%; n=54) had copy number variation (CNV) deletions, followed by splicing (18%; n=21) and nonsense variants (16%; n=19). Missense, frameshift and CNV duplication variants were less prevalent in the cohort (Fig. I C).

The c.(2023+1\_2024-1)\_(2259+1\_2260-1)del was the most prevalent CNV deletion with an allele frequency (AF) of 37.9% (n=44), followed by the splicing c.5928-2A>G (AF=16.4%; n=19) and nonsense c.4120C>T (p.Arg1374Ter) (AF=12.9%; n=21) variants. Of 58 patients, 30 carried homozygous variants (of which 12 reported a history of consanguinity), and 28 carried compound heterozygous variants. Regarding genotype classification, 47 patients (81%) had a type A (severe) genotype, followed by 9 patients with genotype B and 2 with C.



**Table 2.** Detailed analysis of *EYS* variants (NM\_001142800.2) in chromosome 6q12 in the cohort

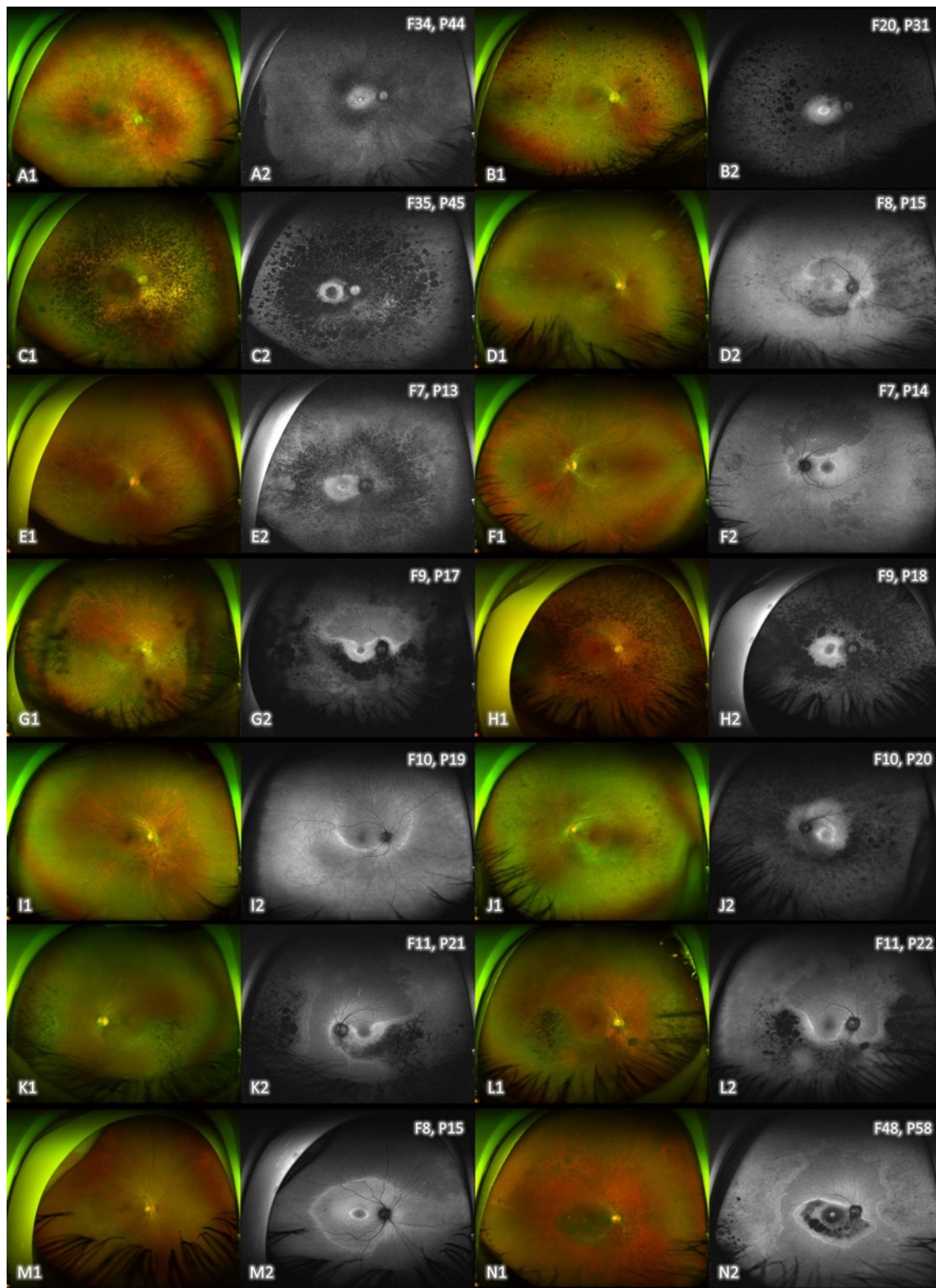
dbSNP	GRCh38	Nucleotide Change	Location	Protein Variant	Variant Type	Predicted Effect	Count in Cohort	Hom	Het	GnomAD Total	ACMG criteria	ACMG classification	ClinVar Significance	First report
	66 111 964-66 200 486	c.(862+1_863-1)(1056+1_1184+407)del	Exon 6 and 7	p.?	CNV Deletion	Null	1		1	N/A	1A, 2A, 2E, 3A	Likely pathogenic	N/A	This study
rs1562140604	66094271-66094274	c.1299+5_1299+8del	Intron 8	p.?	Splicing	Suspected to be null	1		1	0,000007	PM2, PM4	Likely pathogenic	Conflicting (560456)	PMID: 29159838
	65,655,808-66,005,755	c.(2023+1_2024-1)(2259+1_2260-1)del	Exon 13 and 14	p.?	CNV Deletion	Null	44	15	14	0,000012%	1A, 2A, 2E, 3A, 4O, 4L	Pathogenic	N/A	PMID: 21519034
rs45628235	65707508	c.2225del	Exon 14	p.Cys742Leufs*36	Frameshift indel	Null	6	2	2	N/A	PVSI, PM2	Likely pathogenic	N/A	PMID: 34568954
	65622637-65767506	c.(2137+1_2138-1)(2381+1_2382-1)del	Exon 14 and 15	o.?	CNV Deletion	Null	3	1	1	0,000012%	1A, 2A, 2E, 3A, 4O, 4L	Pathogenic	N/A	This study
rs371032798	65655687	c.2380C>T	Exon 15	p.Arg794*	Nonsense	Null	2		2	0.000007% (exome)	PVSI, PMM2, PP5	Pathogenic	Pathogenic (650440)	PMID: 18836446
	65531535	c.3243+2dup	Intron 21	p.?	Splicing	Null	1		1	N/A	PVSI, PM2	Likely pathogenic	N/A	This study
rs1205803331	65301656	c.4103dup	Exon 26	p.Ser1369ilefs*18	Frameshift indel	Null	1		1	0,000007% (genome)	PVSI, PM2	Likely pathogenic	N/A	This study
rs928803207	65301640	c.4120C>T	Exon 26	p.Arg1374*	Nonsense	Null	15	4	7	0.000016% (aggregated)	PVSI, PM2, PP5	Pathogenic	Pathogenic (802236)	PMID: 18836446
rs181169439	65098735	c.5928-2A>G	Intron 28	p.?	Splicing	Null	19	5	9	0.000026% (exome)	PS4, PVSI, PM2, PP5	Pathogenic	Pathogenic (438200)	PMID: 18836446
	65016976-65146066	c.(5927+1_5928-1)(6078+1_6079-1)del	Exon 29	p.?	CNV Deletion	Null	1		1	N/A	1A, 2A, 2E, 3A	Likely Pathogenic	N/A	PMID: 27208209
	64709077-64940484	c.(6424+1_6425-1)(6725+1_6726-1)del	Exon 32 and 33	p.?	CNV Deletion	Null	5	1	3	N/A	1A, 2A, 2E, 3A	Likely pathogenic	N/A	PMID: 20333770
	64574252-64940484	c.(6424+1_6425-1)(7055+1_7056-1)dup	Exon 32 to 35	p.?	CNV Duplication	Null	1		1	N/A	1A, 2I, 2K, 2L, 3A, 4N, 5D	Likely pathogenic	N/A	This study
	64574079	c.7228G>A	Exon 36	p.Ala2410Thr	Missense	Missense	2		2	N/A	PM2, PM5, PP3	Likely pathogenic	N/A	This study
rs985211023	64472422	c.8003G>T	Exon 41	p.Cys2668Phe	Missense	Missense	1		1	0.000064% (aggregated)	PM2, PM3	Likely pathogenic	VUS (598124)	PMID: 22164218
rs373203896	64431148	c.8779T>C	Exon 43	p.Cys2927Arg	Missense	Missense	5	2	1	0.000038% (exome)	PM2, PP3, PP5	Likely pathogenic	Likely pathogenic/Pathogenic (624249)	PMID: 30718709
rs1161453292	64431093	c.8834G>A	Exon 43	p.Gly2945Glu	Missense	Missense	1		1	0.000016% (aggregated)	PM2, PP3	VUS	Conflicting interpretations (836062)	PMID: 21069908
	64430741	c.9182_9185del	Exon 43	p.Asn3061Thrfs*3	Frameshift indel	Null	3		3	N/A	PVSI, PM2	Likely pathogenic	N/A	This study
	64430590	c.9337A>T	Exon 43	p.Lys3113*	Nonsense	Null	2		2	N/A	PVSI, PM2	Likely pathogenic	N/A	This Study
rs772888249	64430535	c.9392G>C	Exon 43	p.Gly3131Ala	Missense	Missense	1		1	0.00006% (exome)	PM2	VUS	Conflicting interpretations (444685)	PMID: 32531858

ACMG - American College of Medical Genetics; CNV - Copy Number Variation; dbSNP - Single Nucleotide Polymorphism Database; Het - Heterozygous; Hom - Homozygous; VUS - Variant of uncertain significance

**Table 3.** Phenotypical data and analysis of EYS-RP patients

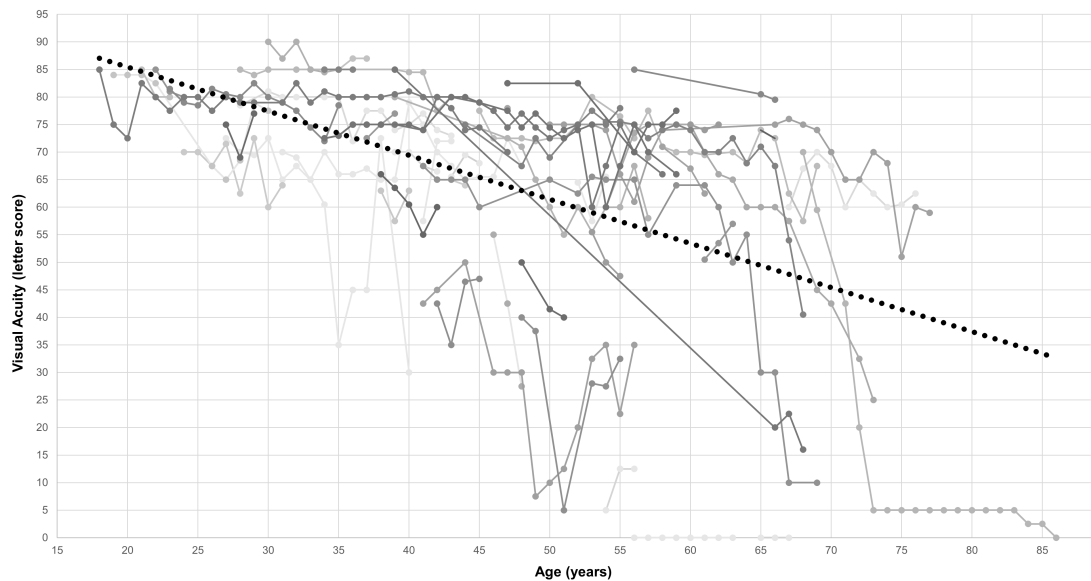
	Typical (N=41)	RP	Atypical (N=14)	RP	p value
<b>Sex (number, %)</b>					0.547
Male	22 (53.7)		9 (64.3)		
Female	19 (46.3)		5 (35.7)		
<b>Age, years (mean ± SD)</b>	52.15 (14.8)		51.36 (13.2)		0.861
<b>Age at diagnosis, years (mean ± SD)</b>	42.27 (13.72)		47.43 (12.43)		0.219
<b>BCVA, ETDRS letters (median, IQR)</b>	65 (22)		79 (13)		<0.001
<b>Follow-up, years (median, IQR 25-75)</b>	7.3 (2.3-17.5)		3.2 (1.5-6.2)		0.072
<b>Age of onset of symptoms (number, %)</b>					0.057
Childhood (6-10 years)	11 (26.8)		2 (14.3)		
Adolescence (11-20 years)	13 (31.7)		2 (14.3)		
Early adulthood (21-30 years)	14 (34.2)		5 (35.7)		
Adulthood (30-50 years)	3 (7.3)		2 (14.3)		
Elderly (>51 years)	0 (0.0)		1 (7.1)		
No Symptoms	0 (0.0)		2 (14.3)		
<b>Color fundus photography</b>					
<b>Amount of pigmentation (number, %)</b>					0.019
Absent/ scarce	15 (36.6)		7 (50.0)		
Moderate	12 (29.3)		7 (50.0)		
Dense	14 (34.1)		0 (0.0)		
<b>Number of quadrants (number, %)</b>					<0.001
0	0 (0.0)		3 (21.4)		
1	3 (7.3)		1 (7.1)		
2	5 (12.2)		6 (42.9)		
3	1 (2.4)		2 (14.3)		
4	32 (78.1)		2 (14.3)		
<b>Autofluorescence fundus images</b>					
<b>Subclassification of phenotype (number, %)</b>					
Parafoveal hyperAF ring	21 (51.2)				
Central hyperAF	12 (29.3)				
Central hypoAF (macular atrophy)	8 (19.5)				
Complete/incomplete		parafoveal		hyperAF	
Ring/arc with superior mid-periphery sparing			13 (92.9)		
Double hyperAFL ring			1 (7.1)		
<b>EZ width, μm (median, IQR)</b>					
Superior	491 (674)		4905 (3637)		<0.001
Inferior	407 (672)		791 (1360)		<0.001
Nasal	564 (645)		1417 (2736)		<0.001
Temporal	509 (692)		1070 (1809)		<0.001
<b>Genotype (number, %)</b>					1.000
A	33 (80.5)		12 (85.7)		
B	6 (14.6)		2 (14.3)		
C	2 (4.9)		0		

BCVA - best-corrected visual acuity; ETDRS - Early Treatment Diabetic Retinopathy Study; EZ - ellipsoidal zone; HiperAF - hiperautofluorescence; HypoAF - hypofluorescence; IQR - interquartile range; RP - retinitis pigmentosa; SD - standard deviation



**Figure 2.** Ultra-widefield color fundus photography (1) and ultra-widefield fundus autofluorescence (2) of 14 patients with EYS-RD. Patient's (P) number and family (F) number are displayed on the top right corner. Note the high degree of intrafamilial and interfamilial heterogeneity; **A-C** Typical retinitis pigmentosa (RP) with scarce, moderate and dense quadrant pigmentation, respectively. Additionally, note the three patterns of typical RP autofluorescence: complete hyperautofluorescent (hyperAF) ring (**B**), central hyperAF (**A**) and macular atrophy

(C); D Atypical RP with an incomplete parafoveal hyperAF arc and mid-peripheral superior sparring; E-L High degree of clinical heterogeneity among members of 4 different families (F7, F9, F10 and F11). E, H and J are examples of typical RP, while F, G, I, K and L represent cases of atypical RP with a complete/incomplete parafoveal hyperAF ring/arc and mid-peripheral superior sparring; M a case of atypical RP with a double hyperAF ring; N The only patient presenting with a cone-rod dystrophy phenotype.



**Figure 3.** Linear tendency curve estimated out of the patient's BCVA over time. An evident decline over time is noted.

#### *Ultrawidefield Color Fundus Photography*

The density and number of quadrants with bone spicule pigmentation were significantly higher in typical RP than in atypical RP retinas ( $p=0.019$  and  $p<0.001$ , respectively). Most patients with typical RP had pigmentation in all quadrants, and of these, most retinas were moderately or densely pigmented (Fig. 2 A-C). Of note, age was a significant factor in pigment quantity, as densely pigmented retinas were more prevalent in older patients (mean  $65.21 \pm 11.48$  years) compared to scarcely (mean  $44.43 \pm 10.83$  years;  $p<0.001$ ) and moderately (mean  $50.79 \pm 13.08$  years;  $p=0.003$ ) pigmented retinas. No differences in age were found between absent/scarcely and moderate groups or between number of pigmented quadrants ( $p>0.05$ ).

#### *Ultrawidefield Fundus Autofluorescence*

UW-FAF fundus phenotypes were subclassified into different categories according to typical/atypical findings. A high degree of intrafamilial and interfamilial heterogeneity was

observed (Fig. 2 E-L). In typical RP, every eye had mid-peripheral hypoAF in all quadrants. A hyperAF parafoveal ring was identified in 51.2% of patients (n=21). In patients whose ring was absent, 29.3% (n=12) had central macular hyperAF and 19.5% (n=8) central hypoAF (macular atrophy). Age was correlated with the subclassification patterns of typical RP ( $r=0.422$ ;  $p=0.006$ ), with the macular atrophy phenotype being more prevalent in older patients (mean  $65.63 \pm 12.69$  years) compared to hyperAF ring phenotype (mean  $47.14 \pm 13.20$  years) ( $p < 0.006$ ). No differences were found comparing central hyperAF (mean  $51.92 \pm 14.16$  years) phenotype with other groups ( $p > 0.05$ ).

Most atypical RP patients presented a complete/incomplete parafoveal hyperAF ring/arc together with inferior crescent-shaped macular atrophy with superior mid-peripheral retinal sparing (92.9% of patients, n=13) (Fig. 2 D, F, G, I, K, L). Another atypical phenotype was observed in one patient - double hyperAF ring (previously described by our group) (Fig. 2 M)<sup>24</sup>. Despite the older age in the atypical group ( $51.36 \pm 13.22$  years), no significant difference was found between atypical RP and typical RP hyperAF ring phenotype ( $p=0.362$ ).

We only identified one patient with a phenotype compatible with CORD (Fig. 2 N).

#### *Spectral-domain OCT*

EZ width measurements were possible in 40 typical and 14 atypical RP patients (Table 3). In typical RP, no differences were found between quadrants in EZ width ( $p=0.558$ ). On the other hand, in patients with atypical RP presenting the inferior crescent-shaped macular atrophy phenotype, superior EZ width [median 4905 (3637)  $\mu\text{m}$ ] was significantly longer compared to inferior EZ [median 791 (1360)  $\mu\text{m}$ ] width ( $p=0.018$ ). No other differences were found between quadrants ( $p > 0.05$ ). Additionally, average EZ width in atypical cases was significantly larger than in typical cases ( $p < 0.001$ ) in every quadrant.

### **Genotype-phenotype-clinical correlations**

#### *Best-corrected visual acuity*

BCVA data was available for every patient (116 eyes). Seven eyes were excluded due to secondary ophthalmologic diseases that were not inherent to RP natural history (i.e. optic neuropathy, ocular trauma, amblyopia). Measured BCVAs ranged from 0 (light perception) to 85 ETDRS letters, and the median BCVA of the cohort in the cross-sectional visit was 66 (21) letters. When stratifying for groups, patients with atypical RP had a significantly better BCVA [median 79 (13) letters] at examination than patients with typical RP [median 65 (22) letters] ( $p < 0.001$ ) (Table 3).

A negative correlation was found between age and BCVA, with older age being associated with poorer BCVA ( $r=-0.50$ ;  $p<0.001$ ). Moreover, a negative BCVA variation was correlated with longer follow-up time ( $r=-0.64$ ;  $p<0.001$ ). Linear regression was performed to predict BCVA variation based on the follow-up time (disease duration), showing an average loss of 1.45 letters per year of follow-up [ $F(1,55)=48.698$ ;  $R^2=0.470$ ;  $p<0.001$ ; 95% IC (-1.87, -1.03)]. When stratifying for UWF-FAF phenotypes, typical RP patients followed the same correlation, with older patients presenting poorer BCVA ( $r=-0.70$ ;  $p<0.001$ ). Longer follow-up time was also associated to a negative BCVA variation ( $r=-0.68$ ;  $p<0.001$ ), with an expected loss of 1.51 letters per year of follow-up [ $F(1,39)=32.934$ ;  $R^2=0.458$ ;  $p<0.001$ ; 95% IC (-2.04, -0.98)]. For atypical RP, no correlation was established between age and BCVA ( $r=-0.04$ ;  $p=0.904$ ) nor follow-up time-BCVA variation ( $r=-0.464$ ;  $p=0.111$ ). Contrastingly, a significant regression was found with a loss of 0.73 letters per year of follow-up [ $F(1,11)=8.686$ ;  $R^2=0.441$ ;  $p=0.013$ ; 95% IC (-1.28, -0.19)]. A curve of the natural clinical course of BCVA of the EYS-RD spectrum is represented in Figure 3.

#### *Genotype-phenotype correlations*

In typical RP, 21 patients presented at least one deleterious variant in one allele greater than GRch37 6:65300137 (c.5617C)<sup>14</sup>, while the other 20 patients did not. In atypical RP, seven patients presented at least one mutation in one allele greater than GRch37 6:65300137, and the other seven did not present any mutation near the C-terminus region. This difference between phenotypes was not statistically significant ( $p=1.000$ ). No other differences were found between variants or genotype classification and phenotypes.

## **DISCUSSION**

According to the Global Retinal Inherited Disease (GRID) dataset, the worldwide frequency of EYS-RD is 4.4%, making EYS the third most frequently mutated gene in IRDs, lagging only behind ABCA4 (24.8%) and USH2A (14.6%)<sup>25</sup>. It is estimated that EYS-RP accounts for 5-33% of all non-syndromic arRP cases, with a high prevalence in Japanese (18-33%), Spanish (15.9%) and French (12%) populations<sup>7-9,15,26-30</sup>. In Portugal, EYS is responsible for ~28% of arRP cases and accounts for 9% of all IRD cases in the IRD-PT registry<sup>18</sup>, making it the most commonly mutated IRD gene in our country. In this study, we thoroughly analyzed genetic, phenotypical, and clinical data from a large EYS cohort, thus contributing to a deeper understanding of EYS-RD.

First, our findings expand the genetic spectrum of EYS-RD by reporting 8 novel clinically significant EYS variants. The most frequent genetic defects were CNV deletions (almost 50%), in particular the c.(2023+1\_2024-1)\_ (2259+1\_2260-1)del variant, with an allele frequency of 37.9%



in our cohort. To date, this variant has only been reported in a Spanish and a Portuguese/Brazilian cohort of *EYS*-associated sector RP (published by our group)<sup>13,31</sup>. Compared to other studies, its prevalence in our cohort suggests a probable founder effect in the Portuguese population. Additionally, c.5928-2A>G and c.4120C>T p.(Arg1374Ter) were the second and third most frequently encountered variants. Except for a Tunisian study, the c.5928-2A>G variant has only been reported in Hispanic, Portuguese, and Brazilian families, suggesting a possible geographical prevalence<sup>13,32–34</sup>. On the other hand, the c.4120C>T p.(Arg1374Ter) variant seems to present more diverse geolocation as it was previously reported in Dutch, Spanish, and American cohorts<sup>14,28,35</sup>. Collectively, these 3 variants were responsible for 67.2% of the deleterious *EYS* variants in our cohort, suggesting possible hotspots in the Portuguese population.

Second, we used deep phenotyping by means of multimodal imaging to provide new insights regarding the *EYS*-RD phenotypes. Fifty-seven patients in our cohort had a clinical diagnosis of RP, while one had a clinical diagnosis of CORD. Based on UWF-CFP and UWF-FAF, we were able to separate typical (75%) from atypical (25%) cases, underlining the phenotypical heterogeneity that exists in *EYS*-RD. While typical *EYS*-RP patients exhibited imaging features in line with the available literature<sup>2</sup>, atypical *EYS*-RP phenotypes behave somewhat differently. In 2017, Sengillo *et al*<sup>14</sup> described an unusual hyperAF ring exhibiting a crescent-shaped boundary encroaching the central macula on FAF fundus imaging of *EYS*-RP patients, which was later integrated by some studies in the sector RP disease spectrum<sup>11,13,14,36</sup>. The authors<sup>14</sup> hypothesized that these atypical phenotypes could be related to mutations closer to the C-terminus (greater than GRch37 6:65300137), an association we did not find in our cohort. Most atypical cases in our cohort presented a complete/incomplete parafoveal hyperAF ring/arc together with inferior crescent-shaped macular atrophy and superior mid-peripheral retinal sparing. However, UWF-FAF depicted some degree of retinal degeneration in the far periphery (i.e., Fig. 2 G, I, K and L), which does not fit the classical sector RP definition<sup>36,37</sup>. The superior mid-peripheral sparing was also evident on SD-OCT, where EZ width was significantly longer on the superior quadrant than on the inferior quadrant. In line with our results, a recent study evaluated the damage in the superior and inferior retina in *EYS*-RP by means of SD-OCT and observed a predominant photoreceptor cell loss in the inferior quadrants<sup>38</sup>. The authors attributed this to the light-induced damage of the inferior retina due to the higher dose distribution of UV or visible light that it receives. Furthermore, they observed that the EZ in the superior retina was twice as long as that in the inferior retina<sup>38</sup>. While this may explain some of the findings observed in atypical cases, it does not explain the intra and interfamilial heterogeneity observed in this cohort, nor does it explain the retinal degenerative changes in the superior far periphery highlighted on UWF-FAF imaging. It can be hypothesized that younger

patients with atypical RP will eventually progress towards more typical phenotypes as they age. However, atypical RP patients in our cohort were older than patients presenting typical hyperAF rings, which suggests that these phenotypes are indeed milder. As others have suggested<sup>38</sup>, we believe that modifier genes, gene modulators, or additional environmental factors may be responsible for the heterogeneity observed in *EYS*-RD, which warrants further investigation.

Third, we evaluated the natural history of *EYS*-RD. In our study, most patients had the onset of symptoms during adolescence (11-20 years) and early adulthood (21-30 years). This is consistent with other large-scale studies which situated the onset of symptoms of *EYS*-RD between 16 and 21 years of age<sup>12,15-17</sup>. Regarding BCVA, patients with atypical forms showed significantly better BCVA than patients with typical RP. This is consistent with SD-OCT findings, as atypical patients had significantly larger EZ widths irrespective of the quadrant in comparison to those presenting a typical phenotype. Additionally, in typical RP, older patients had poorer BCVA, which attests to the naturally progressive evolution of the disease. This association was not found in atypical RP, which is consistent with another report that associated atypical *EYS*-RP with a better prognosis than typical *EYS*-RP<sup>10</sup>. That same study by Pierrache et al investigated the BCVA variation in patients with *EYS*-RD, reporting an average loss of 0.75 ETDRS letters per year of follow-up<sup>10</sup>. In our population, we observed a higher average loss of ETDRS letters per year (1.45 letters). Nevertheless, compared to the proposed average decline in BCVA of 2.3 letters per year described for RP<sup>39</sup>, *EYS*-RP can be placed in the milder spectrum of the disease. Lastly, when stratifying for RP phenotype, typical RP patients had a higher expected loss of ETDRS letters per year of follow-up than those presenting an atypical RP phenotype. Once again, this attests to the milder clinical course of *EYS*-associated atypical RP.

Our study presents some limitations. First, we have a small sample size of atypical RP due to the rare nature of *EYS*-RD, so caution is needed when extrapolating results and drawing conclusions. Second, we conducted a single-center, retrospective study, and sequential imaging data could not be retrieved for all patients. With this in mind, we conducted a cross-sectional evaluation using UWF imaging and SD-OCT, allowing for a thorough phenotype description. Lastly, our study comprises a cohort of Portuguese patients only. Due to the remarkable heterogeneity of *EYS* regarding genotype, phenotype and clinical progression, the external validity of the study may be affected.

In conclusion, this study expands the genetic spectrum of *EYS*-RD by reporting 8 novel *EYS* variants and identifying genetic hotspots in the Portuguese population. The high prevalence of CNV deletions in *EYS* emphasizes the need to include CNV screening in the genetic study of IRD patients. Furthermore, we provide robust evidence that *EYS*-RD is highly heterogeneous and that atypical cases are associated with a milder phenotype and overall better prognosis. As ophthalmology takes a deep dive into precision medicine, standardized phenotyping, as seen in

this study, is of extreme importance for patient selection and outcome measurement in clinical trials, but also for patient counseling on their future disease course. Prospective natural history studies with larger, multicenter, multicultural cohorts are needed to better characterize disease progression in *EYS*-RD and eventually establish genotype-phenotype correlations.

## REFERENCES

1. Van Trigt AC. De oogspiegel. *Ned Lancet, third Ser Utr.* 1852;1853:417-509.
2. Verbakel SK, van Huet RAC, Boon CJF, et al. Non-syndromic retinitis pigmentosa. *Prog Retin Eye Res.* 2018;66:157-186. doi:10.1016/j.preteyeres.2018.03.005
3. Collin RWJ, Littink KW, Klevering BJ, et al. Identification of a 2 Mb human ortholog of *Drosophila* eyes shut/spacemaker that is mutated in patients with retinitis pigmentosa. *Am J Hum Genet.* 2008;83(5):594-603. doi:10.1016/j.AJHG.2008.10.014
4. Abd El-Aziz MM, Barragan I, O'Driscoll CA, et al. *EYS*, encoding an ortholog of *Drosophila* spacemaker, is mutated in autosomal recessive retinitis pigmentosa. *Nat Genet.* 2008;40(11):1285-1287. doi:10.1038/NG.241
5. Garcia-Delgado AB, Valdes-Sanchez L, Morillo-Sanchez MJ, Ponte-Zuñiga B, Diaz-Corrales FJ, de la Cerda B. Dissecting the role of *EYS* in retinal degeneration: clinical and molecular aspects and its implications for future therapy. *Orphanet J Rare Dis.* 2021;16(1):222. doi:10.1186/s13023-021-01843-z
6. Alfano G, Kruczek PM, Shah AZ, et al. *EYS* Is a Protein Associated with the Ciliary Axoneme in Rods and Cones. *PLoS One.* 2016;11(11). doi:10.1371/JOURNAL.PONE.0166397
7. Iwanami M, Oishi A, Ogino K, et al. Five major sequence variants and copy number variants in the *EYS* gene account for one-third of Japanese patients with autosomal recessive and simplex retinitis pigmentosa. *Mol Vis.* 2019;25:766.
8. Gao FJ, Li JK, Chen H, et al. Genetic and Clinical Findings in a Large Cohort of Chinese Patients with Suspected Retinitis Pigmentosa. *Ophthalmology.* 2019;126(11):1549-1556. doi:10.1016/j.OPHTHA.2019.04.038
9. Iwanami M, Oshikawa M, Nishida T, Nakadomari S, Kato S. High prevalence of mutations in the *EYS* gene in Japanese patients with autosomal recessive retinitis pigmentosa. *Invest Ophthalmol Vis Sci.* 2012;53(2):1033-1040. doi:10.1167/IOVS.11-9048
10. Pierrache LHM, Messchaert M, Thiadens AAHJ, et al. Extending the Spectrum of *EYS*-Associated Retinal Disease to Macular Dystrophy. *Invest Ophthalmol Vis Sci.* 2019;60(6):2049-2063. doi:10.1167/IOVS.18-25531
11. Mucciolo DP, Sodi A, Passerini I, et al. Fundus phenotype in retinitis pigmentosa

- associated with EYS mutations. *Ophthalmic Genet.* 2018;39(5):589-602. doi:10.1080/13816810.2018.1509351
12. Gao FJ, Wang DD, Hu FY, et al. Genotypic spectrum and phenotype correlations of EYS-associated disease in a Chinese cohort. *Eye*. Published online 2021. doi:10.1038/s41433-021-01794-6
  13. Marques JP, Porto FBO, Carvalho AL, et al. EYS-Associated Sector Retinitis Pigmentosa. *Graefes Arch Clin Exp Ophthalmol.* 2022;260(4):1405-1413. doi:10.1007/S00417-021-05411-W
  14. Sengillo JD, Lee W, Nagasaki T, et al. A Distinct Phenotype of Eyes Shut Homolog (EYS)-Retinitis Pigmentosa Is Associated With Variants Near the C-Terminus. *Am J Ophthalmol.* 2018;190:99-112. doi:10.1016/j.ajco.2018.03.008
  15. Littink KW, Van Den Born LI, Koenekoop RK, et al. Mutations in the EYS gene account for approximately 5% of autosomal recessive retinitis pigmentosa and cause a fairly homogeneous phenotype. *Ophthalmology.* 2010;117(10). doi:10.1016/j.ophttha.2010.01.040
  16. Xu K, Chen DF, Chang H, et al. Genotype Profile of Global EYS-Associated Inherited Retinal Dystrophy and Clinical Findings in a Large Chinese Cohort. *Front Cell Dev Biol.* 2021;9. doi:10.3389/fcell.2021.634220/FULL
  17. Yang L, Fujinami K, Ueno S, et al. Genetic Spectrum of EYS-associated Retinal Disease in a Large Japanese Cohort: Identification of Disease-associated Variants with Relatively High Allele Frequency. *Sci Rep.* 2020;10(1). doi:10.1038/s41598-020-62119-3
  18. Marques JP, Carvalho AL, Henriques J, Murta JN, Saraiva J, Silva R. Design, development and deployment of a web-based interoperable registry for inherited retinal dystrophies in Portugal: the IRD-PT. *Orphanet J Rare Dis.* 2020;15(1). doi:10.1186/s13023-020-01591-6
  19. Marques JP, Marta A, Geada S, et al. Clinical/Demographic Functional Testing and Multimodal Imaging Differences between Genetically Solved and Unsolved Retinitis Pigmentosa. *Ophthalmologica.* 2022;245(2). doi:10.1159/000520305
  20. Otte B, Andrews C, Lacy G, Branham K, Musch DC, Jayasundera KT. Clinical trial design for neuroprotection in RHO autosomal dominant retinitis pigmentosa; outcome measure considerations. *Ophthalmic Genet.* 2021;42(2):170-177. doi:10.1080/13816810.2020.1867752
  21. Richards S, Aziz N, Bale S, et al. Standards and guidelines for the interpretation of sequence variants: a joint consensus recommendation of the American College of Medical Genetics and Genomics and the Association for Molecular Pathology. *Genet Med.* 2015;17(5):405-424. doi:10.1038/GIM.2015.30

22. Fujinami K, Lois N, Mukherjee R, et al. A longitudinal study of Stargardt disease: quantitative assessment of fundus autofluorescence, progression, and genotype correlations. *Invest Ophthalmol Vis Sci.* 2013;54(13):8181-8190. doi:10.1167/IOVS.13-12104
23. Kong X, Fujinami K, Strauss RW, et al. Visual Acuity Change Over 24 Months and Its Association With Foveal Phenotype and Genotype in Individuals With Stargardt Disease: ProgStar Study Report No. 10. *JAMA Ophthalmol.* 2018;136(8):920-928. doi:10.1001/JAMAOPHTHALMOL.2018.2198
24. Marques JP, Simão J. Double Concentric Hyperautofluorescent Ring in EYS-Associated Retinitis Pigmentosa. *Asia-Pacific J Ophthalmol (Philadelphia, Pa).* Published online February 2022. doi:10.1097/APO.0000000000000473
25. Schneider N, Sundaresan Y, Gopalakrishnan P, et al. Inherited retinal diseases: Linking genes, disease-causing variants, and relevant therapeutic modalities. *Prog Retin Eye Res.* 2022;89. doi:10.1016/J.PRETEYERES.2021.101029
26. Bandah-Rozenfeld D, Littink KW, Ben-Yosef T, et al. Novel null mutations in the EYS gene are a frequent cause of autosomal recessive retinitis pigmentosa in the Israeli population. *Invest Ophthalmol Vis Sci.* 2010;51(9):4387-4394. doi:10.1167/IOVS.09-4732
27. Audo I, Sahel JA, Mohand-Saïd S, et al. EYS is a major gene for rod-cone dystrophies in France. *Hum Mutat.* 2010;31(5). doi:10.1002/HUMU.21249
28. Barragán I, Borrego S, Pieras JI, et al. Mutation spectrum of EYS in Spanish patients with autosomal recessive retinitis pigmentosa. *Hum Mutat.* 2010;31(11). doi:10.1002/HUMU.21334
29. Hosono K, Ishigami C, Takahashi M, et al. Two novel mutations in the EYS gene are possible major causes of autosomal recessive retinitis pigmentosa in the Japanese population. *PLoS One.* 2012;7(2). doi:10.1371/JOURNAL.PONE.0031036
30. Arai Y, Maeda A, Hiram Y, et al. Retinitis Pigmentosa with EYS Mutations Is the Most Prevalent Inherited Retinal Dystrophy in Japanese Populations. *J Ophthalmol.* 2015;2015. doi:10.1155/2015/819760
31. Pieras JI, Barragán I, Borrego S, et al. Copy-number variations in EYS: a significant event in the appearance of arRP. *Invest Ophthalmol Vis Sci.* 2011;52(8):5625-5631. doi:10.1167/IOVS.11-7292
32. González-del Pozo M, Borrego S, Barragán I, et al. Mutation screening of multiple genes in Spanish patients with autosomal recessive retinitis pigmentosa by targeted resequencing. *PLoS One.* 2011;6(12). doi:10.1371/JOURNAL.PONE.0027894
33. Habibi I, Chebil A, Falfoul Y, et al. Identifying mutations in Tunisian families with retinal dystrophy. *Sci Rep.* 2016;6. doi:10.1038/SREP37455

34. McGuigan DB, Heon E, Cideciyan A V., et al. EYS Mutations Causing Autosomal Recessive Retinitis Pigmentosa: Changes of Retinal Structure and Function with Disease Progression. *Genes (Basel)*. 2017;8(7). doi:10.3390/GENES8070178
35. Messchaert M, Haer-Wigman L, Khan MI, Cremers FPM, Collin RWJ. EYS mutation update: In silico assessment of 271 reported and 26 novel variants in patients with retinitis pigmentosa. *Hum Mutat*. 2018;39(2):177-186. doi:10.1002/HUMU.23371
36. Georgiou M, Grewal PS, Narayan A, et al. Sector Retinitis Pigmentosa: Extending the Molecular Genetics Basis and Elucidating the Natural History. *Am J Ophthalmol*. 2021;221:299-310. doi:10.1016/j.ajoph.2020.08.004
37. Bietti GB. Su alcune forme atipiche o rare di degenerazione retinica (degenerazione tappetoretiniche e quadri morbosi similari). *Boll Ocul*. 1937;16:1159.
38. Otsuka Y, Oishi A, Miyata M, et al. Evaluation of outer nuclear layer overshadowed by retinal vessels in retinitis pigmentosa. *Eye* 2021. Published online May 11, 2021:1-8. doi:10.1038/s41433-021-01578-y
39. Iftikhar M, Usmani B, Sanyal A, et al. Progression of retinitis pigmentosa on multimodal imaging: The PREP-I study. *Clin Experiment Ophthalmol*. 2019;47(5):605-613. doi:10.1111/CEO.13458

Manuscript 10

**3.4. Genetic spectrum, retinal phenotype and peripapillary RNFL thickness in RPGR heterozygotes**

João Pedro Marques

Rosa Pinheiro

Ana Luísa Carvalho

Miguel Raimundo

Mário Soares

Pedro Melo

Joaquim Murta

Jorge Saraiva

Rufino Silva

*Published in: Graefes Arch Clin Exp Ophthalmol. 2022 Sep 2. Online ahead of print.*

## **ABSTRACT**

### **Purpose**

Phenotypic heterogeneity with variable severity has been reported in female carriers of *RPGR* mutations, including a male-type phenotype. A phenomenon not fully understood is peripapillary retinal nerve fiber layer thickening (pRNFL) in male patients with *RPGR*-associated X-linked retinitis pigmentosa, especially in the temporal sector. We aim to describe the genetic spectrum, retinal phenotypes and pRNFL thickness in a cohort of Caucasian *RPGR*-mutation heterozygotes.

### **Methods**

Cross-sectional study conducted at an inherited retinal degeneration (IRD) reference center in Portugal. Female patients heterozygous for clinically significant *RPGR* variants were identified using the IRD-PT registry. A complete ophthalmologic examination was performed, complemented by macular and peripapillary spectral-domain optical coherence tomography (SD-OCT), ultra-widefield (UW) color fundus photography (CFP) and UW fundus autofluorescence (FAF). The retinal phenotypes were graded according to previously described classifications. The pRNFL thickness across the superior, inferior, nasal and temporal quadrants was compared to the Spectralis® RNFL age-adjusted reference database.

### **Results**

Forty-eight eyes from 24 females (10 families) were included in the study. Genetic analysis yielded 8 distinct clinically significant frameshift variants in *RPGR* gene, 3 of which herein reported for the first time. No association was found between mutation location and best-corrected visual acuity (BCVA) or retinal phenotype. Age was associated with worse BCVA and more advanced phenotypes on SD-OCT, UW-CFP and UW-FAF. Seven women (29.17%) presented a male-type phenotype on UW-FAF in at least one eye. An association was found between UW-FAF and pRNFL thickness in the temporal sector ( $p=0.003$ ), with the most advanced FAF phenotypes showing increased pRNFL thickness in this sector.

### **Conclusion**

This study expands the genetic landscape of *RPGR*-associated disease by reporting 3 novel clinically significant variants. We have shown that clinically severe phenotypes are not uncommon among female carriers. Furthermore, we provide novel insights into pRNFL changes observed in *RPGR* heterozygotes that mimic what has been reported in male patients.



## INTRODUCTION

Retinitis pigmentosa (RP) is the most common inherited retinal degeneration (IRD), with an worldwide prevalence of 1:4000 individuals.<sup>1</sup> Clinically significant variants in Retinitis Pigmentosa GTPase Regulator (*RPGR*) gene account for 70-80% of X-linked retinitis pigmentosa (XLRP), one of the most severe forms of non-syndromic RP in males.<sup>2,3</sup> To date, more than 600 variants in the *RPGR* gene have been described.<sup>4</sup> It is well documented that female carriers of *RPGR* mutations may show disease phenotypes of variable severity, often with significant inter-eye asymmetry.<sup>2,3,5,6</sup> The phenotypic heterogeneity in females is believed to be due to X-inactivation, a chromosomal process occurring in the X-inactivation center and affecting many X chromosome genes.<sup>7,8</sup> Preferred inactivation of one X chromosome over the other can either be random or a consequence of mutations/structural X chromosome changes. Mutations may skew the inactivation process with the mutant allele being preferentially selected or inactivated, altering the ratio of mutant to wildtype X chromosomes selected.<sup>2</sup> Thus, retinal findings in *RPGR*-mutation female carriers may range from normal fundus appearance to a severe male-like phenotype.<sup>2,6,9,10</sup> Fundus autofluorescence is particularly helpful in detecting such retinal mosaicism.<sup>2,11</sup>

Although most *RPGR*-mutation carriers do not usually report symptoms,<sup>6,12</sup> myopia and amblyopia are common findings and decreased visual acuity (VA), reduced dark adaptation, electroretinogram changes and visual field constriction have been reported.<sup>3,6,11</sup>

Four main patterns of fundus appearance have been described in *RPGR*-mutation carriers: normal or near normal pattern (grade 0), tapetal-like reflex (TLR, grade 1), focal or patchy pigmentary changes limited to a quadrant or hemisphere (grade 2), and three or more quadrants of bone-spicule hyperpigmentation or atrophy (grade 3).<sup>3,6,11</sup> Additionally, Nanda et al<sup>2</sup> described four fundus autofluorescence (FAF) patterns: (1) N-pattern (normal or near-normal appearance); (2) R-pattern (radial-spoke shaped reflexes extending from the central macular area in a radial pattern); (3) F-pattern (focal pigmentary retinopathy patchy pigmentation with a radial reflex pattern); and (4) M-pattern (male pattern retinitis pigmentosa). Visual function has been shown to largely correlate with the retinal phenotype, i. e. patients with a normal fundus or TLR are more likely to retain good visual acuity (VA), while those with widespread changes are more prone to have impaired VA.<sup>6,11,12</sup>

A phenomenon not fully understood is inner retinal thickening and peripapillary retinal nerve fiber (pRNFL) layer thickening in male patients with *RPGR*-associated XLRP.<sup>13,14</sup> These changes are detectable relatively early in the disease course and may reflect a neuronal-gial retinal remodeling response to photoreceptor stress or loss.<sup>13-15</sup> To this date, no study has specifically investigated pRNFL changes in *RPGR*-mutation carriers.

The purpose of this study was to describe the genetic spectrum, retinal phenotypes and pRNFL thickness in a cohort of Caucasian *RPGR*-mutation female carriers.

## **METHODS**

### ***Study Design and Diagnostic Criteria***

Cross-sectional study conducted at an IRD reference center in Portugal (Centro Hospitalar e Universitário de Coimbra). The study was approved by the local Ethics Committee and followed the tenets of the Declaration of Helsinki for biomedical research. Female patients heterozygous for disease-causing (ie likely pathogenic or pathogenic) *RPGR* variants were identified using the IRD-PT registry.<sup>16</sup> Only female patients with molecular confirmation of a clinically significant *RPGR* mutation (class IV or class V according to the American College of Medical Genetics and Genomics)<sup>17</sup> or an obligate carrier status were included. Obligate carriers were defined as daughters of an affected male patient with *RPGR*-associated disease, mothers of at least two affected sons, or mothers of one affected son along with at least one other affected male patient or confirmed carrier in the family, to exclude the possibility of a *de novo* mutation.

### ***Clinical evaluation and retinal phenotypes***

A complete ophthalmologic examination was performed, including ETDRS best-corrected VA (BCVA) converted to LogMAR, manifest refraction, spherical equivalent, biomicroscopy and dilated funduscopy. All subjects were observed by the same IRD specialist (J.P.M). Age at diagnosis, presence/absence of symptoms, and family history were retrieved from each individual patient file. Spectralis® (Heidelberg Engineering, Heidelberg, Germany) spectral-domain optical coherence tomography (SD-OCT) was used to evaluate the central foveal thickness, inner retinal layers, outer retinal layers and pRNFL thickness. Optos® (Optos California, Optos GmbH, Germany) ultra-widefield color fundus photography (UW-CFP) and UW-FAF was used to grade fundus changes and FAF phenotypes according to previously used criteria.<sup>2,3,6,11</sup> On UW-CFP, the retinal phenotype was graded as: normal (grade 0); a TLR without pigmentary changes in the retina (grade 1); regional pigmentary changes such as bone spicule-like pigmentation involving at least two quadrants, and/or macular RPE alterations, with or without a TLR (grade 2); at least three quadrants of pigmentary changes or RPE atrophy in the periphery (grade 3).<sup>11</sup> On UW-FAF, the retinal phenotype was graded according to Nanda et al<sup>2</sup>: (1) N-pattern (normal or near-normal fundus appearance); (2) R-pattern (radial-spoke shaped reflexes extending from the central macular area in a radial pattern); (3) F-pattern (focal pigmentary retinopathy patchy pigmentation with a radial reflex pattern); and (4) M-pattern (male pattern retinitis pigmentosa).

On SD-OCT, peripapillary and macular manual segmentation was performed whenever automated retinal layer segmentation was inadequate. SD-OCT macular scans were graded according to the extent of atrophy of the ellipsoid zone (EZ) and external limiting membrane (ELM) in the macular cube acquisition scans: (1) no atrophy; (2) atrophy outside the central 1-mm; (3) atrophy within the central 1-mm but sparing the central point; (4) subfoveal atrophy (central point involvement). The pRNFL thickness was compared to the Spectralis® pRNFL age-adjusted reference database for European descent (201 subjects; age range 18 – 78 years; refractive errors from +5D to -7D). Eyes with unreliable pRNFL thickness measurements due to severe peripapillary atrophy associated with tilted disc syndrome were excluded from the analysis.

Inter-eye symmetry was considered when both eyes from the same patient shared the same grade on UW-CFP, UW-FAF and macular SD-OCT. All images were graded by 2 independent medical graders (R.P. and J.P.M.). Inter-grader agreement (Supplemental Table 1) was evaluated by the percentage of agreement and the weighted Kappa coefficient considering linear weights.<sup>18</sup> Disagreement was resolved by open adjudication.

### **Statistical analysis**

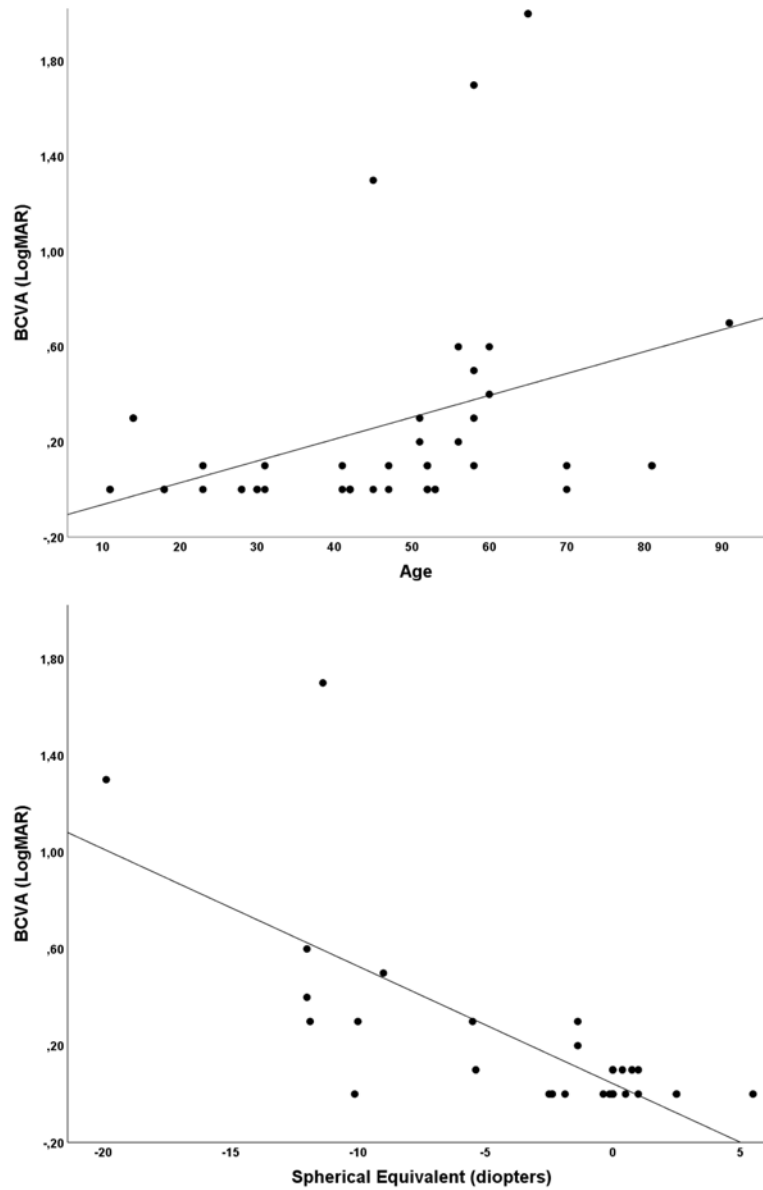
Data from both eyes were analyzed. Independent *t* tests and linear and logistic regression models were used to determine associations between variables. Comparison between pRNFL thickness and the Spectralis® pRNFL age-adjusted reference database for European descent was performed manually by identifying cases with a pRNFL thickness that did not fall within 1 standard-deviation (SD) limit for each peripapillary sector. SPSS software version 25.0 (SPSS Inc., Chicago, IL, USA) was used to perform all statistical analysis. P-values <0.05 were considered statistically significant.

## **RESULTS**

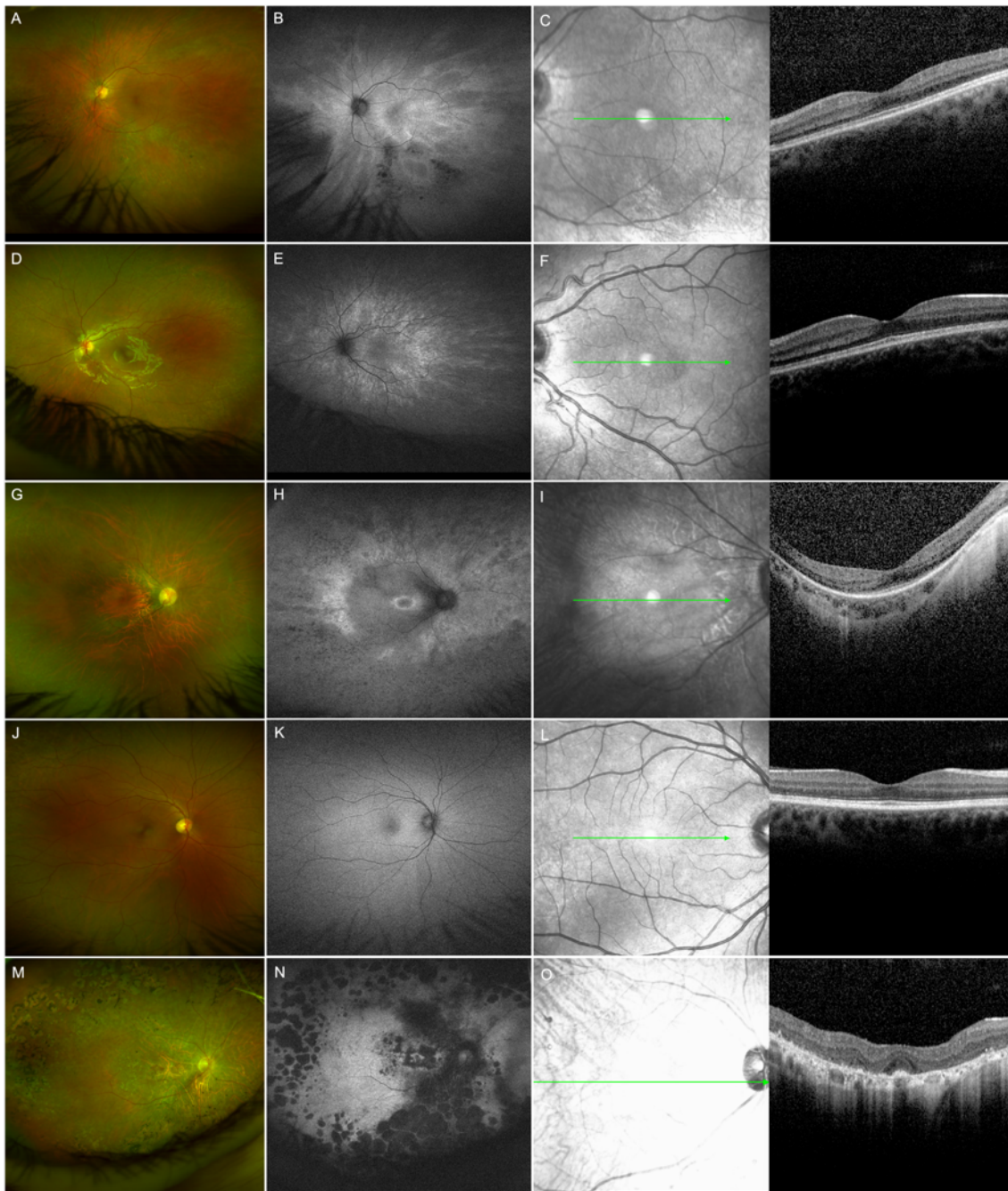
Forty-eight eyes from 24 Caucasian female patients (10 families) were included in the study. All patients were Portuguese, except for one who was from Ukraine. Twenty-three heterozygotes were from RP pedigrees and 1 (the Ukrainian female) from a cone/cone-rod dystrophy pedigree. Median age was 49 years (range 11 – 91 years old). Nyctalopia was reported by 4 patients and photophobia by 1. Mean BCVA was  $0.26 \pm 0.49$  logMAR (range 0 to 2 logMAR), with 4 females (16.6%) presenting a BCVA below 20/200 (logMAR 1.0) in at least one eye. Mean spherical equivalent (SE) was  $-3.19 \pm 5.67$  D (range -19.87 to 5.5 D) and 8 eyes (16.6%) had a SE lower than -6 D.

When exploring parameters that could be related to visual outcomes (Supplemental Figure 1), we found a positive correlation between age and logMAR BCVA ( $R^2 = 0.123$ ,  $p = 0.016$ ). Myopia

was associated with worse visual acuity, demonstrated by the negative correlation between SE and logMAR BCVA ( $R^2 = 0.535$ ,  $p < 0.001$ ).



**Supplemental Figure I.** *Top* Graphical representation depicting the positive correlation between logMAR best-corrected visual acuity (BCVA) and age ( $R^2 = 0.123$ ,  $p = 0.016$ ). *Bottom* Graphical representation depicting the negative correlation between logMAR BCVA and spherical equivalent ( $R^2 = 0.535$ ,  $p < 0.001$ ).



**Figure 1.** Phenotypic heterogeneity in RPGR-mutation heterozygotes. Five examples of UW-CFP, UW-FAF and macular OCT phenotypes are shown. (A-C) Left eye of a patient with regional pigmentary changes including bone spicule-like pigmentation involving the nasal and inferior quadrants (UW-CFP grade 2) and focal pigmentary retinopathy patchy pigmentation with a radial reflex pattern (F-pattern). On macular SD-OCT no atrophy of the outer retinal layers is seen on the horizontal scan (grade 1). (D-F) Left eye of a young patient with apparently normal UW-CFP (grade 0) but clear radial-spoke shaped reflexes extending from the central macular area in a radial pattern on UW-FAF (R-pattern) and a normal macular OCT (grade 1). (G-I) Right eye of an heterozygote with typical a male-like changes, including pigmentary changes in the periphery and a parafoveal hyperautofluorescent ring on UW-FAF (M-pattern). The horizontal

scan on macular SD-OCT shows concentric loss of outer retinal layers outside the central 1-mm (grade 2). (J-L) Right eye of a heterozygote with normal UW-CFP (grade 0), UW-FAF (N-pattern) and macular SD-OCT (grade 1; no outer retinal atrophy). (M-O) Right eye of a heterozygote with advanced disease (male-type presentation), including macular atrophy depicted by macular hypoautofluorescence. On SD-OCT, preservation of the outer retinal layers is only observed subfoveally (grade 3).

### **Genetic spectrum**

Genetic analysis yielded 8 distinct clinically significant frameshift variants in the *RPGR* gene, 5 pathogenic and 3 likely pathogenic (Table 1), from 10 different families. Six variants were located in the ORF15 region, while the remaining 2 were located in exons 10 and 11 (Table 1). Five variants were previously reported, while 3 are herein reported for the first time: the likely pathogenic c.2872del p.(Glu958Lysfs\*131) and c.2615\_2616del p.(Glu872Glyfs\*206) variants, located in the ORF15 region and the pathogenic c.1261dup p.(Ser421Phefs\*32) variant located in exon 11. No association was found between BCVA and variant location.

### **Retinal Phenotypes**

Twenty-one eyes (43.8%) showed no abnormalities on UW-CFP (grade 0); 12 eyes (25%) were classified as grade 1; 7 eyes (14.6%) were classified as grade 2, and 8 eyes (16.7%) were classified as grade 3 (Table 2). Regarding UW-FAF patterns, the N-pattern was identified in 5 eyes (10.4%), the R-pattern in 23 eyes (47.9%), the F-pattern in 8 eyes (16.7%) and the M-pattern in 12 eyes (25%). Interestingly, of the 23 eyes with a radial pattern on UW-FAF, the TLR (grade 1) had not been detected on fundoscopy or UW-CFP in 16 of 23 (69.56%). On the other hand, in the 5 eyes without FAF abnormalities, UW-CFP was graded normal in all (Table 2).

On SD-OCT, a normal macular structure was observed in 32 eyes (66.7%). Seven eyes (14.6%) showed loss of integrity of the outer retinal layers outside the central 1-mm, 4 eyes (8.3%) had loss of integrity of the outer retinal layers within the central 1-mm but showed preservation of the central point and 5 eyes (10.4%) showed loss of the EZ and ELM affecting the central point (Table 2). No anatomical correlates were observed for the TLR on SD-OCT. Macular SD-OCT thickness values were obtained after manual segmentation. Mean central retinal thickness was  $257.29 \pm 23.92 \mu\text{m}$ , mean central point thickness was  $229.96 \pm 22.29$  and mean macular volume was  $7.54 \pm 0.66 \text{ mm}^3$ . There was no correlation between central retinal thickness and UW-FAF, UW-CFP or macular SD-OCT phenotypes ( $p > 0.05$  for all). However, there was a negative correlation between macular volume and UW-FAF, UW-CFP and OCT phenotypes ( $p = 0.03$ ,  $p = 0.03$  and  $p < 0.05$ , respectively), showing that more advanced phenotypes have lower macular volumes. Additionally, we analyzed the macular inner retinal

layers (RNFL, ganglion cell layer and inner plexiform layer). Mean macular RNFL thickness was  $16.44 \pm 6.68 \mu\text{m}$ , mean macular ganglion cell layer thickness was  $16.37 \pm 4.9 \mu\text{m}$  and mean macular inner plexiform layer thickness was  $22.62 \pm 4.64 \mu\text{m}$ . No correlation was found between thickness of each of these layers and UW-FAF, UW-CFP or SD-OCT phenotypes ( $p > 0.05$ ). There was also no correlation between macular retinal inner layer thickness and BCVA ( $p > 0.05$ ).

Inter-eye symmetry was observed on UW-CFP in 19 patients, on UW-FAF in 18 patients, and on SD-OCT in 18 patients (Table 2). Figure 1 shows 5 examples of different UW-FAF, UW-CFP and macular OCT phenotypes. No correlation was found between genotype and UW-CFP, UW-FAF or macular SD-OCT classifications. However, UW-FAF, UW-CFP and macular SD-OCT phenotypes were found to negatively correlate with BCVA ( $p = 0.003$ ,  $p = 0.001$  and  $p < 0.001$ , respectively), with the most advanced phenotypes associated with lower BCVA in all imaging methods. This was still true after adjusting for age ( $p = 0.005$ ,  $p = 0.001$  and  $p = 0.002$ , respectively) but significance was lost for UW-CFP and UW-FAF when adjusting for SE ( $p > 0.05$  for both). SD-OCT was the only independent predictor of BCVA after adjusting for SE ( $p = 0.001$ ). There was a significant correlation between age and UW-FAF, UW-CFP and SD-OCT grading, with older patients exhibiting more severe phenotypes ( $p = 0.003$ ,  $p < 0.001$  and  $p < 0.001$ , respectively).

**Table I.** Genetic landscape of the cohort

Reference Sequence	Location	Nucleotide change	Effect	Variant type	Female patients N (%)	Families N (%)	ACMG Classification	References
NM_001034853.2	ORF15	c.2763_2764del	p.Glu922Glyfs*156	Frameshift	6 (25.0)	1 (10)	Pathogenic	PMID: 10932196; 14564670; 17325176; 23372056
NM_001034853.2	ORF15	c.2872del	p.Glu958Lysfs*131	Frameshift	5 (20.8)	1 (10)	Likely pathogenic	This study
NM_001034853.2	Exon 11	c.1261dup	p.Ser421Phefs*32	Frameshift	1 (4.2)	1 (10)	Pathogenic	This study
NM_001034853.2	ORF15	c.3178_3179del	p.Glu1060Argfs*18	Frameshift	1 (4.2)	1 (10)	Likely pathogenic	PMID: 16936086; 30567410; 31645972; 28559085
NM_001034853.2	Exon 10	c.1243_1244del	p.Arg415Glyfs*37	Frameshift	5 (20.8)	3 (30)	Pathogenic	PMID: 21857984; 27208204; 28322733; 31953110; 32343782; 15173948
NM_001034853.2	ORF15	c.2501del	p.Glu834Glyfs*255	Frameshift	1 (4.2)	1 (10)	Pathogenic	PMID: 15173948
NM_001034853.2	ORF15	c.2426_2427del	p.Glu809Glyfs*25	Frameshift	1 (4.2)	1 (10)	Pathogenic	PMID: 10932196; 11992260; 14564670; 14566651; 17093403; 17325176; 18552978; 20064120; 21857984; 23822596; 28559085; 29528978; 30105367; 30543658; 30567410; 32209785; 32343782
NM_001034853.2	ORF15	c.2615_2616del	p.Glu872Glyfs*206	Frameshift	4 (16.6)	1 (10)	Likely pathogenic	This study



**Table 2.** UW-CFP, UW-FAF and macular SD-OCT retinal phenotypes for each individual patient, according to age and genetic data (variant and location).

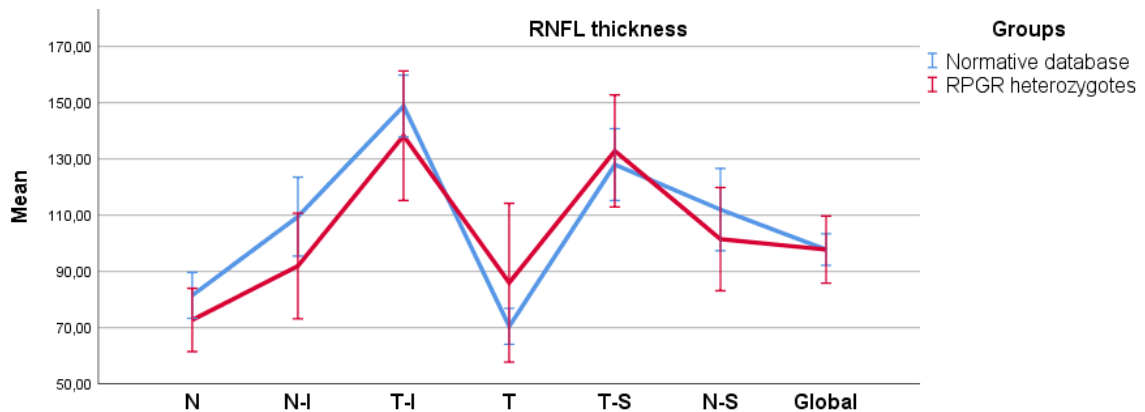
FAMILY	PATIENT	AGE	GENETIC VARIANT	LOCATION	UW-CFP CLASSIFICATION		UW-FAF CLASSIFICATION		MACULAR SD-OCT		INTEREYE SYMMETRY (YES/NO)		
					RE	LE	RE	LE	RE	LE	UW-CFP	UW-FAF	Macular SD-OCT
1	P1	52	c.1243_1244del (p.Arg415Glyfs*37)	Exon 10	0	0	1	2	1	1	Yes	No	Yes
2	P2	31	c.2615_2616del p.(Glu872Glyfs*206)	ORF15	1	1	3	2	1	2	Yes	No	No
	P3	58	c.2615_2616del p.(Glu872Glyfs*206)	ORF15	0	2	2	3	1	1	No	No	Yes
	P4	28	c.2615_2616del p.(Glu872Glyfs*206)	ORF15	0	0	2	2	1	1	Yes	Yes	Yes
	P5*	60	c.2615_2616del p.(Glu872Glyfs*206)	ORF15	3	3	4	4	2	4	Yes	Yes	No
3	P6	18	c.2763_2764del p.(Glu922Glyfs*156)	ORF15	0	0	2	2	1	1	Yes	Yes	Yes
	P7*	23	c.2763_2764del p.(Glu922Glyfs*156)	ORF15	1	1	4	4	2	2	Yes	Yes	Yes
	P8	91	c.2763_2764del p.(Glu922Glyfs*156)	ORF15	3	3	4	4	4	3	Yes	Yes	No
	P9	47	c.2763_2764del p.(Glu922Glyfs*156)	ORF15	1	1	3	3	1	1	Yes	Yes	Yes
	P10	42	c.2763_2764del p.(Glu922Glyfs*156)	ORF15	0	0	2	2	1	1	Yes	Yes	Yes
	P11	11	c.2763_2764del p.(Glu922Glyfs*156)	ORF15	0	0	2	2	1	1	Yes	Yes	Yes
	P12	52	c.2763_2764del p.(Glu922Glyfs*156)	ORF15	0	0	1	1	1	1	Yes	Yes	Yes
4	P13	41	c.3178_3179del p.(Glu1060Argfs*18)	ORF15	0	0	1	1	1	1	Yes	Yes	Yes
5	P14	30	c.1243_1244del (p.Arg415Glyfs*37)	Exon 10	1	0	2	2	1	1	No	Yes	Yes
	P15	70	c.1243_1244del (p.Arg415Glyfs*37)	Exon 10	1	1	2	2	1	1	Yes	Yes	Yes
6	P16*	56	c.2872del p.(Glu958Lysfs*131)	ORF15	3	2	4	3	3	2	No	No	No
	P17	58	c.2872del p.(Glu958Lysfs*131)	ORF15	2	2	3	3	2	4	Yes	Yes	No
	P18*	65	c.2872del p.(Glu958Lysfs*131)	ORF15	3	3	4	4	4	4	Yes	Yes	Yes
	P19	53	c.2872del p.(Glu958Lysfs*131)	ORF15	0	0	2	2	1	1	Yes	Yes	Yes
7	P20	42	c.2501del p.(Glu834Glyfs*255)	ORF15	1	1	2	2	1	1	Yes	Yes	Yes
8	P21	45	c.1243_1244del (p.Arg415Glyfs*37)	Exon 10	2	0	3	2	1	1	No	No	Yes
	P22	51	c.1243_1244del (p.Arg415Glyfs*37)	Exon 10	2	1	4	2	2	1	No	No	No
9	P23	81	c.2426_2427del p.(Glu809Glyfs*25)	ORF15	3	3	4	4	3	3	Yes	Yes	Yes
10	P24	14	c.1261dup p.(Ser421Phefs*32)	Exon 11	0	0	2	2	1	1	Yes	Yes	Yes

\* Complaints of nyctalopia

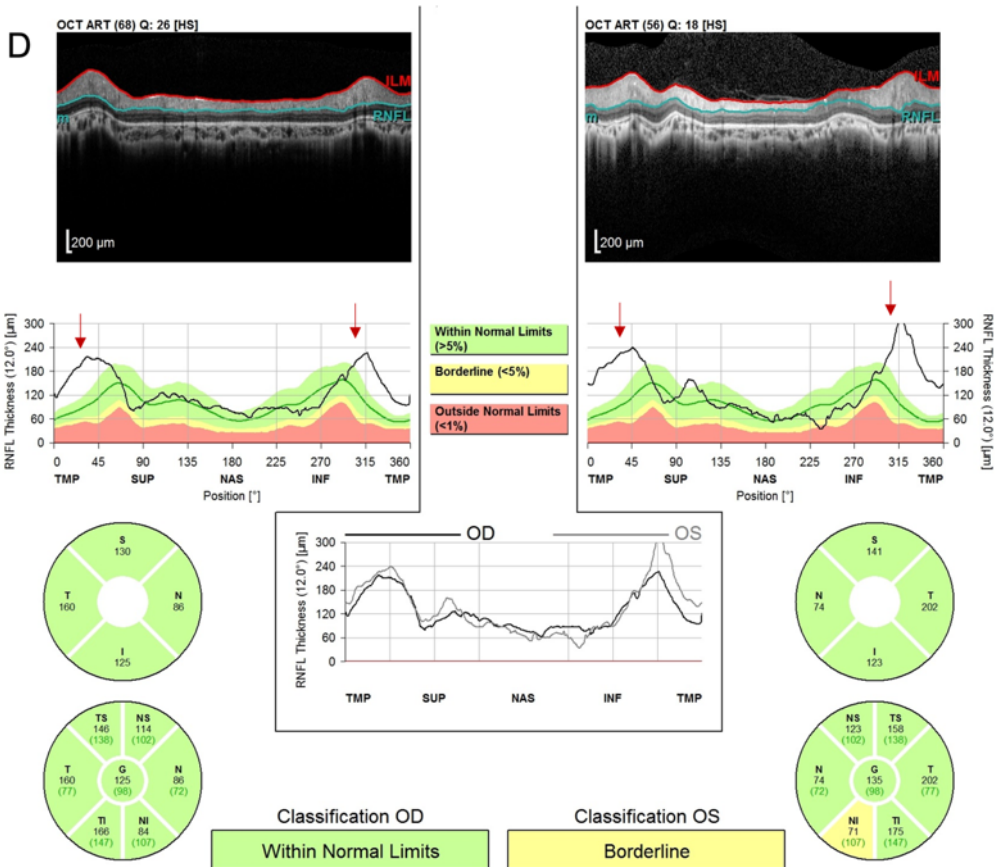
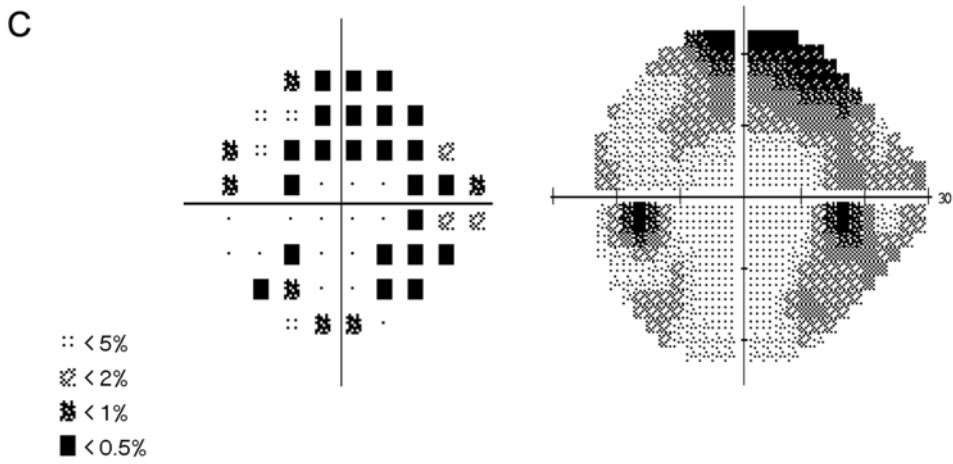
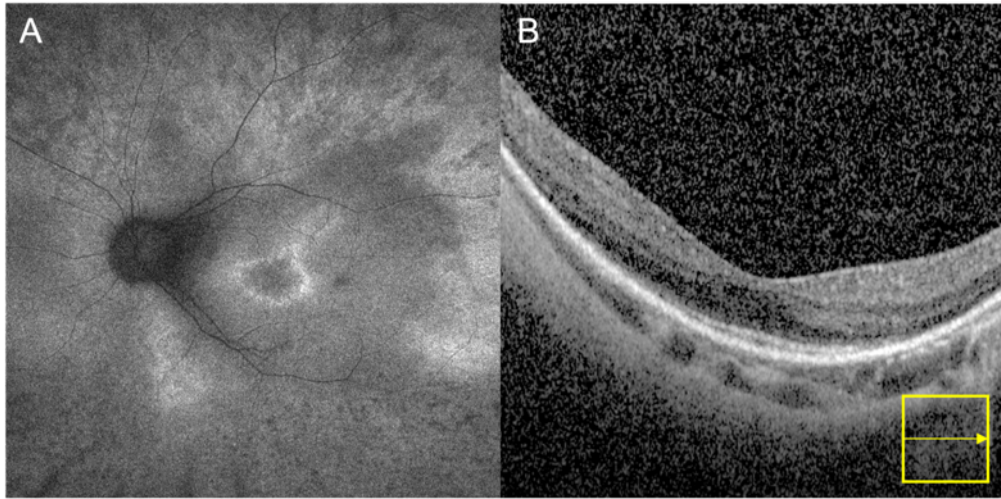
UW – ultra-widfield; CFP – color fundus photography; FAF – fundus autofluorescence; SD-OCT – spectral domain optical coherence tomography

### Peripapillary Retinal Nerve Fiber Layer (pRNFL) Thickness

In the subset of eyes where accurate pRNFL thickness measurements were possible to obtain (n=35), mean global pRNFL thickness in heterozygotes did not significantly differ from age-matched controls from the Spectralis® normative database ( $97.78 \pm 11.93 \mu\text{m}$  vs.  $97.8 \pm 8.6 \mu\text{m}$ ;  $p = 0.993$ ). Sector-wise comparison of the pRNFL thickness between RPGR female carriers and the Spectralis® normative database is graphically depicted in Figure 2. On a topographic level, 10 eyes (28.57%) showed an increase in thickness (characterized by 1 SD above the mean) of the temporal superior sector, 14 and 15 eyes (40% and 42.85%, respectively) had a decrease in thickness (characterized by 1 SD below the mean) of the temporal inferior sector and nasal inferior sectors, respectively, and 18 eyes (51.42%) had an increase in thickness (characterized by 1 SD above the mean) of the temporal sector. No correlation was found between the pRNFL thickness and BCVA, genotype, UW-CFP or SD-OCT phenotypes. However, a significant correlation was found between the UW-FAF classification and the pRNFL thickness in the temporal sector ( $p = 0.003$ ), with the most advanced FAF phenotypes associated with an increased pRNFL thickness in this sector (Figure 3).



**Figure 2.** Sector-wise comparison of the peripapillary retinal nerve fiber layer (pRNFL) thickness between RPGR heterozygotes from our cohort and controls from the Spectralis® pRNFL age-adjusted reference database for European descent.



**Figure 3.** Multimodal imaging and visual field of P7 (the right eye of this patient is shown on Figure 1 G-I). (A) Left eye (LE) UW-FAF depicting a parafoveal hyperautofluorescent ring (M-pattern). (B) LE macular horizontal SD-OCT showing concentric loss of outer retinal layers outside the central 1-mm. (C) On 24-2 Humphrey visual field testing of the LE, peripheral concentric visual field loss is observed, establishing a perfect structure-functional correlation with UW-FAF and SD-OCT. The right eye (not shown) is very similar. (D) pRNFL thickening is observed in both eyes, especially in the temporal sector (red arrows).

## DISCUSSION

This study expands the genetic landscape of *RPGR*-associated disease and shows that clinically severe phenotypes are not uncommon among female carriers. Furthermore, we provide novel insights into pRNFL changes observed in *RPGR* heterozygotes.

We found 8 distinct clinically significant variants in the *RPGR* gene in our cohort of 24 females (10 families), 3 of which are herein reported for the first time. Six variants were located in the ORF15 region, while in the remaining 2 were located in exons 10 and 11. Previous studies have found that female carriers with mutations in *RPGR* ORF15 showed worse measures of visual function than carriers with mutations in exons 1–14.<sup>6,19</sup> Like Nanda et al,<sup>2</sup> we found no specific correlation between mutation location and phenotype category or BCVA. Although the small number of patients may have precluded us from establishing genotype-phenotype correlations, our findings are in agreement with a recent genotype-phenotype study comprising a large cohort where no association was found between BCVA and location or variant type in female carriers.<sup>4</sup>

Moderate and high myopia are frequently present in *RPGR* carriers, referred to as an “X-linked dominant pattern of myopia” with a higher penetrance than the X-linked recessive pattern of RP.<sup>7,20,21</sup> The reasons behind the association between *RPGR* mutations and high myopia remain unclear, but after analyzing refractive errors in a large cohort of IRDs, Hendriks et al<sup>22</sup> postulated that the transport area between the inner and outer segment (i.e., the location of *RPGR* protein), is one of the critical sites for refractive error development. Although it is reasonable to assume that part of the retinal function loss in female carriers is secondary to their high myopia, the degree of retinal damage in these carrier females exceeds the degree predicted by the myopia alone.<sup>23</sup> Additionally, Yang et al<sup>4</sup> found out that refractive error was unrelated to age, location or variant type in both male patients and female carriers of *RPGR* mutations. In our cohort, mean BCVA was  $0.26 \pm 0.49$  logMAR (range 0 to 2 logMAR) and mean SE was  $-3.19 \pm 5.67$  D, with 8 eyes (16.6%) presenting a SE lower than -6 D. As observed in previous studies,<sup>11,23</sup> a negative correlation was found between SE and BCVA. Four females (16.6%) had a BCVA below 20/200 (logMAR 1.0) in at least one eye. This is similar to what was observed by Talib et al (13%),<sup>11</sup> but

higher than reported by an earlier cohort (2%).<sup>6</sup> As expected, the most advanced imaging phenotypes were associated with lower BCVA in all imaging methods. A positive correlation was also found between older age and more severe phenotypes. Visual function decline over time in *RPGR* heterozygotes has been observed by others,<sup>4,6,11,12</sup> which is in agreement with our findings. Nevertheless, the cross-sectional nature of our study precludes us from formulating definite conclusions regarding disease progression with age.

In families with more than 1 *RPGR* heterozygote (n=5), intrafamilial heterogeneity was observed in 4. The pathogenic c.1243\_1244del p.(Arg415Glyfs\*37) variant was found in 5 females from 3 unrelated pedigrees. Phenotypes ranged from normal to male-type (Table 2), irrespective of the pedigree. Unlike Talib et al<sup>11</sup> we did not find a family-based aggregation of affected heterozygotes. Inter- and intrafamilial phenotypical variability was observed, likely due to a combination of skewed X-inactivation and genetic and/or environmental modifiers. Nanda et al<sup>2</sup> found that the FAF pattern was the same between the two eyes in all their 23 cases. In our study, intraindividual asymmetry was found in 5 females (20.83%) on UW-CFP and on 6 females (25%) on UW-FAF and macular SD-OCT grading (Table 2). Left–right asymmetry in X-chromosome inactivation in several paired structures of the body, such as the retina, has been reported. Although this has been at least partially attributed to the role of X-chromosome inactivation, the biological basis remains to be fully elucidated.<sup>7,11</sup> Other possible explanations include those commonly found in other X-linked recessive disorders such as X chromosome abnormalities, multiple interacting loci, modifier genes, epigenetic changes, threshold phenomena, and unidentified additional mutations.<sup>6</sup>

In our cohort, 56.25% (n=27) of eyes presented changes on fundus appearance (i.e. UW-CFP classification  $\geq 1$ ), with 9 eyes (18.75%) displaying grade 3 changes (Table 2). An abnormal FAF (i.e. UW-FAF classification  $\geq 2$ ) was present in 43 eyes (89.58%). The R-phenotype (grade 2) was the most commonly observed (23 eyes, 47.92%). This particular FAF phenotype is a sensitive diagnostic feature of the XLRP female carrier status.<sup>2,3,24</sup> Similar to previous descriptions,<sup>2,11</sup> we found that the R-phenotype may be observed even in females who have no TLR on funduscopy. Most impressively, seven women (29.17%) presented a M-phenotype (grade 4) on UW-FAF in at least one eye (Table 2), reinforcing that clinically severe phenotypes are not uncommon in female carriers. This number is higher than reported by Nanda et al (13.04%) but closer to Talib et al,<sup>11</sup> where 23% of heterozygotes displayed a complete RP or COD/CORD phenotype. We are aware that the high frequency of females presenting with a M-phenotype in our cohort may result from a selection bias. These females are more likely to have visual symptoms and thus more likely to be referred to an IRD clinic, whereas heterozygotes without signs or symptoms may never seek specialist advice from a geneticist or ophthalmologist. The high number of females presenting with male-type disease underlines the importance of genetic

testing (including the difficult-to-study ORF15 region) as dominant inheritance could be wrongly presumed in some pedigrees.<sup>9</sup>

Regarding macular SD-OCT, loss of integrity of the outer retinal layers was observed in 1/3 of eyes (n=16). Seven eyes showed atrophy of the outer retinal layers outside the central 1-mm, while 9 eyes showed loss of integrity of the EZ and ELM affecting the central 1-mm (5 of which had subfoveal involvement). Similarly, Talib et al<sup>11</sup> reported 4 eyes from 2 heterozygotes with center-involving outer retinal atrophy in their cohort of 47 heterozygotes.

Quantification of pRNFL thickness in *RPGR*-heterozygotes revealed that mean global pRNFL thickness was not increased but a section-wise temporal pRNFL thickening was found in comparison with the Spectralis® normative database. A recent study with *RPGR*-associated XLRP male patients found an overall increase in pRNFL thickness and section-wise thickening in all patients.<sup>14</sup> Interestingly, RNFL thickening was more prominent in the temporal than in the nasal sections and was independent of refraction error. We found a correlation between the UW-FAF classification and the pRNFL thickness in the temporal sector ( $p = 0.003$ ). Thus, *RPGR*-heterozygotes presenting with advanced male-like phenotypes appear to have increased temporal RNFL thickness, which is in agreement with the *RPGR*-associated XLRP male study.<sup>14</sup> Neuronal-glia remodeling associated with outer retinal atrophy or altered metabolic signaling, blood vessel architecture of the inner retina, or yet unknown factors have been proposed as explanations for the increased pRNFL thickness in RP.<sup>13,14,25,26</sup>

We found no correlation between macular inner retinal layer thickness and BCVA, UW-FAF, UW-CFP or SD-OCT classifications, showing that the inner retinal layers are preserved in *RPGR* heterozygotes across phenotypes. This is important since the status of the retinal inner layers is crucial for patients qualifying for gene replacement therapies, retinal implants, optogenetic approaches, or induced-pluripotent stem cells. Inclusion of severely affected female *RPGR*-mutation carriers in gene therapy trials is still a matter of debate, as well as which outcome measures would provide the most sensitive detection of treatment effect.<sup>2,11</sup> Considering that heterozygotes presenting with a male-type phenotype closely mimic the changes seen in *RPGR*-associated XLRP in males, we believe that this particular subset of female carriers should definitely be considered for future therapeutic approaches such as gene replacement therapies. This opinion is shared by others,<sup>2,9,11,27</sup> so hopefully female patients with a male-type phenotype will have the opportunity to be recruited to *RPGR* gene therapy trials in a near future.

This study has several limitations. First, its cross-sectional design prevents drawing conclusions about disease progression. Second, we are aware of the potentially limited statistical power due to the low number of included patients, a common challenge in rare diseases. Third, in most cases of our cohort, functional testing was limited to BCVA. Other visual function tests such as visual fields and electrophysiology testing could contribute to expand the phenotypical

spectrum of retinal degeneration in *RPGR*-mutation heterozygotes. Nevertheless, we were able to collect detailed clinical, genetic, visual acuity and multimodal imaging data in a cohort of 48 eyes from 24 *RPGR*-mutation carrier females. We reported for the first time 3 novel clinically significant variants and used UWF imaging to grade CFP and FAF according to established classifications. Additionally, our study provides novel insights into pRNFL changes seen in *RPGR* female carriers. Even though we were not able to elucidate why this happens beyond a reasonable doubt and rely mostly on previous speculative mechanisms to attempt an explanation, our findings may have implications for ongoing and future trials.

In conclusion, as ophthalmology takes a deep dive into precision medicine, standardized phenotyping, as seen in this study, is of extreme importance for patient selection and outcome measurements in clinical trials, but also for patient counseling on their future disease course. Prospective natural history studies with larger cohorts are needed to better characterize disease progression in *RPGR*-mutation female carriers, including pRNFL thickness changes over time, and eventually establish genotype-phenotype correlations.

## REFERENCES

1. Verbakel SK, van Huet RAC, Boon CJF, et al. Non-syndromic retinitis pigmentosa. *Prog Retin Eye Res* 2018;66:157-186. DOI: 10.1016/j.preteyeres.2018.03.005.
2. Nanda A, Salvetti AP, Clouston P, Downes SM, MacLaren RE. Exploring the Variable Phenotypes of *RPGR* Carrier Females in Assessing their Potential for Retinal Gene Therapy. *Genes (Basel)* 2018;9(12). DOI: 10.3390/genes9120643.
3. De Silva SR, Arno G, Robson AG, et al. The X-linked retinopathies: Physiological insights, pathogenic mechanisms, phenotypic features and novel therapies. *Prog Retin Eye Res* 2021;82:100898. DOI: 10.1016/j.preteyeres.2020.100898.
4. Yang J, Zhou L, Ouyang J, et al. Genotype-Phenotype Analysis of *RPGR* Variations: Reporting of 62 Chinese Families and a Literature Review. *Front Genet* 2021;12:600210. DOI: 10.3389/fgene.2021.600210.
5. Jacobson SG, Yagasaki K, Feuer WJ, Roman AJ. Interocular asymmetry of visual function in heterozygotes of X-linked retinitis pigmentosa. *Exp Eye Res* 1989;48(5):679-91. DOI: 10.1016/0014-4835(89)90009-2.
6. Comander J, Weigel-DiFranco C, Sandberg MA, Berson EL. Visual Function in Carriers of X-Linked Retinitis Pigmentosa. *Ophthalmology* 2015;122(9):1899-906. DOI: 10.1016/j.optha.2015.05.039.
7. Fahim AT, Daiger SP. The Role of X-Chromosome Inactivation in Retinal Development and Disease. *Adv Exp Med Biol* 2016;854:325-31. DOI: 10.1007/978-3-319-17121-0\_43.

8. Fahim AT, Sullivan LS, Bowne SJ, et al. X-Chromosome Inactivation Is a Biomarker of Clinical Severity in Female Carriers of RPGR-Associated X-Linked Retinitis Pigmentosa. *Ophthalmol Retina* 2020;4(5):510-520. DOI: 10.1016/j.oret.2019.11.010.
9. Salvetti AP, Nanda A, MacLaren RE. RPGR-Related X-Linked Retinitis Pigmentosa Carriers with a Severe "Male Pattern". *Ophthalmologica* 2021;244(1):60-67. DOI: 10.1159/000503687.
10. Kilgore DA, Kilgore TA, Sukpraprut-Braaten S, Schaefer GB, Uwaydat SH. Multimodal imaging of an RPGR carrier female. *Ophthalmic Genet* 2021;42(3):312-316. DOI: 10.1080/13816810.2021.1881981.
11. Talib M, van Schooneveld MJ, Van Cauwenbergh C, et al. The Spectrum of Structural and Functional Abnormalities in Female Carriers of Pathogenic Variants in the RPGR Gene. *Invest Ophthalmol Vis Sci* 2018;59(10):4123-4133. DOI: 10.1167/iovs.17-23453.
12. Grover S, Fishman GA, Anderson RJ, Lindeman M. A longitudinal study of visual function in carriers of X-linked recessive retinitis pigmentosa. *Ophthalmology* 2000;107(2):386-96. DOI: 10.1016/s0161-6420(99)00045-7.
13. Aleman TS, Cideciyan AV, Sumaroka A, et al. Inner retinal abnormalities in X-linked retinitis pigmentosa with RPGR mutations. *Invest Ophthalmol Vis Sci* 2007;48(10):4759-65. DOI: 10.1167/iovs.07-0453.
14. Birtel TH, Birtel J, Hess K, et al. Analysis of imaging biomarkers and retinal nerve fiber layer thickness in RPGR-associated retinitis pigmentosa. *Graefes Arch Clin Exp Ophthalmol* 2021;259(12):3597-3604. DOI: 10.1007/s00417-021-05233-w.
15. Gao H, Huang X, He J, Zou T, Chen X, Xu H. The roles of microglia in neural remodeling during retinal degeneration. *Histol Histopathol* 2021:18384. DOI: 10.14670/HH-18-384.
16. Marques JP, Carvalho AL, Henriques J, Murta JN, Saraiva J, Silva R. Design, development and deployment of a web-based interoperable registry for inherited retinal dystrophies in Portugal: the IRD-PT. *Orphanet J Rare Dis* 2020;15(1):304. DOI: 10.1186/s13023-020-01591-6.
17. Richards S, Aziz N, Bale S, et al. Standards and guidelines for the interpretation of sequence variants: a joint consensus recommendation of the American College of Medical Genetics and Genomics and the Association for Molecular Pathology. *Genet Med* 2015;17(5):405-24. DOI: 10.1038/gim.2015.30.
18. Landis JR, Koch GG. The measurement of observer agreement for categorical data. *Biometrics* 1977;33(1):159-74.
19. Andreasson S, Breuer DK, Eksandh L, et al. Clinical studies of X-linked retinitis pigmentosa in three Swedish families with newly identified mutations in the RP2 and



- RPGR-ORF15 genes. *Ophthalmic Genet* 2003;24(4):215-23. DOI: 10.1076/opge.24.4.215.17228.
20. Li HP, Yuan SQ, Wang XG, Sheng XL, Li XR. Myopia with X-linked retinitis pigmentosa results from a novel gross deletion of RPGR gene. *Int J Ophthalmol* 2020;13(8):1306-1311. DOI: 10.18240/ijo.2020.08.18.
  21. Al-Maskari A, O'Grady A, Pal B, McKibbin M. Phenotypic progression in X-linked retinitis pigmentosa secondary to a novel mutation in the RPGR gene. *Eye (Lond)* 2009;23(3):519-21. DOI: 10.1038/eye.2008.427.
  22. Hendriks M, Verhoeven VJM, Buitendijk GHS, et al. Development of Refractive Errors-What Can We Learn From Inherited Retinal Dystrophies? *Am J Ophthalmol* 2017;182:81-89. DOI: 10.1016/j.ajo.2017.07.008.
  23. Sanchez Tocino H, Diez Montero C, Villanueva Gomez A, Lobo Valentin R, Montero-Moreno JA. Phenotypic high myopia in X-linked retinitis pigmentosa secondary to a novel mutation in the RPGR gene. *Ophthalmic Genet* 2019;40(2):170-176. DOI: 10.1080/13816810.2019.1605385.
  24. Ogino K, Oishi M, Oishi A, et al. Radial fundus autofluorescence in the periphery in patients with X-linked retinitis pigmentosa. *Clin Ophthalmol* 2015;9:1467-74. DOI: 10.2147/OPHTH.S89371.
  25. Vecino E, Rodriguez FD, Ruzafa N, Pereiro X, Sharma SC. Glia-neuron interactions in the mammalian retina. *Prog Retin Eye Res* 2016;51:1-40. DOI: 10.1016/j.preteyeres.2015.06.003.
  26. Rattner A, Nathans J. The genomic response to retinal disease and injury: evidence for endothelin signaling from photoreceptors to glia. *J Neurosci* 2005;25(18):4540-9. DOI: 10.1523/JNEUROSCI.0492-05.2005.
  27. Martinez-Fernandez De La Camara C, Nanda A, Salvetti AP, Fischer MD, MacLaren RE. Gene therapy for the treatment of X-linked retinitis pigmentosa. *Expert Opin Orphan Drugs* 2018;6(3):167-177. DOI: 10.1080/21678707.2018.1444476.



Manuscript 11

**3.5. Frequency of cystoid macular edema and vitreomacular interface disorders in genetically solved syndromic and non-syndromic Retinitis Pigmentosa**

João Pedro Marques

Emmanuel Neves

Sara Geda

Ana Luísa Carvalho

Joaquim Murta

Jorge Saraiva

Rufino Silva

*Published in: Graefes Arch Clin Exp Ophthalmol. 2022 Sep;260(9):2859-2866.*

## **ABSTRACT**

### **Purpose**

Retinitis Pigmentosa (RP) corresponds to a group of inherited retinal disorders where progressive rod-cone degeneration is observed. Cystoid macular edema (CME) and vitreomacular interface disorders (VMID) are known to complicate the RP phenotype, challenging an age-old concept of retained central visual acuity. The reported prevalence of these changes varies greatly among different studies. We aim to describe the frequency of CME and VMID and identify predictors of these changes in a cohort of Caucasian patients with genetically solved syndromic (sRP) and non-syndromic RP (nsRP).

### **Methods**

Cross-sectional study of patients with genetically solved sRP or nsRP. Genetic testing was clinically oriented in all probands and coordinated by a medical geneticist. The presence/absence of CME and VMIDs such as epiretinal membrane (ERM), vitreomacular traction (VMT), lamellar hole (LH), macular hole (MH), and macular pseudohole (MPH), as well as the integrity of the neurosensory retina and retinal pigment epithelium were evaluated in individual macular SD-OCT b-scans. Mixed-effects regression analysis models were used to identify significant predictors of BCVA, CME and VMID. Significance was considered at  $\alpha < 0.05$ .

**Results** We included 250 eyes from 125 patients. Mean age was  $44.9 \pm 15.7$  years and 55.2% were male. Eighty-eight patients had nsRP and 37 had sRP. Median BCVA was 0.5 (0.2-1.3) logMAR. CME was found in 17.1% of eyes, while ERM was found in 54.3% of eyes. The frequency of CME ( $p=0.45$ ) and ERM ( $p=0.07$ ) did not differ between sRP and nsRP patients, nor across different inheritance patterns. Mixed-effects univariate linear regression identified age ( $p=0.04$ ), cataract surgery ( $p < 0.01$ ), and loss of integrity of outer retinal layers ( $p < 0.01$ ) as significant predictors of lower visual acuity, while increased foveal thickness ( $p < 0.01$ ) and the presence of CME ( $p=0.04$ ) were predictors of higher visual acuity. On mixed-effects multivariable analysis, only increased foveal thickness was significantly associated with better visual acuity ( $p < 0.01$ ).

### **Conclusion**

We found that the burden of ERM and CME in RP patients is high, highlighting the importance of screening for these potentially treatable conditions to improve the quality-of-life of RP patients.

## INTRODUCTION

Retinitis Pigmentosa (RP) corresponds to a group of inherited retinal disorders where progressive rod-cone degeneration is observed. Classically, this takes place in a concentric, bilateral, and symmetric way, sparing the central vision until late in the disease course.<sup>1</sup> Considering the phenotypical heterogeneity that characterizes RP, this reductive concept has become increasingly challenged. Threats to central visual acuity in RP patients may include macular atrophy, choroidal neovascularization, cystoid macular edema (CME), and vitreomacular interface disorders (VMID). Specifically, the association between cystoid macular edema (CME) and RP has been known for quite some time.<sup>2</sup> With the enhancement of optical coherence tomography (OCT) platforms, imaging of the vitreomacular interface improved substantially and recent studies began to look at VMID in RP patients.<sup>3-5</sup> The reported prevalence of CME and VMID varies greatly among different studies, probably because distinct OCT platforms and classifications are used. Additionally, most studies lack genetic information on the included patients, and data on the frequency of these changes in syndromic forms of RP is currently scarce.

Considering the detrimental effect that CME and VMID can have on central visual acuity, it is of utmost importance to screen RP patients for these potentially treatable complications. For instance, several studies have shown improvement of CME in RP following treatment with topical or oral carbonic anhydrase inhibitors (CAI).<sup>6-9</sup> A recent meta-analysis based on non-randomized controlled clinical studies demonstrated that RP patients with CME treated with CAI have better anatomical outcomes, even though the effect on visual acuity proved inconsistent across studies.<sup>10</sup> Regarding VMID, microincision vitrectomy surgery may ameliorate metamorphopsia and improve visual function in RP patients with epiretinal membrane (ERM) or vitreomacular traction syndrome.<sup>11,12</sup> Furthermore, as we enter an era of targeted gene therapies for RP, obtaining reference data on the prevalence of CME and VMID across different RP genotypes is warranted.

In this study, our primary aim was to describe the frequency of CME and VMID in a cohort of genetically solved syndromic and non-syndromic RP patients, routinely followed at an inherited retinal dystrophies (IRD) reference center in Portugal. Our secondary aim was to determine clinical predictors of BCVA, CME and VMID.

## METHODS

### ***Study Design and Diagnostic Criteria***

Cross-sectional study conducted at the Retinal Dystrophies Clinic and Medical Genetics Unit of *Centro Hospitalar e Universitário de Coimbra (CHUC)*, an IRD reference center and the only Portuguese healthcare provider represented in the European Reference Network for rare eye diseases (ERN-EYE) consortium. Consecutive patients with a clinical and genetic diagnosis of syndromic or non-syndromic RP were identified using the IRD-PT registry.<sup>13</sup> Informed consent was obtained for every included subject. The study was approved by the local Ethics Committee and followed the tenets of the Declaration of Helsinki for biomedical research.

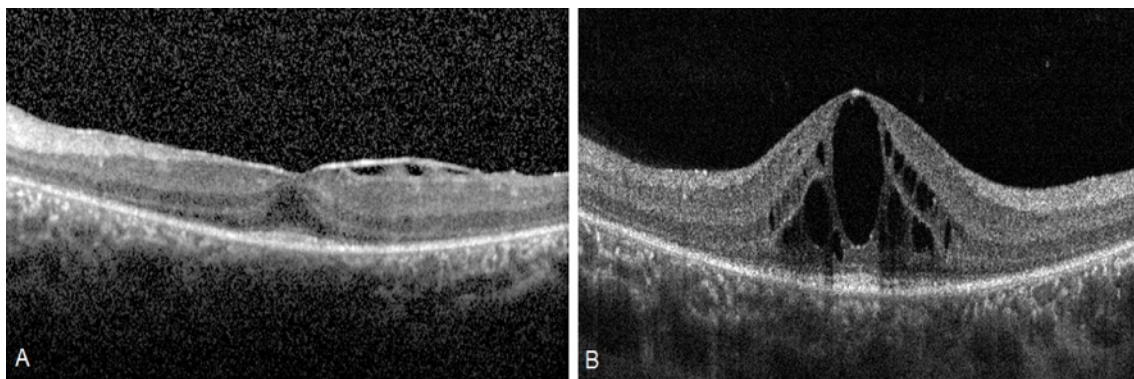
### ***Genetic testing***

Genetic testing was clinically oriented in all probands and coordinated by a medical geneticist from the Medical Genetics Unit of CHUC. A next-generation sequencing (NGS) approach was used, complemented by multiplex ligation-dependent probe amplification (MLPA) and/or sequencing of *RPGR-ORF15* when deemed necessary. Peripheral blood samples were collected from all probands and available relatives for genetic analysis. The genomic DNA was extracted using a genomic DNA extraction and purification kit based on the manufacturer's protocol. Variants were classified in accordance with the American College of Medical Genetics and Genomics (ACMG).<sup>14</sup> All variants classified as pathogenic (class V) or likely pathogenic (class IV) were further confirmed by Sanger sequencing. Whenever possible, segregation analysis was performed in family members. Published cDNA sequences for the identified genes were compared with the sequencing results. Genetic counselling provided by a medical geneticist was granted to all subjects.

### ***Data collection and grading***

Clinical and demographic data were collected from each individual patient file. All patients underwent a comprehensive ophthalmologic examination including best-corrected visual acuity (BCVA, ETDRS letters), dilated slit-lamp anterior segment and fundus biomicroscopy performed by a single IRD specialist (JPM). Multimodal imaging included: seven standard 45°-field colour fundus photographs (CFP) taken with a Nikon Digital SLR Camera D7000 (Nikon Corporation, Japan) mounted on either a TRC-NW7SF or TRC-NW8 Mark II Retinal Camera (Topcon Corporation, Japan), ultrawidefield (UWF) fundus and FAF imaging (Optos California, Optos GmbH, Germany), and spectral-domain optical coherence tomography (SD-OCT, Spectralis, Heidelberg Engineering, Heidelberg, Germany or Avanti RTVue-XR 100, Optovue Inc, Fremont, CA, USA). ERM were graded according to the ERM SD-OCT classification proposed by Govetto

et al<sup>15</sup> (**Figure 1A**). Cystoid macular edema (CME) (**Figure 1B**), vitreomacular traction (VMT), lamellar hole (LH), macular hole (MH) and macular pseudo-hole (MPH) were classified according to the SD-OCT classification for macular diseases proposed by the E3 consortium.<sup>16</sup> The loss of integrity of the outer retinal layers and retinal pigment epithelium (RPE) at the central millimeter and central point was evaluated on SD-OCT horizontal and vertical b-scans. Posterior vitreous detachment (PVD) was classified on SD-OCT macular b-scans as: *attached* if the posterior hyaloid had any attachment in or around the fovea, *detached* if there was a visible complete detachment or *questionable* if we were unable to classify it as one of the former. Patients with low-quality SD-OCT scans due to nystagmus or significant media opacities were excluded from the SD-OCT analysis. All images were graded by two independent experienced medical graders (JPM and ERN). Disagreement was resolved by open adjudication.



**Figure 1.** Macular spectral domain optical coherence tomography (SD-OCT) horizontal b-scans of two non-syndromic retinitis pigmentosa (RP) patients. (A) Type II epiretinal membrane (note the loss of the foveal contour) in a patient with *RPGR*-associated X-linked RP. (B) Cystoid macular edema in a patient with *EYS*-associated autosomal-recessive RP.

### **Statistical analysis**

Continuous variables were expressed as mean  $\pm$  SD or median (IQR) when normally distributed or skewed, respectively. Categorical variables were expressed as proportions. Pearson's chi-square test was used for analysis of categorical outcome variables. We used generalized mixed effects regression analysis to study the effects of covariates on ocular outcomes, in this way accounting for inter-eye correlation. The  $\alpha$  level was set at 0.05. For statistical analysis, the software package used was STATA 14.0 (StataCorp. 2015. *Stata Statistical Software: Release 14*. College Station, TX: StataCorp LP).

## RESULTS

### Study population

We included 250 eyes from 125 patients (103 families), mean age  $44.9 \pm 15.7$  years. Of these, 88 (70 families) had non-syndromic RP while 37 (33 families) had syndromic RP. Although there was no difference between BCVA ( $p=0.82$ ) and gender (0.535) between syndromic and non-syndromic patients, syndromic patients were significantly younger ( $p<0.01$ ). Please refer to **Table I and Supplementary Table I** for further baseline information.

**Table I.** Baseline characteristics of the study population.

Patients (n)	125
Eyes (n)	250
Gender (n; %)	
Female	56 (44.8)
Male	69 (55.2)
Age (mean $\pm$ SD)	$44.9 \pm 15.7$
BCVA logMAR (median; IQR)	0.5 (0.2-1.3)
Syndromic RP (n; %)	37 (29.6)
Non-Syndromic RP (n; %)	88 (70.4)

**Supplementary Table I.** Baseline characteristics of the study population according to syndromic status.

	Syndromic RP (n=37)	Non-Syndromic RP (n=88)	p value
Female	15 (40.5)	41 (53.4)	0.535
Male	22 (59.5)	47 (46.6)	
Age (mean $\pm$ SD)	$39.2 \pm 14.3$	$47.2 \pm 15.8$	<0.01
BCVA logMAR (median; IQR)	0.5 (1.2)	0.5 (1.1)	0.91

### Genetic information

Autosomal recessive inheritance was the most frequently observed inheritance pattern (87 families, 78.4% of patients), followed by X-linked (9 families, 15.2% of patients), and autosomal dominant (7 families, 6.4% of patients). In non-syndromic RP, disease-causing genotypes were distributed across 20 different genes. Mutations in *EYS* (26 families), *RPGR* (7



families), and *CNGB1* (6 families) explained 60.3% of cases. On the other hand, in syndromic RP, disease-causing genotypes were distributed across 13 different genes and mutations in *USH2A* (7 families), *MYO7A* (5 families), and *BBS10* (4 families) explained 54% of cases. Of note, *USH2A* mutations were found both in cases of syndromic and non-syndromic RP. In syndromic RP patients, Usher syndrome was the most frequent diagnosis (21/37), followed by Bardet-Biedl (9/37), and Neurodegeneration with brain iron accumulation (NBIA; 4/37). Please refer to **Supplementary Tables 2 and 3** for information on the genotypes.

**Supplementary Table 2.** Diagnoses, genes and number of patients and families in the syndromic RP group.

Diagnosis	Gene, n (%)	Affected patients, n (%)	Affected families, n
Usher Syndrome Type II	<i>USH2A</i>	9 (24.3)	7
Usher Syndrome Type I	<i>MYO7A</i>	6 (16.2)	5
Bardet-Biedl Syndrome	<i>BBS10</i>	5 (13.5)	4
Neurodegeneration with brain iron accumulation	<i>PANK2</i>	4 (10.8)	4
Usher Syndrome Type I	<i>CDH23</i>	3 (8.1)	3
Bardet-Biedl Syndrome	<i>BBS1</i>	3 (8.1)	3
Usher Syndrome Type I	<i>USH1G</i>	1 (2.7)	1
Jalili Syndrome	<i>CNNM4</i>	1 (2.7)	1
Usher Syndrome Type II	<i>ADGVR1</i>	1 (2.7)	1
Senior-Loken Syndrome	<i>NPHP1</i>	1 (2.7)	1
Bardet-Biedl Syndrome	<i>TTC8</i>	1 (2.7)	1
Usher Syndrome Type I	<i>PCDH15</i>	1 (2.7)	1
Bone Marrow Failure Syndrome type III	<i>DNAJC21</i>	1 (2.7)	1

**Supplementary Table 3.** Genes and number of patients and families in the non-syndromic RP group.

Gene, n (%)	Affected patients, n (%)	Affected families, n
<i>EYS</i>	28 (31.8)	26
<i>RPGR</i>	18 (20.5)	7
<i>CNGB1</i>	7 (8.0)	6
<i>IMPG2</i>	6 (6.8)	4
<i>NR2E3</i>	5 (5.7)	5
<i>RHO</i>	4 (4.6)	3
<i>RPE65</i>	4 (4.6)	3

<i>RDH12</i>	3 (3.4)	3
<i>PROM1</i>	2 (2.3)	2
<i>USH2A</i>	2 (2.3)	2
<i>MERTK</i>	2 (2.3)	2
<i>BBS2</i>	1 (1.1)	1
<i>PCARE</i>	1 (1.1)	1
<i>RP2</i>	1 (1.1)	1
<i>WDR19</i>	1 (1.1)	1
<i>PD6EB</i>	1 (1.1)	1
<i>PD6EA</i>	1 (1.1)	1
<i>OTX2</i>	1 (1.1)	1

### **Lens status**

Of 250 eyes, 79 (31.6%) had a clinically detectable cataract while 86 (34.4%) had been submitted to cataract surgery. Additionally, 66.2% (n=51) of cataracts were classified as posterior subcapsular cataracts. Finally, 85 eyes (34.0%) had no clinically detectable lens opacity.

### **Vitreomacular interface disorders**

Forty eyes were excluded from the SD-OCT analysis due to low quality scans. The overall frequency of ERM was 54.3% (n=114/210 eyes), most of which corresponded to stages 1 and 2 (97.4%) of the Govetto classification.[15] CME was found in 17.1% (36/210 eyes), while LH was only identified in 2 eyes, and VMT was observed in 3 eyes.

Considering non-syndromic RP cases, ERM affected 59.3% (86/145) of eyes, while CME was found in 15.9% (23/145) of eyes. There was SD-OCT evidence of complete PVD in 9% (13/145) of eyes, while in 69.6% (101/145) the vitreous remained attached in the posterior pole. For 21.4% (31/145) of patients the status of the posterior vitreous was deemed questionable as it was not possible to clearly assert whether it was fully attached or fully detached but not visible on b-scans.

In syndromic RP cases, ERM affected 43.1% (28/65) of eyes and CME affected 20% (13/65) of eyes. Regarding the status of the posterior vitreous, complete PVD was found in 1.5% (1/65) of eyes, and it was attached in 84.6% (55/65) of eyes. For 13.8% (9/65) of eyes, the status of the vitreous was deemed as questionable. Please refer to **Table 2** for more details. For a description of VMID and CME according to genotype please refer to **Supplementary Table 4**.

**Table 2.** Frequency of vitreomacular interface features in the study population.

	Per patient (n=106)	Per eye (n=210)
<b>Cystoid macular edema (%)</b>	24.5	17.1
<b>Epiretinal membrane (%)</b>	64.5	54.3
<b>Stage I</b>		92.1
<b>Stage II</b>		5.3
<b>Stage III</b>		2.6
<b>Stage IV</b>		0
<b>Vitreomacular traction (%)</b>	2.8	1.4
<b>Lamellar hole (%)</b>	1.9	1.0
<b>Macular hole (%)</b>	0	0
<b>Pseudomacular hole (%)</b>	0	0
<b>Posterior vitreous detachment</b>		
<b>Attached (%)</b>	69.8	74.2
<b>Detached (%)</b>	12.3	6.7
<b>Questionable (%)</b>	17.9	19.1

**Supplementary Table 4.** Frequency of eyes affected with VMID and CME according to genotype.

Gene	VMID			CME % (n)
	ERM % (n)	LH % (n)	VMT % (n)	
EYS	30.7% (n=35)	100% (n=2)	66.7% (n=2)	27.8% (n=10)
USH2A	11.4% (n=13)	0% (n=0)	0% (n=0)	16.7% (n=6)
RPGR	9.6% (n=11)	0% (n=0)	0% (n=0)	16.7% (n=6)
CNGBI	7.9% (n=9)	0% (n=0)	33.3% (n=1)	11.1% (n=4)
MYO7A	7.0% (n=8)	0% (n=0)	0% (n=0)	8.3% (n=3)
RPE65	5.3% (n=6)	0% (n=0)	0% (n=0)	0% (n=0)
IMPG2	5.3% (n=6)	0% (n=0)	0% (n=0)	0% (n=0)
RHO	4.4% (n=5)	0% (n=0)	0% (n=0)	2.8% (n=1)

<i>CDH23</i>	2.6% (n=3)	0% (n=0)	0% (n=0)	5.6% (n=2)
<i>BBS10</i>	1.8% (n=2)	0% (n=0)	0% (n=0)	0% (n=0)
<i>RDH12</i>	1.8% (n=2)	0% (n=0)	0% (n=0)	0% (n=0)
<i>BBS2</i>	1.8% (n=2)	0% (n=0)	0% (n=0)	0% (n=0)
<i>PCARE</i>	1.8% (n=2)	0% (n=0)	0% (n=0)	2.8% (n=1)
<i>RP2</i>	1.8% (n=2)	0% (n=0)	0% (n=0)	0% (n=0)
<i>ADGVR1</i>	1.8% (n=2)	0% (n=0)	0% (n=0)	0% (n=0)
<i>WDR13</i>	1.8% (n=2)	0% (n=0)	0% (n=0)	0% (n=0)
<i>PANK2</i>	0.9% (n=1)	0% (n=0)	0% (n=0)	2.8% (n=1)
<i>PROM1</i>	0.9% (n=1)	0% (n=0)	0% (n=0)	0% (n=0)
<i>BBS1</i>	0.9% (n=1)	0% (n=0)	0% (n=0)	0% (n=0)
<i>PCDH15</i>	0.9% (n=1)	0% (n=0)	0% (n=0)	0% (n=0)
<i>NR2E3</i>	0% (n=0)	0% (n=0)	0% (n=0)	2.8% (n=1)
<i>USH1G</i>	0% (n=0)	0% (n=0)	0% (n=0)	2.8% (n=1)
<b>TOTAL, n</b>	<b>114</b>	<b>2</b>	<b>3</b>	<b>36</b>

VMID – vitreomacular interface disorder; ERM – epiretinal membrane; LH – lamellar hole; VMT – vitreomacular traction; CME – cystoid macular edema

### ***Integrity of outer retinal layers and retinal pigment epithelium***

Loss of integrity of the outer retinal layers in the central millimeter was observed in 71.4% (n=150/210) of eyes, 38.0% of those (n=57/150) affecting the central point. On the other hand, there was atrophy of the RPE affecting the central millimeter in 33.3% (n=70/210) of eyes, with center involvement in 60.0% (n=42/70) of these.

### ***Univariate and Multivariate regression analysis***

We conducted mixed-effects univariate linear and logistic regression models to identify significant predictors of BCVA (**Table 3**), ERM (**Table 4**), and CME (**Table 5**), respectively. Foveal thickness ( $\beta$  -0.03; [-0.04; -0.02];  $p < 0.01$ ), CME ( $\beta$  -0.23; [-0.46; <-0.01];  $p = 0.04$ ), cataract surgery ( $\beta$  0.40; [0.13-0.66];  $p < 0.01$ ), and loss of integrity of outer retinal layers ( $\beta$  0.34; [0.1-0.58];  $p < 0.01$ ) were initially found to be significantly associated with BCVA. On mixed-effects multivariable linear regression analysis, only foveal thickness ( $\beta$  -0.03; [-0.04; -0.01];  $p < 0.01$ ) was significantly associated with BCVA (**Supplementary Table 5**).

**Table 3.** Mixed-effects linear regression analysis for the outcome BCVA (logMAR)

Predictor variable	$\beta$ Coefficient	P value	Lower 95% CI	Upper 95% CI
Age	0.01	<b>0.04</b>	<0.01	0.02
Foveal thickness <sup>a</sup>	-0.03	<b>&lt;0.01</b>	-0.04	-0.02
Loss of integrity of outer retinal layers	0.34	<b>&lt;0.01</b>	0.1	0.58
Gender (male)	0.14	0.39	-0.18	0.47
Cataract surgery	0.40	<b>&lt;0.01</b>	0.13	0.66
CME	-0.23	<b>0.04</b>	-0.46	<-0.01
ERM	0.07	0.48	-0.12	0.25
Syndromic status	-0.02	0.91	-0.38	0.34
Inheritance pattern				
AD	-0.07	0.82	-0.74	0.59
AR	-0.35	0.12	-0.79	0.09
XL	0.30	0.13	-0.09	0.68

<sup>a</sup>Every 10  $\mu\text{m}$  increase in thickness

The  $\alpha$  level was set at 0.05. Statistically significant values are shown in bold

**Table 4.** Mixed-effects logistic regression analysis for the outcome ERM

Predictor variable	$\beta$ coefficient	P value	Lower 95% CI	Upper 95% CI
Age	0.03	0.38	-0.03	0.08
Gender (male)	1.65	0.08	-0.20	3.51
Cataract surgery	0.92	0.25	-0.66	2.49
Syndromic status	-1.77	0.07	-3.72	0.16
Inheritance pattern				
AD	-0.53	0.74	-3.72	2.65
AR	-1.47	0.22	-3.81	0.87
XL	1.30	0.21	-0.74	3.34

**Table 5.** Mixed-effects logistic regression analysis for the outcome CME.

Predictor variable	$\beta$ coefficient	P value	Lower 95% CI	Upper 95% CI
Age	-0.007	0.82	-0.07	0.05
Gender (male)	0.53	0.55	-1.20	2.26
Cataract surgery	-0.23	0.79	-1.89	1.44
Loss of integrity of outer retinal layers	-0.07	0.93	-1.69	1.55
Syndromic status	0.69	0.45	-1.12	2.50
Inheritance pattern				
AD	-1.69	0.38	-5.49	2.10
AR	0.91	0.43	-1.36	3.18
XL	-0.19	0.86	-2.23	1.86

**Supplementary Table 5.** Multivariable mixed-effects linear regression analysis for the outcome BCVA

Predictor variable	Coefficient	P value	Lower 95% CI	Upper 95% CI
Age	<0.01	0.74	<-0.01	0.01
Cataract surgery	0.20	0.10	-0.03	0.43
CME	-0.02	0.83	-0.23	0.19
Loss of integrity of external layers	0.13	0.21	-0.08	0.34
Foveal thickness <sup>a</sup>	-0.03	<0.01	-0.04	-0.01

<sup>a</sup>Every 10  $\mu$ m increase in thickness

## DISCUSSION

The main goal of this study was to assess and report the frequency of VMID and CME in a cohort of genetically solved syndromic and non-syndromic RP. As a secondary aim, we set to identify predictors of clinically significant variables (BCVA, VMID and CME).

We found that the burden of these conditions - particularly CME and ERM - is high both among syndromic and non-syndromic RP cases. Overall, ERMs were the most common form of VMID in our cohort, affecting over 50% of eyes. On the other hand, LH and VMT were relatively rare findings and the posterior vitreous remained attached in most patients, whether syndromic or non-syndromic.

Concerning the prevalence of ERM, our results are in agreement with recent studies that found it to be the most common VMID in RP.<sup>3,4,17</sup> Most corresponded to stage I of the Govetto SD-OCT classification<sup>15</sup>, i.e. without loss of the normal foveal contour. This fact probably explains why there was no statistically significant association between the presence of ERM and lower BCVA. Regarding predictors of ERM presence, we found no statistically significant association between ERM and age, history of cataract surgery or syndromic status. On the other hand, similar to Tan et al<sup>17</sup> we found that male patients showed a tendency toward having ERM, even though this did not reach statistical significance. Using time-domain OCT, Hagiwara et al<sup>5</sup> found that ERMs affected 0.6% of eyes. More recent papers using SD-OCT reported a higher prevalence of ERM in RP eyes. Testa et al<sup>4</sup> found that 15.6% of eyes had ERM. In their study, eyes with a clear lens had a significantly lower prevalence of ERM, while there was no relationship between ERM presence and biological gender or inheritance pattern. Cataract surgery was associated with a higher prevalence of VMID, although they did not study this relationship with ERM specifically. Fragiotta et al<sup>3</sup> found that ERM was the most frequent abnormality, being present in 15.5% of eyes and 84.4% of eyes with VMID. On longitudinal analysis, they found ERM to be associated with a significant loss of vision over 24 months. The frequency of ERM in our cohort seems considerably higher than previously reported. However, direct comparisons are limited by factors like different study populations, methods for retinal imaging and ERM classifications. One strength of our study is the use of a validated SD-OCT ERM classification.<sup>15</sup> A finding of clinical interest relates to the apparent dissociation between the prevalence of ERM and the status of the posterior vitreous. Like Fragiotta et al<sup>3</sup> we found that the posterior vitreous remained attached in most of our patients, suggesting that in RP patients the pathophysiology of ERM may, to some extent, be related to factors other than abnormal posterior vitreous detachment. Further studies are needed to corroborate this hypothesis.

The remaining types of VMID were relatively rare. LH was found in around 1% (2/210) of eyes, while VMT was found in 1.4% (3/210) of eyes. We did not find any macular holes or

macular pseudoholes. Our results seem to be in general agreement with those of previous works, in what concerns the order of magnitude of these changes. Hagiwara et al<sup>5</sup> found VMT in 0.8% of eyes and MH in 0.5% of RP eyes, while Testa et al<sup>4</sup> found VMT in 4.8%, LH in 1.0% and MH in 0.6% of RP eyes.

We found that 17.1% of study eyes (24.5% of patients) had CME. CME was one of the earliest macular changes in RP to be reported in the literature, perhaps because of the easier diagnosis in the pre-OCT era as compared to VMID. Using fluorescein angiography, Fishman et al<sup>2</sup> found CME in around 15% of RP patients. With the use of OCT, estimates of CME prevalence have changed to some degree. Using TD-OCT, Hirakawa et al<sup>18</sup> found “cystoid lesions” in 13% of RP patients while Hagiwara et al<sup>5</sup> found CME in 5.5% of patients. Using Fourier-domain (FD)-OCT, Hajali et al<sup>19</sup> found that 38% and 27% of patients had CME in one or both eyes, respectively, with no apparent association between the inheritance pattern and frequency of CME. In a study of patients without apparent cystic changes on fundus examination<sup>20</sup> the same group reported that 32% and 18% of patients had CME in one or both eyes, respectively. More recently, using SD-OCT, Tan et al<sup>17</sup> reported CME in 18.4% of eyes in a population from Western China. Regarding studies conducted in Europe, recent estimates vary from 20.4% to 50.9% of eyes.<sup>3,4,21</sup> Testa et al<sup>4</sup> reported that CME was significantly associated with female gender, autosomal dominant inheritance and was less likely to exist in pseudophakic patients. Similarly, Liew et al<sup>21</sup> found that CME was more likely to be found in autosomal dominant forms of RP as opposed to X-linked forms. They also found that it was more likely to occur in younger patients and less likely to occur in the presence of ERM or cataract. In our cohort, age, gender, cataract surgery, syndromic status, inheritance pattern, and loss of integrity of outer retinal layers were not significantly associated with the presence of CME.

Regarding predictors of BCVA, univariate mixed-effects regression analyses revealed several statistically significant predictors, but on multivariable analysis, the only predictor significantly associated with BCVA was foveal thickness (i.e., increased retinal thickness was associated with better visual acuity). This supports the clinical notion that patients with thinner retinas, suffering from long-standing degeneration have worse visual acuity.

Limitations of this study include its cross-sectional nature, hampering cause-effect evaluation, and the scattered genotype distribution, making it impossible to establish genotype-phenotype correlations. Additionally, the fact that we conducted this study in a retinal dystrophies referral center may have introduced a referral bias, possibly increasing the prevalence of macular changes in our cohort. On the other hand, this is the first study of its kind to only include patients with a genetically confirmed diagnosis and to report findings of both syndromic and non-syndromic RP. Furthermore, we graded VMID and CME according to validated OCT classifications and used SD-OCT, which allows better visualization of VMID in



comparison to time-domain and fourier-domain OCT systems used in earlier studies. This study helps strengthen our knowledge of macular disorders in genetically solved syndromic and non-syndromic RP patients, allowing more precise estimation of the prevalence of these changes, and facilitating further study designs.

In conclusion, we found that the burden of ERM and CME in syndromic and non-syndromic RP is high, highlighting the importance of screening for these potentially treatable conditions to improve quality-of-life of RP patients.

## REFERENCES

1. Hartong DT, Berson EL, Dryja TP. Retinitis pigmentosa. *Lancet* 2006;368(9549):1795-809. DOI: 10.1016/S0140-6736(06)69740-7.
2. Fishman GA, Maggiano JM, Fishman M. Foveal lesions seen in retinitis pigmentosa. *Arch Ophthalmol* 1977;95(11):1993-6. DOI: 10.1001/archophth.1977.04450110087008.
3. Fragiotta S, Rossi T, Carnevale C, et al. Vitreo-macular interface disorders in retinitis pigmentosa. *Graefes Arch Clin Exp Ophthalmol* 2019;257(10):2137-2146. DOI: 10.1007/s00417-019-04418-8.
4. Testa F, Rossi S, Colucci R, et al. Macular abnormalities in Italian patients with retinitis pigmentosa. *Br J Ophthalmol* 2014;98(7):946-50. DOI: 10.1136/bjophthalmol-2013-304082.
5. Hagiwara A, Yamamoto S, Ogata K, et al. Macular abnormalities in patients with retinitis pigmentosa: prevalence on OCT examination and outcomes of vitreoretinal surgery. *Acta Ophthalmol* 2011;89(2):e122-5. DOI: 10.1111/j.1755-3768.2010.01866.x.
6. Huckfeldt RM, Comander J. Management of Cystoid Macular Edema in Retinitis Pigmentosa. *Semin Ophthalmol* 2017;32(1):43-51. DOI: 10.1080/08820538.2016.1228404.
7. Liew G, Moore AT, Webster AR, Michaelides M. Efficacy and prognostic factors of response to carbonic anhydrase inhibitors in management of cystoid macular edema in retinitis pigmentosa. *Invest Ophthalmol Vis Sci* 2015;56(3):1531-6. DOI: 10.1167/iovs.14-15995.
8. Genead MA, Fishman GA. Efficacy of sustained topical dorzolamide therapy for cystic macular lesions in patients with retinitis pigmentosa and usher syndrome. *Arch Ophthalmol* 2010;128(9):1146-50. DOI: 10.1001/archophthalmol.2010.172.
9. Strong S, Liew G, Michaelides M. Retinitis pigmentosa-associated cystoid macular oedema: pathogenesis and avenues of intervention. *Br J Ophthalmol* 2017;101(1):31-37. DOI: 10.1136/bjophthalmol-2016-309376.

10. Huang Q, Chen R, Lin X, Xiang Z. Efficacy of carbonic anhydrase inhibitors in management of cystoid macular edema in retinitis pigmentosa: A meta-analysis. *PLoS One* 2017;12(10):e0186180. DOI: 10.1371/journal.pone.0186180.
11. Vingolo EM, Gerace E, Valente S, Spadea L, Nebbioso M. Microincision vitrectomy surgery in vitreomacular traction syndrome of retinitis pigmentosa patients. *Biomed Res Int* 2014;2014:537081. DOI: 10.1155/2014/537081.
12. Yan F, Xia FJ, Jiang F, Yu HG. Visual and morphological outcomes of vitreomacular traction syndrome in retinitis pigmentosa treated by vitrectomy. *Int J Ophthalmol* 2018;11(8):1411-1415. DOI: 10.18240/ijo.2018.08.25.
13. Marques JP, Carvalho AL, Henriques J, Murta JN, Saraiva J, Silva R. Design, development and deployment of a web-based interoperable registry for inherited retinal dystrophies in Portugal: the IRD-PT. *Orphanet J Rare Dis* 2020;15(1):304. DOI: 10.1186/s13023-020-01591-6.
14. Richards S, Aziz N, Bale S, et al. Standards and guidelines for the interpretation of sequence variants: a joint consensus recommendation of the American College of Medical Genetics and Genomics and the Association for Molecular Pathology. *Genet Med* 2015;17(5):405-24. DOI: 10.1038/gim.2015.30.
15. Govetto A, Lalane RA, 3rd, Sarraf D, Figueroa MS, Hubschman JP. Insights Into Epiretinal Membranes: Presence of Ectopic Inner Foveal Layers and a New Optical Coherence Tomography Staging Scheme. *Am J Ophthalmol* 2017;175:99-113. DOI: 10.1016/j.ajo.2016.12.006.
16. Gattoussi S, Buitendijk GHS, Peto T, et al. The European Eye Epidemiology spectral-domain optical coherence tomography classification of macular diseases for epidemiological studies. *Acta Ophthalmol* 2019;97(4):364-371. DOI: 10.1111/aos.13883.
17. Tan L, Long Y, Li Z, et al. Ocular abnormalities in a large patient cohort with retinitis pigmentosa in Western China. *BMC Ophthalmol* 2021;21(1):43. DOI: 10.1186/s12886-020-01797-z.
18. Hirakawa H, Iijima H, Gohdo T, Tsukahara S. Optical coherence tomography of cystoid macular edema associated with retinitis pigmentosa. *Am J Ophthalmol* 1999;128(2):185-91. DOI: 10.1016/s0002-9394(99)00100-2.
19. Hajali M, Fishman GA, Anderson RJ. The prevalence of cystoid macular oedema in retinitis pigmentosa patients determined by optical coherence tomography. *Br J Ophthalmol* 2008;92(8):1065-8. DOI: 10.1136/bjo.2008.138560.
20. Hajali M, Fishman GA. The prevalence of cystoid macular oedema on optical coherence tomography in retinitis pigmentosa patients without cystic changes on fundus examination. *Eye (Lond)* 2009;23(4):915-9. DOI: 10.1038/eye.2008.110.

21. Liew G, Strong S, Bradley P, et al. Prevalence of cystoid macular oedema, epiretinal membrane and cataract in retinitis pigmentosa. *Br J Ophthalmol* 2019;103(8):1163-1166. DOI: 10.1136/bjophthalmol-2018-311964.



Manuscript 12

### **3.6. Non-exudative macular neovascularization in Pseudoxanthoma Elasticum**

João Pedro Marques

João Bernardes

Sara Geadá

Mário Soares

Dora Teixeira

Cláudia Farinha

Isabel Pires

Maria Luz Cachulo

Rufino Silva

*Published in: Graefes Arch Clin Exp Ophthalmol. 2021 Apr;259(4):873-882.*

## **ABSTRACT**

### **Purpose**

To characterize morphological changes in the retina, and to report the frequency and natural history of non-exudative macular neovascularization (MNV) in a cohort of Pseudoxanthoma Elasticum (PXE).

### **Methods**

Single-center, retrospective study complemented by a cross-sectional examination. Consecutive patients with a definitive genetic and/or clinical diagnosis of PXE, visiting our Department between January 2019 and December 2019, and with a minimum follow-up of 6 months were recruited. Baseline data were retrieved from each patient file. Additionally, a cross-sectional examination comprising color fundus photography, spectral-domain optical coherence tomography (SD-OCT), OCT-Angiography (OCT-A), and fundus autofluorescence was performed. The presence of typical PXE-related findings, as well as related complications was multimodally evaluated. The prevalence and natural history of non-exudative MNV were assessed. All images were graded by two independent graders.

### **Results**

Forty-eight eyes from 24 patients (mean age  $59.11 \pm 18.14$ ) with a median follow-up of 53.00 months were included. Angioid streaks and *peau d'orange* were observed in 46/48 and 42/48 eyes, while MNV was present in 75.00% of the cohort. The prevalence of non-exudative MNV was 33.33% (6/18). In the 2 eyes that developed exudation, time to conversion was  $9.50 \pm 4.95$  months. No significant difference in visual acuity was found between eyes with non-exudative MNV and those with no signs of MNV.

### **Conclusions**

We have shown that non-exudative MNV is a frequent finding in PXE but the majority of eyes did not develop exudation during follow-up. Our results are a clear evidence of the utility of OCT-A in the management of PXE.

## INTRODUCTION

Pseudoxanthoma elasticum (PXE; OMIM #264800; ORPHA #758) is a rare, autosomal recessive multisystem disorder with an estimated prevalence of 1:25,000 to 1:100,000.<sup>1</sup> It is caused by sequence variants in the *ABCC6* gene, which encodes a transmembrane transporter protein (MRP6).<sup>2</sup> More than 300 disease-causing mutations in *ABCC6* have been identified, with different genetic profiles described in Asian and European populations.<sup>3-6</sup>

Progressive dystrophic calcification and structural change of elastic fibers of the extracellular matrix affecting selective connective tissues are the hallmark of PXE. The skin, eye, and cardiovascular system are primarily affected, despite considerable inter- and intrafamilial variability.<sup>6</sup>

Retinal involvement is known to increase with age,<sup>7</sup> with *peau d'orange* and angioid streaks being the most common findings.<sup>6</sup> Additionally, although to a lesser extent, optic nerve head (ONH) drusen, comets/comet tail lesions and pattern dystrophy-like changes have also been reported as part of the phenotype of PXE-related retinopathy. Angioid streaks are irregular, linear, crack-like dehiscences of a calcified and brittle Bruch membrane (BrM), typically emerging as dark reddish brown bands, with borders of variable width.<sup>3,8</sup> They usually radiate from a concentric peripapillary ring toward the equator of the eye. Calcification of BrM may also impede the exchange of nutrients, growth factors, and waste products between the retinal pigment epithelium (RPE) and choroid, ultimately leading to a functional and structural compromise of the RPE, the choriocapillaris and the retina.<sup>7</sup> Macular neovascularization (MNV)\* is a frequent complication of angioid streaks, affecting up to 86% of PXE patients over the course of the disease, and significantly impacting visual function as a result of subretinal hemorrhage, exudation, atrophy and/or fibrovascular scarring.<sup>9</sup> Exudative MNV is the only ocular complication of PXE that is eligible for treatment, with intravitreal injections of anti-vascular endothelial growth factor (VEGF) shown to reduce visual impairment in the long-term.<sup>9-11</sup> However, the onset of exudation does not necessarily coincide with the formation of MNV. We learned from optical coherence tomography angiography (OCT-A) studies in age-related macular degeneration (AMD) that asymptomatic, non-exudative MNV has a prevalence ranging from 6.25% to 27% in fellow eyes of neovascular AMD.<sup>12</sup> The 2-year cumulative exudation risk is 13.6 times greater in eyes diagnosed with non-exudative MNV compared with eyes without detectable lesions, thus highlighting the importance of frequent monitoring in this population.<sup>13</sup>

Even though the ocular phenotype of PXE-related retinopathy has been thoroughly described using multimodal imaging,<sup>3,7,8,14-16</sup> including OCT-A,<sup>17-19</sup> the prevalence and natural

---

\* The Consensus Nomenclature for Reporting Neovascular Age-Related Macular Degeneration (AMD) Data (2020) recently established that the term *macular neovascularization* should be used in AMD-related neovascularization. Even though neovascularization in PXE-associated retinopathy is pathophysiologically different from AMD, the authors chose to use the same term for PXE-related neovascularization.

history of non-exudative MNV in PXE have never been reported. The aim of this study was to multimodally characterize morphological changes in the retina, and to report the prevalence and natural history of non-exudative MNV in a Portuguese cohort of PXE-related retinopathy.

## **METHODS**

### **Study Design**

Single-center, retrospective cohort study complemented by a cross-sectional examination. The study was conducted at the Department of Ophthalmology of *Centro Hospitalar e Universitário de Coimbra*, and followed the tenets of the Declaration of Helsinki for biomedical research. Informed consent was obtained for every included subject and the study was approved by the local Ethics Committee.

### **Diagnostic Criteria**

Consecutive patients with a definitive genetic and/or clinical diagnosis of PXE, visiting our Department between January 2019 and December 2019, and with a minimum follow-up of 6 months were recruited. The diagnosis of PXE was established using the revised diagnostic criteria for PXE.<sup>20</sup> Only patients with definitive diagnosis (at least 2 major diagnostic criteria) were included. Patients with significant media opacities, unstable fixation, inadequate pupillary dilation or those with any possibly confounding vitreoretinal disease were excluded.

### **Study Protocol and Grading**

Baseline epidemiological data along with baseline imaging were retrieved from each individual patient file. Additionally, all patients underwent a cross-sectional examination comprising: (1) a comprehensive ophthalmologic examination including best-corrected visual acuity (BCVA), dilated slit-lamp anterior segment and fundus biomicroscopy; (2) seven standard 45°-field color fundus photographs (CFP) taken with a Nikon Digital SLR Camera D7000 (Nikon Corporation, Japan) mounted on a TRC-NW7SF Mark II Retinal Camera (Topcon Corporation, Japan); (3) spectral-domain optical coherence tomography (SD-OCT) (Spectralis, Heidelberg Engineering, Heidelberg, Germany); (4) OCT-Angiography (OCT-A) (Avanti RTVue-XR 100, Optovue Inc, Fremont, CA, USA); and (5) fundus autofluorescence (FAF) (HRAII, Heidelberg Engineering, Heidelberg, Germany). The presence/absence of typical PXE-related retinopathy findings was multimodally evaluated (angioid streaks, *peau d'orange*, ONH drusen, pattern dystrophy-like changes, comets and comet tail lesions), as well as the presence/absence of related complications: MNV, atrophy and fibrosis. Grading of angioid streaks was performed according to the 4 distinct FAF patterns described by Marchese et al<sup>21</sup>: pattern I – angioid streaks



appear as hypoautofluorescent irregular lines; pattern 2 – angioid streaks exhibit the parastreak phenomenon (mottled increase of autofluorescence along the margins of angioid streaks); pattern 3 – petaloid atrophy (hypoautofluorescence following the direction of angioid streaks around the optic disc); and pattern 4 – characterized by diffuse atrophy involving both the peripapillary and the macular area. Pattern dystrophy-like changes were graded according to Agarwal et al<sup>22</sup> and Finger et al<sup>15</sup> as: vitelliform, fundus flavimaculatus, fundus pulverulentus, and reticular. In eyes with MNV, the morphology (tangled: loose lace appearance with filamentous vessels and few branches; or interlacing: dense vascular network with multiple vessels and perilesional halo, as defined by Corbelli et al<sup>19</sup>), location (foveal involvement or foveal sparing), and activity (defined by the presence of intraretinal and/or subretinal fluid on SD-OCT) were evaluated. The boundaries used to identify MNV in this study extended from the outer retina to the choriocapillaris slab in OCT-A.

The term non-exudative MNV (also known as subclinical or quiescent MNV) was used for asymptomatic, treatment-naive MNV on OCT-A that has not shown evidence of exudation (defined by activity signs on SD-OCT) for a period >12 weeks. A retrospective analysis was performed to identify all cases of non-exudative MNV at the time of first OCT-A imaging. All available OCT-A exams from these eyes acquired over time were evaluated to determine the natural history, including the development of exudation (ie, conversion to exudative MNV). Time to symptomatic exudation was defined by the day subretinal and/or intraretinal fluid was documented on SD-OCT.

All images were graded by two independent experienced medical graders (JPM and JB). Disagreement was resolved by open adjudication.

### **Statistical Analysis**

Descriptive statistics were first calculated for all study variables. Continuous variables were recorded as mean and standard deviation (SD) values with minimum and maximum when appropriate, whereas categorical variables were recorded as frequency and percentage. Normality of continuous variables was evaluated by the Shapiro-Wilk test. Student's t-test and Mann-Whitney test were used to determine statistical significance between two independent samples. ANOVA and the Kruskal–Wallis test were used for associations between continuous variables with more than two independent predictors. Chi-square test and Fisher's exact test were used to calculate associations between binary variables. A p-value < 0.05 was considered statistically significant. Statistical analysis was performed with SPSS software version 23 (IBM Corp; Armonk, NY).

## RESULTS

### Study Population

Forty-eight eyes of 24 consecutive patients with PXE, with a mean age of  $59.11 \pm 18.14$  years old (range 17–95 years) were included. The cohort included 12 male and 12 female patients with a median follow-up of 53.00 months (range 6–263 months).

### Multimodal Imaging Findings

A cross-sectional visit comprising multimodal retinal imaging was used to describe the ocular phenotype of PXE-related retinopathy (Table 1 and Figure 1). Angioid streaks and *peau d'orange* were observed in 46/48 (95.83%) and 42/48 (87.50%) eyes, respectively. The different angioid streaks patterns of autofluorescence (Figure 2E-H) were evaluated with FAF (Table 1). A statistically significant association ( $p < 0.001$ ) was observed between these patterns and the patients' age, with younger patients showing mostly patterns 1 and 2 and older patients showing patterns 3 and 4.

Comets/comet tail lesions were identified in 8/48 eyes (16.67%), mainly located in the (mid)periphery (Fig 1B). ONH drusen were visible in 3 eyes (6.25%) of 2 patients. Pattern-dystrophy-like changes (Fig 2A-D) were seen in 20/48 eyes (41.67%). These were most frequently observed in eyes with angioid streaks FAF patterns 1 and 2 ( $p = 0.021$ ).

On OCT-A and SD-OCT, MNV lesions were observed in 36/48 eyes (75.00%). Sixteen eyes were undergoing treatment with anti-VEGF agents, while the same number ( $n = 16$ ) showed disciform scarring. Macular atrophy was present in 21 eyes.

Eyes without MNV lesions ( $n = 12$ ) tended to exhibit initial FAF angioid streaks patterns (1 and 2). In fact, only 1 eye without MNV lesion had a FAF pattern higher than 2 ( $p = 0.018$ ).

**Table 1.** Relative frequency of the features of PXE-related retinal dystrophy in our cohort at the time of the cross-sectional evaluation

Ocular Features	n (%)
<i>Peau d'orange</i>	42 (87.50%)
Angioid streaks	46 (95.83%)
FAF Patterns of Angioid Streaks	
Pattern 1: Hypoautofluorescent lines	12 (25.00%)
Pattern 2: Parastreak phenomenon	16 (33.33%)
Pattern 3: Petaloid atrophy	8 (16.67%)
Pattern 4: Diffuse atrophy	12 (25.00%)

Comets / Comet tail lesion	8 (16.67%)
Pattern dystrophy-like changes	20 (41.67%)
Vitelliform	1 (5.00%)
Fundus pulverulentus	14 (70.00%)
Fundus flavimaculatus	2 (10.00%)
Reticular	3 (15.00%)
Optic nerve head drusen	3 (6.25%)
Focal choroidal excavation (n; %)	5 (10.42%)
Macular neovascularization (MNV)	36 (75.00%)
Exudative MNV	16 (44.44%)
Non-exudative MNV	4 (11.11%)
Disciform	16 (44.44%)
Foveal involvement	27 (75%)
Topographically associated with angiod streaks	22 (61.11%)

---

FAF – fundus autofluorescence

### ***Non-exudative Macular Neovascularization***

On the last available follow-up, among the 36 eyes with MNV, non-exudative MNV was found in 4 (Table 1). To calculate the prevalence of MNV in our cohort we retrospectively reviewed all baseline OCT-A exams and excluded those eyes with advanced disease (active MNV, fibrosis and/or macular atrophy) at the time of first OCT-A imaging (30/48; 62.50%). In the remaining 18 eyes, non-exudative MNV was identified in 6, for a frequency of 33.33%. The demographic characteristics of these cases are illustrated in Table 2. All eyes had follow-up visits, averaging  $31.17 \pm 16.82$  months. Four eyes of 3 patients with non-exudative MNV at baseline did not develop exudation during the entire follow-up (Figs 3, 4 and 5). In those that developed exudation (n=2), an average time to conversion of  $9.50 \pm 4.95$  months was found. The incidence of exudation in eyes with non-exudative MNV was 33.3% (2/6), whereas in eyes without non-exudative MNV (12/18; 66.6%) no exudation was observed during the entire follow-up ( $23.75 \pm 5.82$  months).

All cases of macular non-exudative MNV were classified as type I MNV, with an interlacing network observed on OCTA. A double-layer sign was found in 4 eyes (66.67%). Interestingly, foveal involvement was only observed in case I (which developed exudation 13 months after). BCVA remained unchanged both in eyes with non-exudative MNV and in those with no signs of MNV. Furthermore, the difference in BCVA between the two groups was not significant, neither at diagnosis nor at the last visit (table 3).

**Table 2.** Demographic characteristics of the eyes with non-exudative MNV

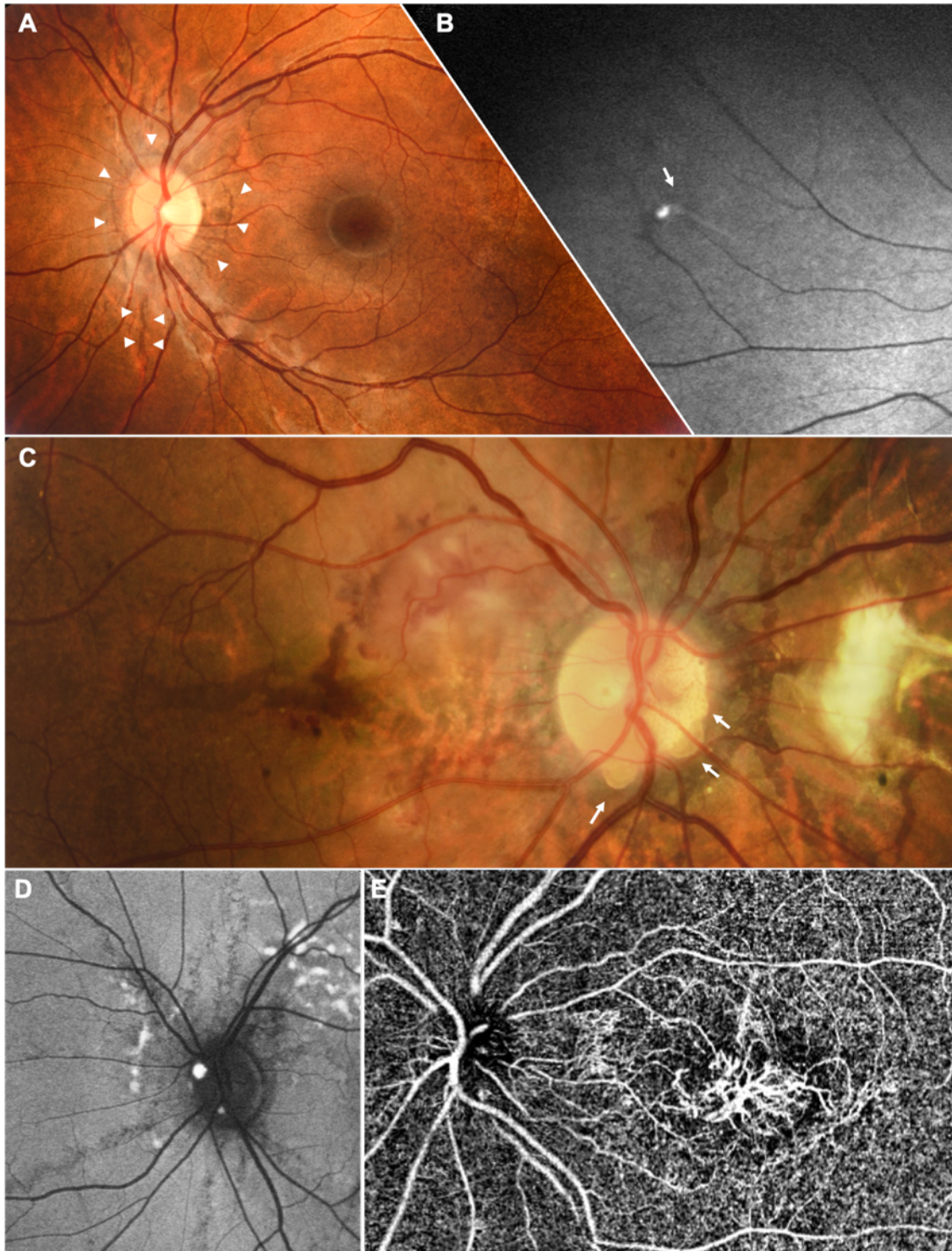
Case	Age	Eye	Sex	Follow-up (months)	Conversion	Time to conversion (months)	Pattern Dystrophy
1	74	R	M	33	Yes	13	reticular
2	52	L	F	6	No	N/A	fundus pulverulentus
3	56	L	M	24	Yes	6	fundus pulverulentus
4	60	R	F	33	No	N/A	fundus flavimaculatus
5	60	L	F	33	No	N/A	fundus flavimaculatus
6	41	R	F	58	No	N/A	no

N/A – not applicable

**Table 3.** BCVA differences between eyes with non-exudative MNV and eyes without MNV

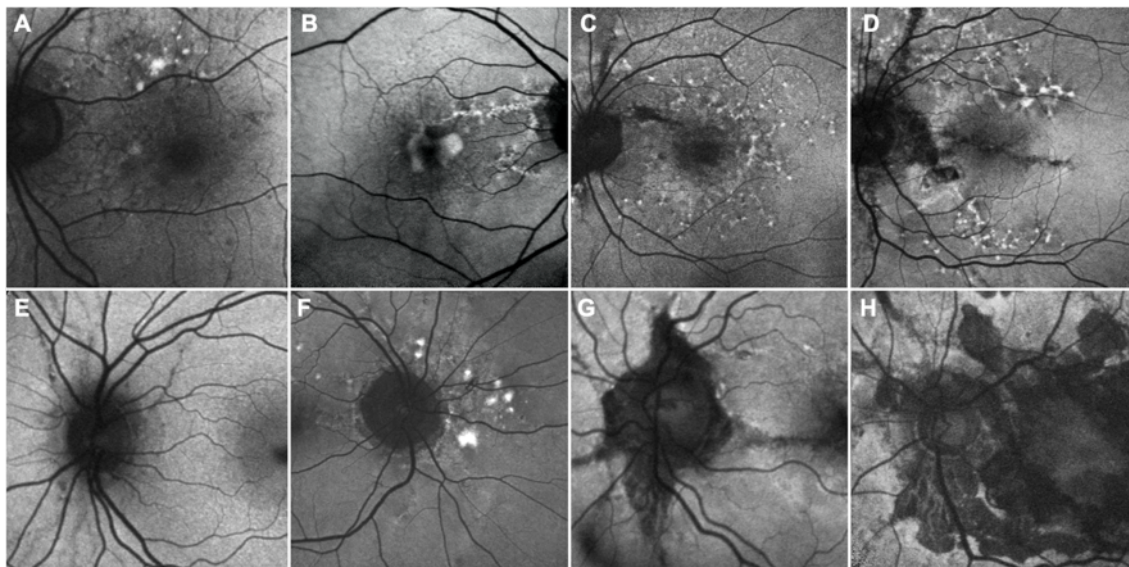
<b>BCVA at baseline mean ± SD (ETDRS letters)</b>	Without MNV	81.91 ± 4.91	p=0.197
	Non-exudative MNV	70 ± 19.49	
<b>BCVA at last visit mean ± SD (ETDRS letters)</b>	Without MNV	81.00 ± 7.41	p=0.452
	Non-exudative MNV	73 ± 23.61	

BCVA – best-corrected visual acuity; SD – standard deviation; MNV – macular neovascularization

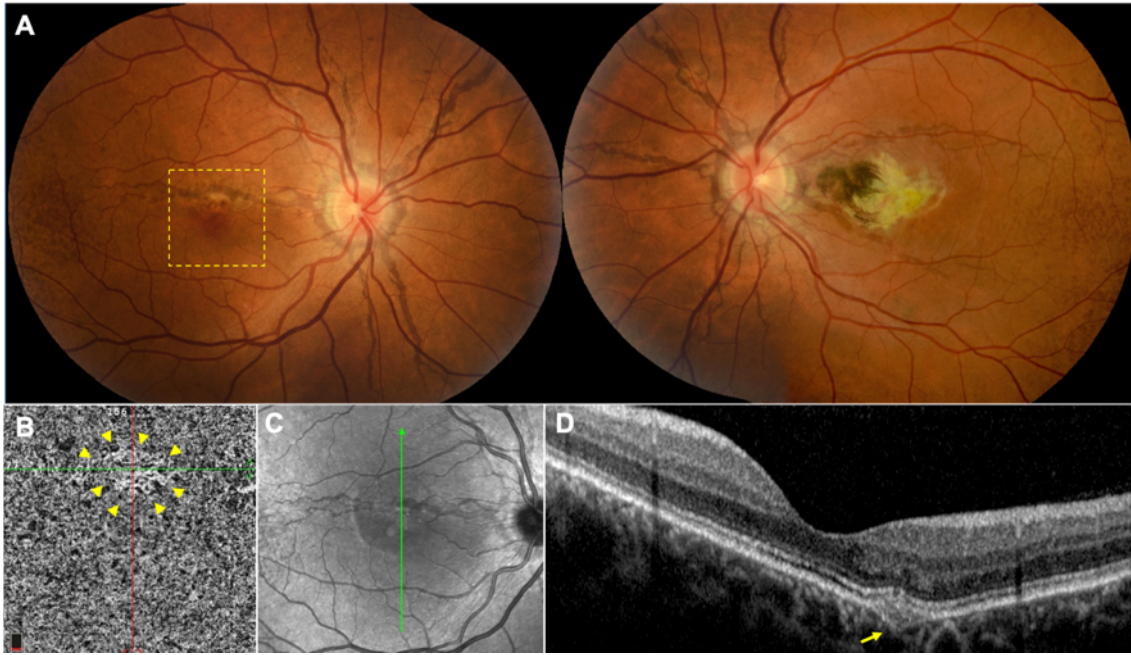


**Figure 4** Several examples of the ocular features of PXE-related retinopathy in our cohort. Angioid streaks are irregular, linear, crack-like dehiscences of a calcified and brittle Bruch membrane, typically emerging as dark reddish brown bands, with borders of variable width. They usually radiate from a concentric peripapillary ring toward the equator of the eye (white arrowheads in Figure A). Peau d'orange is characterized by small dark spots, within an area of a slightly whitish or opaque fundus reflex (Figures A and C). This pattern may be observed at the posterior pole (temporal macula) very early in the disease and more peripheral in later disease

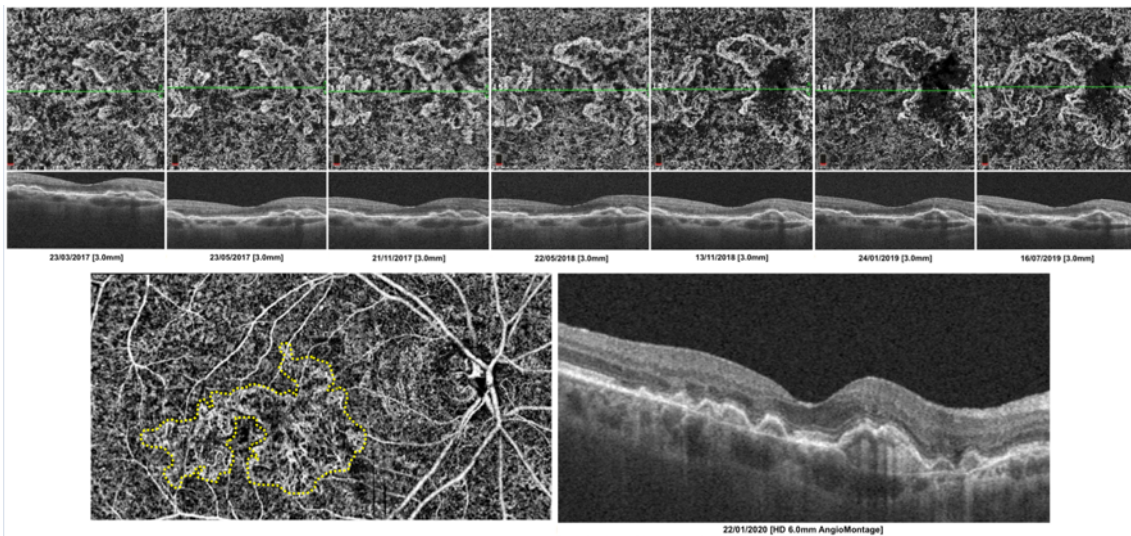
stages. Comet tail lesions appear as yellowish spots with different dimensions, sometimes presenting an opaque tail pointing to the optic nerve head. On FAF imaging, they often show considerable hyperautofluorescence (white arrow in Figure B). Optic nerve head drusen have the shape of crystalline structures embedded within the ONH (white arrows in Figure C), while on FAF, hyperautofluorescent round structures are usually identified (Figure D). Macular neovascularization (MNV) is a common finding in PXE. An active lesion complicated by subretinal hemorrhage is seen in Figure C, while a fibrotic scar is observed nasally in the same eye. On Optical Coherence Tomography Angiography (OCT-A), the neovascular complex is usually readily identified (Figure E). Pattern dystrophy-like changes often accompany PXE. In Figure D, fundus pulverulentus-like pattern dystrophy is observed on FAF.



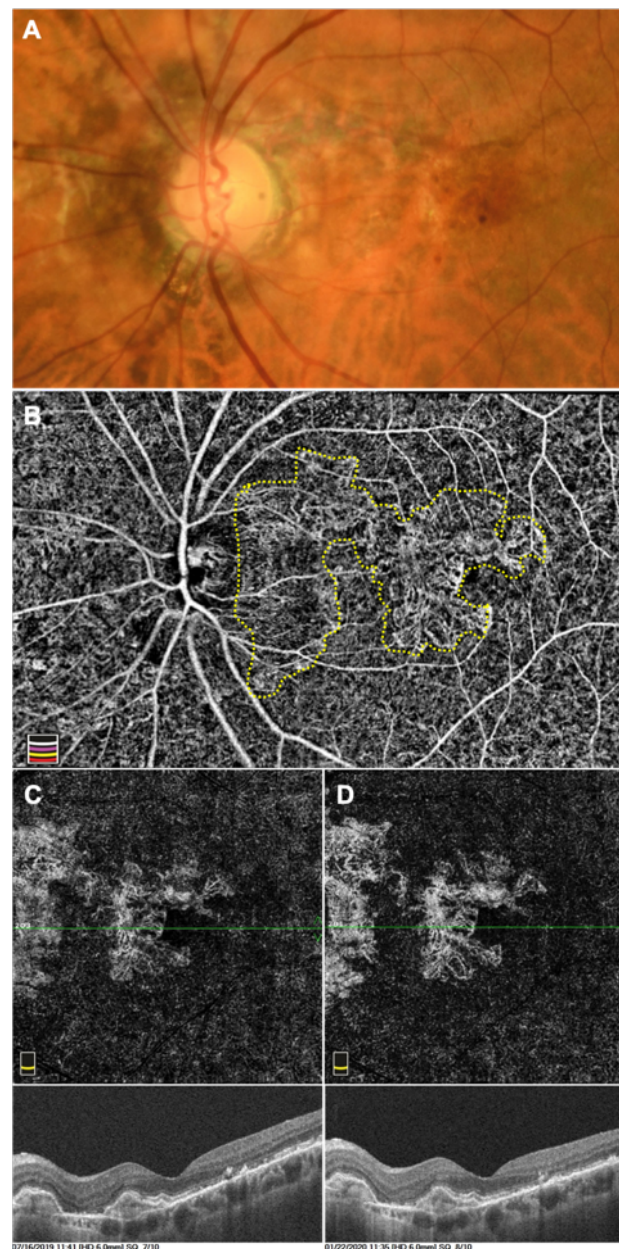
**Figure 5** **A-D** represent examples of the pattern dystrophy-like changes observed on Fundus Autofluorescence (FAF) in patients with PXE: **(A)** Fundus pulverulentus, **(B)** Vitelliform, **(C)** Fundus flavimaculatus and **(D)** Reticular. **E-H** represent the 4 patterns of angioid streaks observed on FAF: **(E) Pattern 1** – angioid streaks appear as hypoautofluorescent irregular lines; **(F) Pattern 2** – angioid streaks exhibit the parastreak phenomenon (mottled increase of autofluorescence along the margins of angioid streaks); **(G) Pattern 3** – petaloid atrophy (hypoautofluorescence following the direction of angioid streaks around the optic disc); and **(H) Pattern 4** – characterized by diffuse atrophy involving both the peripapillary and the macular area.



**Figure 6** Forty-one year-old female patient with PXE. **(A)** Color fundus photography showing angioid streaks and peau d'orange RLE. On the left eye, disciform scarring is seen. **(B)** 3x3 mm macular OCT-A scan of the choriocapillaris slab corresponding to the region of the yellow dotted square on **(A)**. An interlacing extrafoveal neovascular membrane is seen (yellow arrowheads). **(C)** Near infra-red imaging showing the topographical association of the neovascular lesion with an angioid streak. **(D)** A vertical OCT scan over the green arrow in **(C)** shows a focal choroidal excavation (yellow arrow) and double layer sign in topographical association with the angioid streak and the small extrafoveal neovascular membrane. Despite 58 months of follow-up, exudation never occurred and visual acuity remains 20/20 OD.



**Figure 7** Long-term follow-up of macular neovascularization in the RE of a 60 years old female patient with PXE. The patient has been followed for almost 3 years, and monitored with frequent OCT-A examinations. What started as 2 independent foci of neovascularization has evolved to a single neovascular complex (yellow dotted line). Despite an evident increase in size over time, the lesion remains non-exudative and the patient is asymptomatic with 20/25 vision.



**Figure 8** Multimodal imaging of non-exudative macular neovascularization in the LE of the same patient imaged in Figure 4. **(A)** Color fundus photography shows angioid streaks and pigmentary changes in the macula. **(B)** On OCTA, a large, foveal sparing neovascular complex is seen (yellow dotted line). **(C)** and **(D)** show the 2 last available 6x6 macular OCTA scans in the outer retina



slab and corresponding SD-OCT horizontal scans. The neovascular complex is relatively stable, with no signs of activity. The patient has a total follow up of 33 months.

## DISCUSSION

This study presents a detailed and thorough multimodal characterization of the ocular phenotype of PXE in a Portuguese cohort and is the first to describe the prevalence and natural history of non-exudative MNV in PXE-related retinopathy. The ocular phenotype of PXE-related retinopathy has been extensively described using multimodal imaging.<sup>3,7,8,14-19</sup> As reported in previous studies, angioid streaks were the most common funduscopic finding observed in our cohort (46/48; 95.83%). All patients except the youngest (a 16-year-old boy with confirmed biallelic *ABCC6* mutations and typical skin changes) were found to have angioid streaks in both eyes. The four angioid streaks patterns on FAF showed a statistically significant association with the patients' age. This is consistent with the findings reported by Marchese et al,<sup>21</sup> thus favoring the author's hypothesis that FAF patterns may represent progressive stages of degenerative changes associated with angioid streaks. It is possible that, over time, RPE changes expanding beyond the angioid streaks margins are responsible for the broadening of the hypoautofluorescence (pattern 3 – petaloid), culminating in generalized RPE abnormalities, as observed in pattern 4.

Pattern dystrophy-like changes are frequently observed in patients with PXE-related retinopathy. Agarwal et al<sup>22</sup> reported a prevalence of 60% in a study including 44 eyes imaged with CFP. The prevalence reported by Marchese et al<sup>21</sup> and Finger et al<sup>15</sup> was considerably lower (3/40; 7.50% and 8/92; 8.70%, respectively) in studies where FAF was used to complement CFP. In our cohort, pattern dystrophy-like changes were identified in 41.67% cases using a combination of CFP and FAF. The presence of extensive scarring/atrophy in association with exudative/previously exudative MNVs in a large proportion of eyes included in this study may have obscured pattern dystrophy-like changes that were present before.

Although the pathophysiology of PXE remains to be fully elucidated, it is clear that the various disease manifestations are a consequence of slow but progressive calcification of connective tissue rich in elastic fibers.<sup>7</sup> Angioid streaks result from breaks/defects in a calcified BrM. These brittle and fragile areas generate a direct communication to the choroid circulation, allowing neovascular complexes to sprout into the sub-RPE space. This inherent predisposition to neovascularization explains the high reported prevalence (up to 86%) of MNV in PXE.<sup>9</sup> The posterior pole is the most commonly affected area as a consequence of the higher frequency of angioid streaks.<sup>7</sup> In fact, MNV could be topographically associated with angioid streaks in 61.11% of our sample. This is probably an underestimation since in cases with advanced disease the topographical association may no longer be possible.

The widespread use of OCT-A led to a recent increase in the identification of asymptomatic, non-exudative MNV in several retinal conditions, including PXE-related retinopathy. Andreanos et al<sup>23</sup> first reported a case of non-exudative type I MNV in a patient with PXE. The authors monitored the patient closely with OCT-A examinations performed every 2 months and found no evidence of exudation, despite a small increase in the CNV area. Visual acuity remained stable throughout the 8-month follow-up. Since patients with PXE are usually asymptomatic until vision drops due to the advent of neovascularization, most of them only seek eye care after exudation occurs. This is why a large proportion of our cohort (62.50%; 30/48) had exudative MNV or late disease at baseline. Excluding these eyes, the relative frequency of non-exudative MNV was 33.33% (6/18). Even though direct comparisons are not possible, this number appears to be higher than those reported for AMD, where non-exudative MNV has a prevalence ranging from 6.25% to 27% in fellow eyes of neovascular AMD.<sup>12</sup>

All cases of non-exudative MNV in our cohort had an interlacing pattern on OCT-A. This pattern is characterized by a dense vascular network with multiple and tortuous vessels, and a perilesional halo and is usually described in association with activity signs.<sup>19</sup> Nevertheless, no consensus exists on the aspect (and value) of the reported OCT-A morphological patterns.<sup>18</sup> Conversion to exudative MNV was found in 2 eyes (33.33%) over a mean follow-up of  $31.17 \pm 16.82$  months. In those that developed signs of activity, the average time to exudation was  $9.50 \pm 4.95$  months. Natural history studies in AMD have shown that ~25% of lesions become exudative over 6 to 20 months.<sup>12</sup> Thus, the identification of non-exudative MNV should result in close monitoring so that anti-VEGF treatment is started as soon as activity signs arise. On the other hand, there is also evidence suggesting that the presence of a stable non-exudative neovascular complex is not always detrimental and may even prevent or reduce the progression of RPE atrophy.<sup>12</sup> These lesions may actually provide nutritional support to the overlying RPE and photoreceptors, thus preserving foveal function and persisting for many years without affecting vision.<sup>24</sup> This hypothesis is supported by a clinicopathological study<sup>24</sup> conducted in a 90 year-old patient with long-standing non-exudative MNV before her death. The authors found distinguishing features like numerous connecting vessels, high density of neovessels, a continuous RPE, and slow growth of the neovascular complex over time. It is now accepted that as long as exudation does not occur, AMD-related non-exudative MNV is not responsible for a deterioration in visual function and anti-VEGF treatment is not indicated.<sup>12</sup> We strongly believe that this rationale also applies to PXE-related non-exudative MNV as illustrated by several cases in this cohort who present long-term follow-ups and no signs of exudation.

This study has several limitations, mostly associated to its retrospective nature. These include heterogeneity of visit intervals and imaging (performed at baseline and during follow-up). To compensate for this, we performed a cross-sectional examination where all patients were

subjected to multimodal imaging following a strict acquisition protocol. Still, since we did not include ultrawidefield imaging, the prevalence of some PXE-related features, especially those more commonly found in (mid)periphery may be underestimated. Another limitation is the large number of eyes with advanced disease at baseline. This limitation is mainly associated to the fact that most asymptomatic patients with PXE do not seek eye care. Finally, frequencies of specific features always depend on the cohort (selected diagnostic criteria, age distribution, etc) and large patient cohorts are required to achieve meaningful conclusions and draw evidence-based recommendations.

Despite the above-mentioned limitations, our study has several strengths. First, a standardized protocol involving rapid and noninvasive multimodal retinal imaging and 2 independent graders allowed us to characterize the ocular phenotype of PXE in a Portuguese cohort. Second, we were able to describe the prevalence and natural history of non-exudative MNV in PXE-related retinopathy for the first time, thus contributing to a better understanding of this clinical entity in PXE.

### **Conclusion**

The frequency and natural history of non-exudative MNV in a cohort of PXE-related retinopathy are herein reported for the first time. We have shown that non-exudative MNV is a common finding in PXE and despite the long follow-up, the majority of eyes did not develop exudation. Our findings are a clear evidence of the utility of OCT-A in the management of this disease. Given its non-invasive nature, OCT-A should be considered part of the clinical evaluation of all patients with PXE, including those asymptomatic. Like in AMD, we believe that non-exudative MNV in PXE-related retinopathy should be monitored frequently but treatment with anti-VEGF should only be started once exudation develops. Finally, the presumed supportive role of non-exudative MNV in the setting of a severely dysfunctional BrM should be further studied. PXE may actually be an ideal model disease to better understand this clinical entity. Longitudinal OCT-A studies with large patient cohorts are warranted to better characterize non-exudative MNV in PXE.

### **REFERENCES**

1. Chassaing N, Martin L, Calvas P, Le Bert M, Hovnanian A. Pseudoxanthoma elasticum: a clinical, pathophysiological and genetic update including 11 novel ABCC6 mutations. *J Med Genet* 2005;42(12):881-92. DOI: 10.1136/jmg.2004.030171.

2. Nguyen XT, Talib M, van Cauwenbergh C, et al. CLINICAL CHARACTERISTICS AND NATURAL HISTORY OF RHO-ASSOCIATED RETINITIS PIGMENTOSA: A Long-Term Follow-Up Study. *Retina* 2020. DOI: 10.1097/IAE.0000000000002808.
3. Chatziralli I, Saitakis G, Dimitriou E, et al. ANGIOID STREAKS: A Comprehensive Review From Pathophysiology to Treatment. *Retina* 2019;39(1):1-11. DOI: 10.1097/IAE.0000000000002327.
4. Katagiri S, Negishi Y, Mizobuchi K, Urashima M, Nakano T, Hayashi T. ABCC6 Gene Analysis in 20 Japanese Patients with Angioid Streaks Revealing Four Frequent and Two Novel Variants and Pseudodominant Inheritance. *J Ophthalmol* 2017;2017:1079687. DOI: 10.1155/2017/1079687.
5. Ran Y, Zheng A, Thibodeau PH. Structural analysis reveals pathomechanisms associated with pseudoxanthoma elasticum-causing mutations in the ABCC6 transporter. *J Biol Chem* 2018;293(41):15855-15866. DOI: 10.1074/jbc.RA118.004806.
6. Legrand A, Cornez L, Samkari W, et al. Mutation spectrum in the ABCC6 gene and genotype-phenotype correlations in a French cohort with pseudoxanthoma elasticum. *Genet Med* 2017;19(8):909-917. DOI: 10.1038/gim.2016.213.
7. Gliem M, Zaeytijd JD, Finger RP, Holz FG, Leroy BP, Charbel Issa P. An update on the ocular phenotype in patients with pseudoxanthoma elasticum. *Front Genet* 2013;4:14. DOI: 10.3389/fgene.2013.00014.
8. Gliem M, Muller PL, Birtel J, Hendig D, Holz FG, Charbel Issa P. Frequency, Phenotypic Characteristics and Progression of Atrophy Associated With a Diseased Bruch's Membrane in Pseudoxanthoma Elasticum. *Invest Ophthalmol Vis Sci* 2016;57(7):3323-30. DOI: 10.1167/iovs.16-19388.
9. Risseeuw S, Ossewaarde-van Norel J, Klaver CCW, Colijn JM, Imhof SM, van Leeuwen R. Visual Acuity in Pseudoxanthoma Elasticum. *Retina* 2019;39(8):1580-1587. DOI: 10.1097/IAE.0000000000002173.
10. Gliem M, Finger RP, Fimmers R, Brinkmann CK, Holz FG, Charbel Issa P. Treatment of choroidal neovascularization due to angioid streaks: a comprehensive review. *Retina* 2013;33(7):1300-14. DOI: 10.1097/IAE.0b013e3182914d2b.
11. Tilleul J, Mimoun G, Querques G, et al. INTRAVITREAL RANIBIZUMAB FOR CHOROIDAL NEOVASCULARIZATION IN ANGIOID STREAKS: Four-Year Follow-up. *Retina* 2016;36(3):483-91. DOI: 10.1097/IAE.0000000000000745.
12. Laiginhas R, Yang J, Rosenfeld PJ, Falcão M. Non-Exudative Macular Neovascularization - A systematic review of prevalence, natural history, and recent insights from OCT angiography. *Ophthalmology Retina*. DOI: 10.1016/j.oret.2020.02.016.

13. Yang J, Zhang Q, Motulsky EH, et al. Two-Year Risk of Exudation in Eyes with Nonexudative Age-Related Macular Degeneration and Subclinical Neovascularization Detected with Swept Source Optical Coherence Tomography Angiography. *Am J Ophthalmol* 2019;208:1-11. DOI: 10.1016/j.ajo.2019.06.017.
14. De Zaeytijd J, Vanakker OM, Coucke PJ, De Paepe A, De Laey JJ, Leroy BP. Added value of infrared, red-free and autofluorescence fundus imaging in pseudoxanthoma elasticum. *Br J Ophthalmol* 2010;94(4):479-86. DOI: 10.1136/bjo.2009.162644.
15. Finger RP, Charbel Issa P, Ladewig M, Gotting C, Holz FG, Scholl HP. Fundus autofluorescence in Pseudoxanthoma elasticum. *Retina* 2009;29(10):1496-505. DOI: 10.1097/IAE.0b013e3181aade47.
16. Gliem M, Birtel J, Muller PL, et al. Acute Retinopathy in Pseudoxanthoma Elasticum. *JAMA Ophthalmol* 2019. DOI: 10.1001/jamaophthalmol.2019.2910.
17. Birtel J, Lindner M, Mishra DK, et al. Retinal imaging including optical coherence tomography angiography for detecting active choroidal neovascularization in pseudoxanthoma elasticum. *Clin Exp Ophthalmol* 2019;47(2):240-249. DOI: 10.1111/ceo.13385.
18. Chapron T, Mimoun G, Miere A, et al. Optical coherence tomography angiography features of choroidal neovascularization secondary to angioid streaks. *Eye (Lond)* 2019;33(3):385-391. DOI: 10.1038/s41433-018-0213-1.
19. Corbelli E, Carnevali A, Marchese A, et al. Optical Coherence Tomography Angiography Features of Angioid Streaks. *Retina* 2018;38(11):2128-2136. DOI: 10.1097/IAE.0000000000001859.
20. Plomp AS, Toonstra J, Bergen AA, van Dijk MR, de Jong PT. Proposal for updating the pseudoxanthoma elasticum classification system and a review of the clinical findings. *Am J Med Genet A* 2010;152A(4):1049-58. DOI: 10.1002/ajmg.a.33329.
21. Marchese A, Rabiolo A, Corbelli E, et al. Ultra-Widefield Imaging in Patients with Angioid Streaks Secondary to Pseudoxanthoma Elasticum. *Ophthalmol Retina* 2017;1(2):137-144. DOI: 10.1016/j.oret.2016.10.005.
22. Agarwal A, Patel P, Adkins T, Gass JD. Spectrum of pattern dystrophy in pseudoxanthoma elasticum. *Arch Ophthalmol* 2005;123(7):923-8. DOI: 10.1001/archophth.123.7.923.
23. Andreanos KD, Rotsos T, Koutsandrea C, Kymionis GD, Georgalas I, Ladas ID. Detection of nonexudative choroidal neovascularization secondary to angioid streaks using optical coherence tomography angiography. *Eur J Ophthalmol* 2017;27(5):e140-e143. DOI: 10.5301/ejo.5000995.

24. Chen L, Messinger JD, Sloan KR, et al. Nonexudative Macular Neovascularization Supporting Outer Retina in Age-Related Macular Degeneration: A Clinicopathologic Correlation. *Ophthalmology* 2020. DOI: 10.1016/j.optha.2020.01.040.

## **CHAPTER 4: PATIENT-REPORTED OUTCOMES**





Manuscript 13

**4.1. Portuguese translation and linguistic validation of the Michigan Retinal Degeneration Questionnaire and the Michigan Vision-Related Anxiety Questionnaire in a cohort with Inherited Retinal Degenerations**

João Pedro Marques

Luís Bernardes

Carolina Oliveira

Gabriela Fonseca

João Quadrado Gil

Luciana Sotero

Ana Paula Relvas

Joaquim Murta

Rufino Silva

Gabrielle Davis Lacy

Maria Fernanda Abalem

K. Thiran Jayasundera

*Published in: Ophthalmic Genet. 2022 Feb;43(1):137-139.*

## MANUSCRIPT

Inherited retinal degenerations (IRDs) are among the most important causes of severe visual impairment and blindness in children and young adults in developed countries<sup>1,2</sup>, thus posing a significant psychosocial and economic burden<sup>3</sup>. Recent therapeutic advances in the field raise the need for standardized patient reported outcome (PRO) measurement<sup>4</sup>. The Michigan Retinal Degeneration Questionnaire (MRDQ)<sup>5</sup> and the Michigan Vision-Related Anxiety Questionnaire (MVAQ)<sup>6</sup> are two psychometrically validated PRO questionnaires specifically designed to measure visual function and anxiety in IRDs. MRDQ and MVAQ can be used to monitor vision-related quality of life changes over time, and therefore are adequate tools to monitor disease progression and treatment impact, both in clinical practice and in clinical trial settings. However, both PRO measures are only available in English, thus limiting the scope of their applicability. Its translation to Portuguese, the world's 5<sup>th</sup> language with more native speakers, would be a step forward to achieving valid global PRO research.

For the purpose of making an official Portuguese translation, written permission from the original authors of MRDQ and MVAQ was obtained, and an end-user license agreement was signed by the involved parts – University of Michigan and Centro Hospitalar e Universitário de Coimbra (CHUC) – to use the original versions of the copyright protected questionnaires. The translation process followed the recommendations of the *International Society for Pharmacoeconomics and Outcomes Research (ISPOR)* task force for linguistic and cultural validation of PROs<sup>7</sup> and *PRO Consortium* consensus of updated best practices<sup>8</sup>. First, the original English versions of MRDQ and MVAQ were translated to Portuguese (forward translation) by two independent qualified translators, native Portuguese speakers and fluent in English, and reconciled into one translation by a third independent qualified translator. Back-translation of the reconciled forward translation was performed by a fourth qualified translator, blind to the source questionnaire. This was followed by assessment of semantic equivalence of the back-translation, aiming to identify issues in the reconciled translation, agree on revisions and implement changes. Conceptual and operational equivalence were prioritized rather than literal word for word translation of the items, taking into account the cultural differences and multiple meanings of some of the words used. The questionnaires were then administered to willing participants recruited from the IRD-PT registry<sup>9</sup> and managed at the Retinal Dystrophies Clinic of CHUC, Coimbra, Portugal. Informed consent was obtained upon enrolment. In pediatric patients, a caregiver's consent was also obtained. The interviews were conducted over the phone between March 2021 and June 2021 by a trained Clinical Psychologist. The time each patient took to respond to every item was measured; patients were also asked to comment on

the extent to which the questionnaire and individual items were clear, objective, and adequate to their visual function and daily life.

Genetically confirmed IRD patients from both genders (age range 16-70 years old) and across different levels of education, responded to the MRDQ (n=15) and MVAQ (n=11). Seven patients responded to both questionnaires. Sample characteristics are described in Table 1. Questionnaire and individual item response times for both PRO tools are summarized in Table 2. For MRDQ, 14/15 patients found most items to be precise and easy to understand. For MVAQ, four patients reported difficulties in understanding some questions, thus highlighting the need for improved semantic and conceptual equivalence of the translation. After concluding the cognitive interviews, the research team reviewed the results and compiled all queries from the respondents (post-cognitive interview debriefing). Content validity was investigated by evaluating the comprehensibility, comprehensiveness and relevance of the items that compose both questionnaires. Based on patient feedback, cognitive debriefing and result analysis, minor revisions to the reconciled forward translation were implemented and a few final corrections were performed to reach a final Portuguese version of both PRO measures.

**Table 1.** Characteristics of the respondents to MRDQ and MVAQ

	MRDQ	MVAQ
<b>N</b>	15	11
<b>Age [mean (Q1; Q3)]</b>	37 (26; 45)	28 (19.5; 35)
<b>Gender</b>		
Male	5	4
Female	10	7
<b>Educational stage</b>		
Middle-school or less	5	4
Secondary/High school	5	1
Tertiary education	5	6
<b>Diagnosis</b>		
Non syndromic RP	6	1
ECORD	7	8
PAX6-associated foveal hypoplasia	1	0
Fundus Albipunctatus	1	0
Stargardt disease	0	1
Cone-rod dystrophy	0	1
<b>Gene</b>		
<i>RPE65</i>	7	7
<i>RPGR</i>	3	0
<i>RDH5</i>	1	0
<i>GRK1</i>	1	0
<i>PRPF31</i>	1	0

<i>ABCA4</i>	0	1
<i>IMPG2</i>	1	0
<i>LRAT</i>	0	1
<i>PAX6</i>	1	0
<i>EYS</i>	0	1
<i>RPGRIP1</i>	0	1

MRDQ – Michigan Retinal Degeneration Questionnaire; MVAQ – Michigan Vision-related Anxiety Questionnaire; Q1 – quartile 1 (25%); Q3 – quartile 3 (75%); RP – retinitis pigmentosa; ECORD – early childhood onset retinal degeneration

**Table 2.** Total time and individual item response times for MRDQ and MVAQ

	MRDQ	MVAQ
<b>Total time [seconds; median (Q1; Q3)]</b>	30 (23; 35)	6(5; 8)
<b>Median time per group of questions [seconds; median (Q1; Q3)]</b>		
Reading	70 (60; 131,5)	5 (3,5; 29,5)
Color and contrast	45 (24,5; 100)	5 (4; 6)
Dark adaptation, mobility and peripheral vision	130 (71; 145)	6 (6; 10,5)
Light sensitivity	28 (20; 37)	5 (4; 7,5)

MRDQ – Michigan Retinal Degeneration Questionnaire; MVAQ – Michigan Vision-related Anxiety Questionnaire; Q1 – quartile 1 (25%); Q3 – quartile 3 (75%)

Despite the recent growth in clinical trials evaluating new treatments for IRDs, it remains difficult to detect therapeutic improvement using standard objective visual function testing<sup>4</sup>. PRO instruments are valuable indicators of a patient’s quality of life, functioning or disability from his/her own perspective, and for this reason are recognized as valid clinical trial outcome measures<sup>10</sup>. Translation, linguistic validation and cultural adaptation are crucial steps to obtain rigorous and valid global PRO research. Adherence to recommended guidelines is essential for ensuring the quality of PRO end-point data and give regulatory agencies confidence in data from the translated versions<sup>8</sup>. We describe step by step the process behind the Portuguese translation and linguistic validation of two new, highly comprehensive and detailed visual function and vision-related anxiety questionnaires – MRDQ and MVAQ, respectively. Very few participants encountered item-specific comprehensibility problems or indicated general comprehensibility issues regarding the response category and the questionnaire’s instructions. Most of these were minor issues regarding translation that could be solved with small changes to the wording or specifying the phrasing and clarifying the item context or conditions. Comprehensibility is probably influenced by the level of education of the respondents, and we believe that the variation in level of education was sufficient among our respondents. As a result, the adaptations

we made should contribute to content validity. Apart from that, both questionnaires proved clear, easy to understand, reasonably objective and simultaneously very comprehensive, covering all aspects of visual function in a manner which respects and adequately mirrors the characteristics of the original documents. Moreover, the socioeconomic, clinical and genetic heterogeneity of the respondents ensures that these translations maintain their properties across different IRDs.

The Portuguese versions of MRDQ and MVAQ are semantically, conceptually and operationally equivalent to the original English versions, and may be used in clinical practice or clinical trials involving Portuguese-speaking IRD patients. A quantitative validation study to evaluate the psychometric properties and responsiveness of the Portuguese translations of MRDQ and MVAQ in a large sample of Portuguese-speaking IRD patients from Portugal and Brazil is currently ongoing.

## REFERENCES

1. Liew G, Michaelides M, Bunce C. A comparison of the causes of blindness certifications in England and Wales in working age adults (16-64 years), 1999-2000 with 2009-2010. *BMJ Open* 2014;4(2):e004015. DOI: 10.1136/bmjopen-2013-004015.
2. Solebo AL, Teoh L, Rahi J. Epidemiology of blindness in children. *Arch Dis Child* 2017;102(9):853-857. DOI: 10.1136/archdischild-2016-310532.
3. Jayasundera KT, Abuzaitoun RO, Lacy GD, et al. Challenges of cost-effectiveness analyses of novel therapeutics for Inherited Retinal Diseases: Cost-effectiveness analysis in Inherited Retinal Diseases. *Am J Ophthalmol* 2021. DOI: 10.1016/j.ajo.2021.08.009.
4. Lacy GD, Abalem MF, Popova LT, et al. Content generation for patient-reported outcome measures for retinal degeneration therapeutic trials. *Ophthalmic Genet* 2020;41(4):315-324. DOI: 10.1080/13816810.2020.1776337.
5. Lacy GD, Abalem MF, Andrews CA, et al. The Michigan Retinal Degeneration Questionnaire: A Patient-Reported Outcome Instrument for Inherited Retinal Degenerations. *Am J Ophthalmol* 2021;222:60-68. DOI: 10.1016/j.ajo.2020.08.032.
6. Lacy GD, Abalem MF, Andrews CA, et al. The Michigan Vision-Related Anxiety Questionnaire: A Psychosocial Outcomes Measure for Inherited Retinal Degenerations. *Am J Ophthalmol* 2021;225:137-146. DOI: 10.1016/j.ajo.2020.12.001.
7. Wild D, Grove A, Martin M, et al. Principles of Good Practice for the Translation and Cultural Adaptation Process for Patient-Reported Outcomes (PRO) Measures: report of the ISPOR Task Force for Translation and Cultural Adaptation. *Value Health* 2005;8(2):94-104. DOI: 10.1111/j.1524-4733.2005.04054.x.

8. Eremenco S, Pease S, Mann S, Berry P, Subcommittee PROCsP. Patient-Reported Outcome (PRO) Consortium translation process: consensus development of updated best practices. *J Patient Rep Outcomes* 2017;2(1):12. DOI: 10.1186/s41687-018-0037-6.
9. Marques JP, Carvalho AL, Henriques J, Murta JN, Saraiva J, Silva R. Design, development and deployment of a web-based interoperable registry for inherited retinal dystrophies in Portugal: the IRD-PT. *Orphanet J Rare Dis* 2020;15(1):304. DOI: 10.1186/s13023-020-01591-6.
10. Rausch-Koster TP, van der Ham AJ, Terwee CB, Verbraak FD, van Rens G, van Nispen RMA. Translation and content validity of the Dutch Impact of Vision Impairment questionnaire assessed by Three-Step Test-Interviewing. *J Patient Rep Outcomes* 2021;5(1):1. DOI: 10.1186/s41687-020-00272-z.

Manuscript 14

**4.2. Self-reported visual function and psychosocial impact of visual loss in EYS-associated retinal degeneration in a Portuguese population**

João Pedro Marques

Ricardo Machado Soares

Sílvia Simão

Rehbi Abuzaitoun

Chris Andrews

C. Henrique Alves

António Francisco Ambrósio

Joaquim Murta

Rufino Silva

Maria Fernanda Abalem

K. Thiran Jayasundera

*Published in: Ophthalmic Genet. 2023 Mar 22;1-7. Online ahead of print.*

## ABSTRACT

**Purpose:** To evaluate self-reported visual function and the psychosocial impact of visual loss EYS-associated retinal degeneration (EYS-RD) using two patient-reported outcome (PRO) measures: Michigan Retinal Degeneration Questionnaire (MRDQ) and Michigan Vision-related Anxiety Questionnaire (MVAQ).

**Design:** Cross-sectional study

**Methods:** Single-center study conducted at a tertiary care hospital in Portugal. Patients with biallelic EYS variants were invited to participate. Clinical data including demographics, ETDRS best-corrected visual acuity (BCVA) in the better-seeing eye and genetic testing results were collected. Interviews were carried out during clinic visits or by phone between November 2021 and February 2022. A blind grader used horizontal and vertical spectral domain optical coherence tomography (SD-OCT) scans to manually measure ellipsoid zone (EZ) width in the nasal, temporal, superior and inferior macular quadrants to calculate the EZ area.

**Results:** Forty-nine patients (53.1% males; mean age  $53 \pm 14$  years) were included. In MRDQ, a positive correlation was found between age and central vision, color vision, contrast sensitivity, scotopic function, photopic peripheral vision and mesopic peripheral vision domain scores ( $p < 0.05$ ). A negative correlation was found between both BCVA and EZ area across all MRDQ domains. In MVAQ, SD-OCT EZ area negatively correlated with both rod function and cone function-related anxiety. Neither age, BCVA or gender correlated with MVAQ domains.

**Conclusions:** This study provides strong evidence supporting a correlation between PRO measures and both functional and structural clinician-reported outcomes. The use of MRDQ and MVAQ adds a new dimension to our understanding of EYS-RD and establishes both PRO measures as important disease outcome measures.



## INTRODUCTION

Eyes shut homolog (*EYS*, MIM \*612424) is the human ortholog of *Drosophila melanogaster* "eyes shut" protein and was first associated with autosomal recessive RP (arRP) in 2008<sup>1,2</sup>. Located on chromosome 6p12 (RP25 locus), with 44 exons spanning over 2 Mb of genomic DNA, *EYS* is the largest retina-specific gene. It encodes four protein isoforms, with its canonical isoform 4 coding for 3165 amino acids, harboring 27 epidermal growth factor (EGF)-like domains and five laminin G-like domains<sup>1-4</sup>. Although the concrete functions of these isoforms are uncertain, the *EYS* protein has been suggested to play an essential role in retinal morphogenesis, architecture, and ciliary transport<sup>3,4</sup>.

According to the Global Retinal Inherited Disease (GRID) dataset, the worldwide frequency of *EYS*-RD is 4.4%, making *EYS* the third most frequently mutated gene in inherited retinal degenerations (IRDs), lagging only behind *ABCA4* (24.8%) and *USH2A* (14.6%)<sup>5</sup>. Estimates indicate that *EYS* accounts for 5-33% of all non-syndromic arRP cases, with the highest prevalence observed in Japan (18-33%), Spain (15.9%) and France (12%)<sup>6-12</sup>. We have recently showed that *EYS* is responsible for ~28% of arRP cases and that it accounts for 9% of all IRD cases in Portugal, making it the most commonly mutated IRD gene (Soares et al, submitted). Even though *EYS*-associated retinal degeneration (*EYS*-RD) has been characterized by a relatively homogeneous and slowly progressive phenotype of RP on early reports<sup>6</sup>, recent studies highlighted its high genetic, phenotypic, and clinical heterogeneity<sup>13-17</sup>.

To facilitate the goal of assessing the efficacy of current and future therapies and investigating IRDs natural history in a precise and standardized manner, patient reported outcomes (PRO), obtained from valid and reliable questionnaires, are essential<sup>18</sup>. PRO instruments are valuable indicators of a patient's quality of life (QoL), functioning or disability from his/her own perspective, and are recognized as valid clinical trial outcome measures<sup>19</sup>. The Michigan Retinal Degeneration Questionnaire (MRDQ)<sup>20</sup> and the Michigan Vision-Related Anxiety Questionnaire (MVAQ)<sup>21</sup> are two psychometrically validated PRO questionnaires specifically designed to measure visual function and anxiety in IRDs, that have recently been translated and linguistically validated for use in Portuguese-speaking countries<sup>22</sup>.

The purpose of this study was (1) to evaluate patients' self-reported visual function and the psychosocial impact of visual loss in a Portuguese cohort of *EYS*-RD using MRDQ and MVAQ, and (2) to correlate MRDQ and MVAQ scores with functional [ETDRS best-corrected visual acuity (BCVA) in the better-seeing eye], structural [spectral domain optical coherence tomography (SD-OCT)-derived ellipsoid zone (EZ) area], and genetic data.

## **METHODS**

### ***Study Design and Population***

Cross-sectional study conducted at the Retinal Dystrophies Clinic of *Centro Hospitalar e Universitário de Coimbra* (CHUC), Portugal's largest IRD reference center. EYS-RD patients currently participating in a natural history study were invited to participate. Clinical records including demographics (age, gender, ethnicity), ETDRS BCVA in the better-seeing eye, genetic testing results, along with personal medical history data were collected from the electronic health record. Informed consent was obtained upon enrolment. The study was approved by the local Ethics Committee and followed the tenets of the Declaration of Helsinki for biomedical research.

### ***Michigan Retinal Degeneration Questionnaire (MRDQ) and Michigan Vision-related Anxiety Questionnaire (MVAQ)***

The Michigan Retinal Degeneration Questionnaire (MRDQ)<sup>20</sup> and the Michigan Vision-Related Anxiety Questionnaire (MVAQ)<sup>21</sup> are two psychometrically validated PRO measures specifically designed for IRDs, recently translated to Portuguese<sup>22</sup>. MRDQ measures the impact of visual handicap in daily tasks across five different dimensions (reading; colour and contrast; dark adaptation; mobility and peripheral vision; and light sensitivity) and contains 59 items pertaining to central vision (n=11), color vision (n=4), contrast sensitivity (n=7), scotopic function (n=12), photopic peripheral vision (n=9), mesopic peripheral vision (n=9), and photosensitivity (n=7)<sup>20</sup>; while MVAQ is a 14-item instrument with two domains: rod (6 items) and cone (8 items) function-related anxiety<sup>21</sup>. For both PRO measures, the higher the score, the higher the self-perceived compromise. The interviews were carried out during clinic visits or by phone from November 2021 through February 2022, with questions being read aloud by the interviewer (R.M.S. or J.P.M.), according to predefined guidelines.

### ***Spectral domain optical coherence tomography (SD-OCT)***

A blind grader (S. S.) used horizontal and vertical Spectralis® (Heidelberg Engineering, Heidelberg, Germany) SD-OCT scans to manually measure EZ width in the nasal, temporal, superior and inferior macular quadrants, according to a validated methodology<sup>23</sup>. OCT EZ area was calculated by separating the EZ into four quadrants (superionasal, superiotemporal, inferionasal, inferiotemporal). By assuming that the OCT EZ area is a semi-oval structure, each of the nasal, temporal, superior and inferior EZ widths were considered a radius. Therefore,

quadrant area between two adjacent radiuses equals  $Area = (\pi((r1 + r2)/2)^2)/4$ . Area for each quadrant was calculated then summed with the other quadrants to yield the OCT EZ area. From the two eyes, the larger of the OCT EZ area was used for analysis of associations.

### **Statistical analysis**

Latent trait scores (theta) were estimated for each domain in MRDQ and MVAQ using the *expected-a-posterior* method using a graded response model. Pearson's correlations were used to quantify the associations between the nine theta scores (MRDQ and MVAQ) and age, better eye logMAR visual acuity, SD-OCT EZ area, gender, and homozygosity for the c.(2023+1\_2024-1)\_2259+1\_2260-1)del p.(Gly676Glufs\*9) variant. Frequency distribution plots for the nine theta domains were graphed. Pearson correlation between SD-OCT EZ area (degree to which peripheral retinal degeneration has constricted intact macular anatomy) and scotopic function theta (severity of peripheral retinal degeneration and loss of rods) was graphed. Additionally, nine (one for each scale) multivariable regression models were used to assess the associations between the MRDQ/MVAQ domains and homozygosity for the c.(2023+1\_2024-1)\_2259+1\_2260-1)del p.(Gly676Glufs\*9) variant and other permutations of pathogenic variants adjusting for age.

## **RESULTS**

### **Demographic and Genetic data**

Forty-nine patients (53.1% male) with biallelic *EYS* clinically significant variants were included in the study (Table 1). The c.(2023+1\_2024-1)\_2259+1\_2260-1)del p.(Gly676Glufs\*9) was the most prevalent variant in our cohort, with an allele frequency (AF) of 39.80% (n=39). The second and third most frequent mutations were the c.5928-2A>G p.? and the c.4120C>T p.(Arg1374Ter) variants with an AF of 17.34% and 12.24%, respectively. Collectively, these 3 variants were responsible for almost 70% of the *EYS* mutations in this cohort.

**Table 1.** Cohort demographics

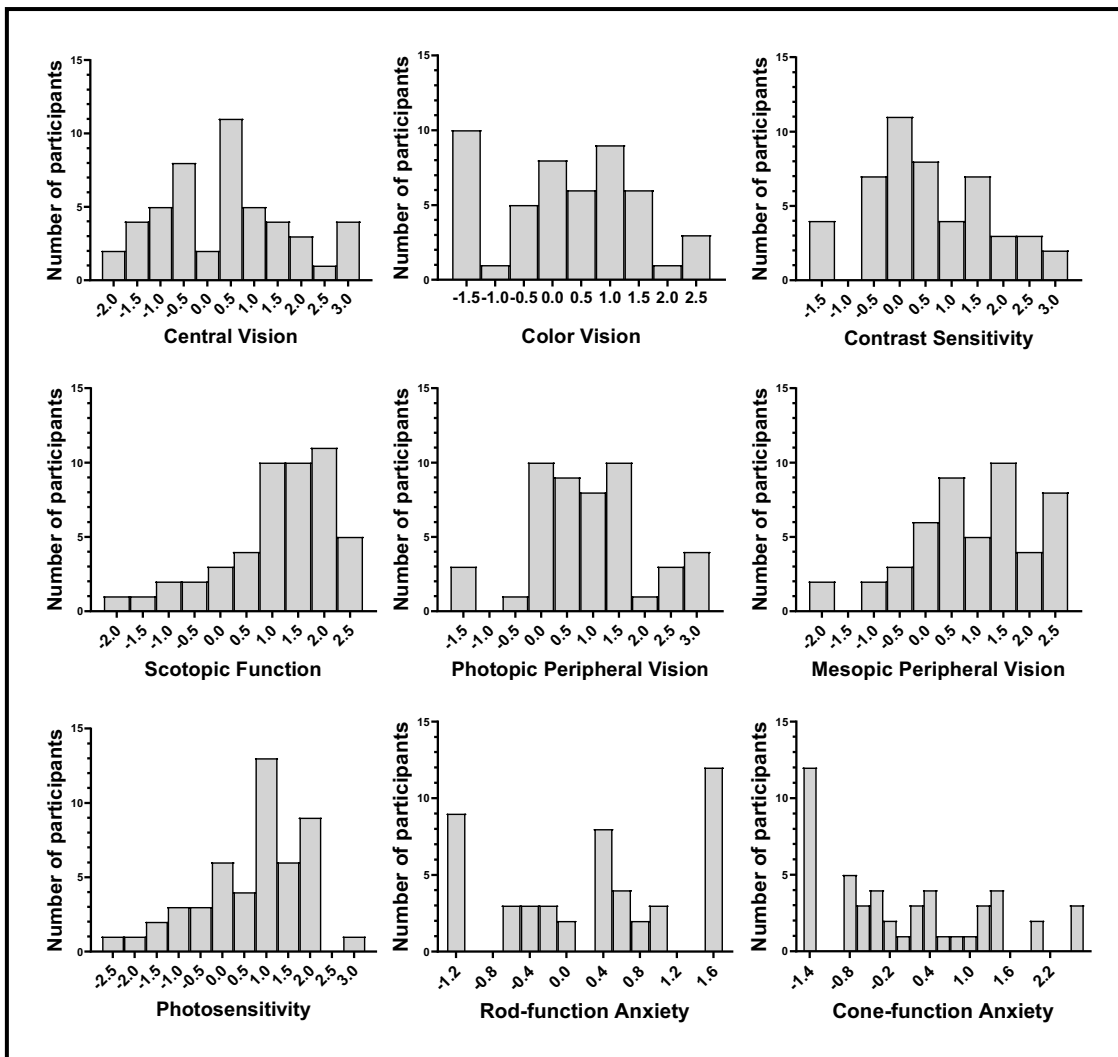
<b>Sample, n</b>	49
<b>Age (years), mean ± SD (Range)</b>	53 ± 14 (24-86)
<b>Male, n (%)</b>	26 (53.1)
<b>Caucasian, n (%)</b>	49 (100)
<b>Deletion mutation C_del, n (%)</b>	
<i>Homozygous</i>	13 (26.5)
<i>Heterozygous</i>	12 (24.5)
<i>Different variants</i>	24 (49)
<b>Better-seeing eye ETDRS letters, Median (IQR)</b>	70 (60-80)
<b>OCT ellipsoid zone area (mm<sup>2</sup>), Median (IQR)</b>	1.1*10 <sup>6</sup> (0-5.8*10 <sup>7</sup> )
OCT=Optical coherence tomography; ETDRS=Early treatment diabetic retinopathy study; C_del= the deletion mutation <i>c.(2023+1_2024-1)_(2259+1_2260-1)del</i> ; IQR=Interquartile Range	

### **Michigan Retinal Degeneration Questionnaire (MRDQ) and Michigan Vision-Related Anxiety Questionnaire (MVAQ)**

Frequency distribution graphs across MRDQ and MVAQ domains are shown in Figure 1. The median MRDQ scores for the different domains were: 0.52 for central vision, 0.33 for color vision, 0.49 for contrast sensitivity, 1.32 for scotopic function, 0.82 for photopic peripheral vision, 1.06 for mesopic peripheral vision, and 0.91 for photosensitivity. A positive correlation was found between age and central vision, color vision, contrast sensitivity, scotopic function, photopic peripheral vision and mesopic peripheral vision MRDQ domains, but not with photosensitivity (Table 2). A negative correlation was found between visual acuity in the better-seeing eye (ETDRS letters) and all MRDQ domains. The same was true for EZ area (Table 2). The negative correlation between SD-OCT EZ area and MRDQ scotopic function is graphically depicted in Figure 2.

The median MVAQ score for rod-function anxiety was 0.44 and -0.26 for cone-function anxiety. SD-OCT EZ area negatively correlated with both rod-function and cone-function anxiety (Table 2). Neither age, BCVA or gender correlated with MVAQ domains.

Univariate analyses to identify the presence of an association between the MRDQ/MVAQ domains and homozygosity for the most prevalent deletion (vs. other variants), and multivariate analysis adjusting for age, did not find a statistically significant association.



**Figure 1.** Domain scores frequency distribution histogram graphs for MRDQ and MVAQ

**Table 2.** Pearson correlations between PRO domain scores and age, visual acuity, SD-OCT EZ area, gender and zygosity.

Patient reported outcome	Statistic	Age	BCVA better-seeing eye (ETDRS letters)	SD-OCT EZ Area	Gender <sup>a</sup>	Homozygosity for deletion mutation <sup>b</sup>		
<b>MRDQ</b>	<i>Central Vision</i>	Pearson Correlation	<b>0.57</b>	<b>-0.8</b>	<b>-0.51</b>	-0.03	0.12	
		Sig. (2-tailed)	<.001	<.001	<.001	0.82	0.4	
	<i>Color Vision</i>	Pearson Correlation	<b>0.35</b>	<b>-0.57</b>	<b>-0.49</b>	-0.02	0.09	
		Sig. (2-tailed)	0.01	<.001	<.001	0.87	0.52	
	<i>Contrast Sensitivity</i>	Pearson Correlation	<b>0.48</b>	<b>-0.66</b>	<b>-0.53</b>	-0.08	0.09	
		Sig. (2-tailed)	<.001	<.001	<.001	0.57	0.52	
	<i>Scotopic Function</i>	Pearson Correlation	<b>0.46</b>	<b>-0.48</b>	<b>-0.65</b>	0.01	0.24	
		Sig. (2-tailed)	<.001	<.001	<.001	0.96	0.1	
	<i>Photopic Peripheral Vision</i>	Pearson Correlation	<b>0.5</b>	<b>-0.56</b>	<b>-0.54</b>	0.01	0.22	
		Sig. (2-tailed)	<.001	<.001	<.001	0.95	0.12	
	<i>Mesopic Peripheral Vision</i>	Pearson Correlation	<b>0.43</b>	<b>-0.48</b>	<b>-0.58</b>	0.04	0.14	
		Sig. (2-tailed)	0.002	<.001	<.001	0.79	0.33	
	<i>Photosensitivity</i>	Pearson Correlation	0.26	<b>-0.51</b>	<b>-0.45</b>	0.01	0.2	
		Sig. (2-tailed)	0.077	<.001	0.001	0.95	0.16	
	<b>MVAQ</b>	<i>Rod-function Anxiety</i>	Pearson Correlation	0.13	0.04	<b>-0.36</b>	0.23	-0.04
			Sig. (2-tailed)	0.37	0.78	0.01	0.11	0.76
<i>Cone-function Anxiety</i>		Pearson Correlation	0.21	-0.12	<b>-0.32</b>	0.24	-0.06	
		Sig. (2-tailed)	0.14	0.4	0.03	0.1	0.7	

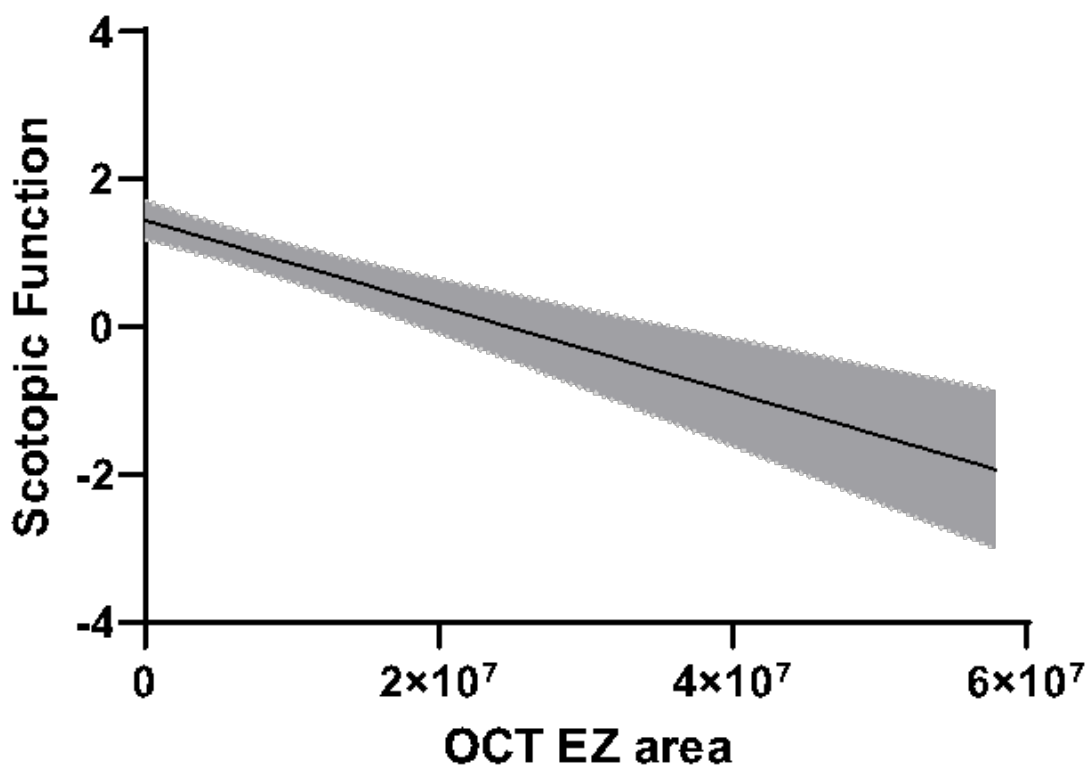
ETDRS=Early treatment diabetic retinopathy study; OCT=Optical coherence tomography; EZ=Ellipsoid zone; MRDQ=Michigan retinal degeneration questionnaire; MVAQ=Michigan vision-related anxiety questionnaire.

Pearson correlations for the table were computed from n=49 pairs except SD-OCT EZ Area (n=48).

<sup>a</sup> Point biserial correlation was used where Male=0, Female=1

<sup>b</sup> Homozygosity of the deletion mutation *c.(2023+1\_2024-1)\_(2259+1\_2260-1)del*. Point biserial correlation was used where Homozygous for mutation=1, Other (heterozygous + different variants)=0

Bold values indicate a significant (p<.05) Pearson correlation.



**Figure 2.** Graphical depiction of the negative correlation between MRDQ scotopic function score and SD-OCT EZ area. Smaller OCT EX area is associated with larger scotopic function disability.

## DISCUSSION

Vision loss has persistent negative effects on QoL and mental health. These effects can reach beyond the affected individual to family members who may struggle to adjust to new caretaking and supportive roles<sup>24,25</sup>. Self-perceived health has been more strongly associated with QoL than traditional clinical tests, suggesting that a patient's perception of his/her quality of vision may be more impactful on his/her QoL. Not surprisingly, individual QoL is one of the seven areas of emphasis of the 2021 National Eye Institute (NEI) Strategic Plan<sup>26,27</sup>. The authors highlight the importance of incorporating patient perspectives in vision-related QoL assessments for clinical research studies and PROs for measuring quality of care<sup>27</sup>. This is particularly important in IRDs since it remains difficult to detect therapeutic improvement using standard objective visual function testing<sup>18</sup>, in spite of the recent growth in clinical trials evaluating treatments for these conditions<sup>28</sup>.

In this study, we evaluated *EYS*-RD patients' self-reported visual function and the psychosocial impact of visual loss using the Portuguese versions of MRDQ and MVAQ<sup>22</sup>. In addition, we correlated specific MRDQ and MVAQ domains with functional, structural, and genetic data. Our results illustrate that self-perceived visual function in *EYS*-RD patients declines with age. A significant correlation was found between age and all visual function domains except for photosensitivity. Additionally, patients with worse visual acuity were the ones reporting more difficulties in all MRDQ dimensions, but neither age nor BCVA correlated with rod-function or cone-function associated anxiety. One possible explanation is the development of engaging coping strategies to achieve a positive adaptation to disease-related problems<sup>29,30</sup>. Research has shown that behavioral and psychoeducational interventions focusing on acceptance of the condition are important to develop skills to self-manage RP progression<sup>31</sup>. Another possible reason why BCVA did not correlate with MVAQ domains is that anxiety and depression may independently be associated with a worse self-perceived visual function. A study by Hahm et al<sup>32</sup> found poorer vision-related functions in RP patients with depression compared to those patients without depression, which could not be explained by visual acuity. The authors highlighted the need to treat anxiety and depression to ameliorate overall vision-related QoL in RP patients. Lastly, an effect of self-reporting bias (i.e., the reluctance to report symptoms that could be perceived as a weakness) should be kept in mind. Some studies have hypothesized that a different exposure to psychosocial stressors and an increased biologic and/or psychologic vulnerability towards anxiety in women may contribute to gender differences in vision-related anxiety.<sup>33-35</sup> This was not the case in our cohort as no correlation was found between gender and self-reported vision-related anxiety.

SD-OCT EZ area, calculated from the horizontal and vertical EZ widths, significantly correlated with both MRDQ and MVAQ scores across all the tested domains. This new SD-OCT biomarker provides evidence of a strong correlation between retinal structure and self-reported visual function and vision-related anxiety in *EYS*-RD. Regarding MRDQ domains, an almost perfect bell curve was observed on the central vision histogram, while a right deviation of the bell curve was observed in scotopic function and mesopic peripheral vision (Figure 1). This is somehow expected since *EYS* causes a rod-predominant disease, where nyctalopia and visual field constriction are the most striking symptoms, and central vision is usually preserved until late in the disease course. Nevertheless, the self-reported visual function results in our population mirror the phenotypical heterogeneity that characterizes *EYS*-RD, with the histograms showing variable distribution on other domains like color vision, or the presence of a relatively large proportion of patients affected by photosensitivity (Figure 1). The correlation between SD-OCT EZ area and MVAQ-related domains underlines the strength of this new



structural biomarker, which proved better than BCVA to estimate the visual disability burden of *EYS*-RD.

Finally, we could not find any correlation between homozygosity for the most prevalent deletion in our cohort and MRDQ or MVAQ scores. To date, no strong genotype-phenotype correlations have been established in *EYS*-RD. The same appears true regarding self-reported visual function and vision-related anxiety. Nevertheless, larger studies are needed to validate this finding.

This study is not exempt of limitations. First, the study population was not evenly distributed among racial/ethnic groups. The demographic of the study group represents the *EYS*-RD patient population at a particular academic institution in Portugal. Further investigation may be necessary to validate our findings across diverse cultural contexts. Second, we used BCVA on the better-seeing eye as the only surrogate of visual function. Nevertheless, to our knowledge this is the first study combining clinician-reported outcomes and two validated PRO measures aiming to better characterize a large population of *EYS*-RD. Our findings grant an improved understanding of *EYS*-associated disease by providing a more holistic form of patient care. Furthermore, we used a novel structural biomarker (EZ area) and revealed its utility in estimating disease burden for patients.

In conclusion, we provide strong evidence supporting a correlation between PRO measures and both functional (BCVA) and structural (EZ area) clinician-reported outcomes. The use of MRDQ and MVAQ in this study adds a new dimension to our understanding of *EYS*-RD and establishes both PRO measures as important disease outcome measures, which may be used in therapeutic trials.

## REFERENCES

1. Collin RW, Littink KW, Klevering BJ, et al. Identification of a 2 Mb human ortholog of *Drosophila* eyes shut/spacemaker that is mutated in patients with retinitis pigmentosa. *Am J Hum Genet* 2008;83(5):594-603. DOI: 10.1016/j.ajhg.2008.10.014.
2. Abd El-Aziz MM, Barragan I, O'Driscoll CA, et al. *EYS*, encoding an ortholog of *Drosophila* spacemaker, is mutated in autosomal recessive retinitis pigmentosa. *Nat Genet* 2008;40(11):1285-7. DOI: 10.1038/ng.241.
3. Garcia-Delgado AB, Valdes-Sanchez L, Morillo-Sanchez MJ, Ponte-Zuniga B, Diaz-Corrales FJ, de la Cerda B. Dissecting the role of *EYS* in retinal degeneration: clinical

- and molecular aspects and its implications for future therapy. *Orphanet J Rare Dis* 2021;16(1):222. DOI: 10.1186/s13023-021-01843-z.
4. Alfano G, Kruczek PM, Shah AZ, et al. EYS Is a Protein Associated with the Ciliary Axoneme in Rods and Cones. *PLoS One* 2016;11(11):e0166397. DOI: 10.1371/journal.pone.0166397.
  5. Schneider N, Sundaresan Y, Gopalakrishnan P, et al. Inherited retinal diseases: Linking genes, disease-causing variants, and relevant therapeutic modalities. *Prog Retin Eye Res* 2022;89:101029. DOI: 10.1016/j.preteyeres.2021.101029.
  6. Littink KW, van den Born LI, Koenekoop RK, et al. Mutations in the EYS gene account for approximately 5% of autosomal recessive retinitis pigmentosa and cause a fairly homogeneous phenotype. *Ophthalmology* 2010;117(10):2026-33, 2033 e1-7. DOI: 10.1016/j.ophtha.2010.01.040.
  7. Bandah-Rozenfeld D, Littink KW, Ben-Yosef T, et al. Novel null mutations in the EYS gene are a frequent cause of autosomal recessive retinitis pigmentosa in the Israeli population. *Invest Ophthalmol Vis Sci* 2010;51(9):4387-94. DOI: 10.1167/iovs.09-4732.
  8. Audo I, Sahel JA, Mohand-Said S, et al. EYS is a major gene for rod-cone dystrophies in France. *Hum Mutat* 2010;31(5):E1406-35. DOI: 10.1002/humu.21249.
  9. Barragan I, Borrego S, Pieras JI, et al. Mutation spectrum of EYS in Spanish patients with autosomal recessive retinitis pigmentosa. *Hum Mutat* 2010;31(11):E1772-800. DOI: 10.1002/humu.21334.
  10. Iwanami M, Oshikawa M, Nishida T, Nakadomari S, Kato S. High prevalence of mutations in the EYS gene in Japanese patients with autosomal recessive retinitis pigmentosa. *Invest Ophthalmol Vis Sci* 2012;53(2):1033-40. DOI: 10.1167/iovs.11-9048.
  11. Arai Y, Maeda A, Hiramami Y, et al. Retinitis Pigmentosa with EYS Mutations Is the Most Prevalent Inherited Retinal Dystrophy in Japanese Populations. *J Ophthalmol* 2015;2015:819760. DOI: 10.1155/2015/819760.
  12. Iwanami M, Oishi A, Ogino K, et al. Five major sequence variants and copy number variants in the EYS gene account for one-third of Japanese patients with autosomal recessive and simplex retinitis pigmentosa. *Mol Vis* 2019;25:766-779.
  13. Pierrache LHM, Messchaert M, Thiadens A, et al. Extending the Spectrum of EYS-Associated Retinal Disease to Macular Dystrophy. *Invest Ophthalmol Vis Sci* 2019;60(6):2049-2063. DOI: 10.1167/iovs.18-25531.
  14. Gao FJ, Wang DD, Hu FY, et al. Genotypic spectrum and phenotype correlations of EYS-associated disease in a Chinese cohort. *Eye (Lond)* 2021. DOI: 10.1038/s41433-021-01794-6.

15. Marques JP, Porto FBO, Carvalho AL, et al. EYS-Associated Sector Retinitis Pigmentosa. *Graefes Arch Clin Exp Ophthalmol* 2022;260(4):1405-1413. DOI: 10.1007/s00417-021-05411-w.
16. Sengillo JD, Lee W, Nagasaki T, et al. A Distinct Phenotype of Eyes Shut Homolog (EYS)-Retinitis Pigmentosa Is Associated With Variants Near the C-Terminus. *Am J Ophthalmol* 2018;190:99-112. DOI: 10.1016/j.ajo.2018.03.008.
17. Marques JP, Simao J. Double Concentric Hyperautofluorescent Ring in EYS-Associated Retinitis Pigmentosa. *Asia Pac J Ophthalmol (Phila)* 2022. DOI: 10.1097/APO.0000000000000473.
18. Lacy GD, Abalem MF, Popova LT, et al. Content generation for patient-reported outcome measures for retinal degeneration therapeutic trials. *Ophthalmic Genet* 2020;41(4):315-324. DOI: 10.1080/13816810.2020.1776337.
19. Rausch-Koster TP, van der Ham AJ, Terwee CB, Verbraak FD, van Rens G, van Nispen RMA. Translation and content validity of the Dutch Impact of Vision Impairment questionnaire assessed by Three-Step Test-Interviewing. *J Patient Rep Outcomes* 2021;5(1):1. DOI: 10.1186/s41687-020-00272-z.
20. Lacy GD, Abalem MF, Andrews CA, et al. The Michigan Retinal Degeneration Questionnaire: A Patient-Reported Outcome Instrument for Inherited Retinal Degenerations. *Am J Ophthalmol* 2021;222:60-68. DOI: 10.1016/j.ajo.2020.08.032.
21. Lacy GD, Abalem MF, Andrews CA, et al. The Michigan Vision-Related Anxiety Questionnaire: A Psychosocial Outcomes Measure for Inherited Retinal Degenerations. *Am J Ophthalmol* 2021;225:137-146. DOI: 10.1016/j.ajo.2020.12.001.
22. Marques JP, Bernardes L, Oliveira C, et al. Portuguese translation and linguistic validation of the Michigan Retinal Degeneration Questionnaire and the Michigan Vision-Related Anxiety Questionnaire in a cohort with inherited retinal degenerations. *Ophthalmic Genet* 2022;43(1):137-139. DOI: 10.1080/13816810.2022.2025609.
23. Otte B, Andrews C, Lacy G, Branham K, Musch DC, Jayasundera KT. Clinical trial design for neuroprotection in RHO autosomal dominant retinitis pigmentosa; outcome measure considerations. *Ophthalmic Genet* 2021;42(2):170-177. DOI: 10.1080/13816810.2020.1867752.
24. D'Amada CS, Nolen R, Huryn LA, Turriff A. Psychosocial impacts of Mendelian eye conditions: A systematic literature review. *Surv Ophthalmol* 2020;65(5):562-580. DOI: 10.1016/j.survophthal.2020.02.002.
25. Bambara JK, Wadley V, Owsley C, Martin RC, Porter C, Dreer LE. Family Functioning and Low Vision: A Systematic Review. *J Vis Impair Blind* 2009;103(3):137-149.

26. Chiang MF, Tumminia SJ. The 2021 National Eye Institute Strategic Plan: Eliminating Vision Loss and Improving Quality of Life. *Ophthalmology* 2022;129(1):12-14. DOI: 10.1016/j.ophtha.2021.09.012.
27. Chiang MF. The 2021 National Eye Institute Strategic Plan-Relating Vision to Health and Quality of Life. *JAMA Ophthalmol* 2021;139(12):1263-1265. DOI: 10.1001/jamaophthalmol.2021.4774.
28. Botto C, Rucli M, Tekinsoy MD, Pulman J, Sahel JA, Dalkara D. Early and late stage gene therapy interventions for inherited retinal degenerations. *Prog Retin Eye Res* 2021;100975. DOI: 10.1016/j.preteyeres.2021.100975.
29. Anil K, Garip G. Coping strategies, vision-related quality of life, and emotional health in managing retinitis pigmentosa: a survey study. *BMC Ophthalmol* 2018;18(1):21. DOI: 10.1186/s12886-018-0689-2.
30. Prem Senthil M, Khadka J, Pesudovs K. Seeing through their eyes: lived experiences of people with retinitis pigmentosa. *Eye (Lond)* 2017;31(5):741-748. DOI: 10.1038/eye.2016.315.
31. Garip G, Kamal A. Systematic review and meta-synthesis of coping with retinitis pigmentosa: implications for improving quality of life. *BMC Ophthalmol* 2019;19(1):181. DOI: 10.1186/s12886-019-1169-z.
32. Hahm BJ, Shin YW, Shim EJ, et al. Depression and the vision-related quality of life in patients with retinitis pigmentosa. *Br J Ophthalmol* 2008;92(5):650-4. DOI: 10.1136/bjo.2007.127092.
33. Altemus M, Sarvaiya N, Neill Epperson C. Sex differences in anxiety and depression clinical perspectives. *Front Neuroendocrinol* 2014;35(3):320-30. DOI: 10.1016/j.yfrne.2014.05.004.
34. Calling S, Midlov P, Johansson SE, Sundquist K, Sundquist J. Longitudinal trends in self-reported anxiety. Effects of age and birth cohort during 25 years. *BMC Psychiatry* 2017;17(1):119. DOI: 10.1186/s12888-017-1277-3.
35. McLean CP, Asnaani A, Litz BT, Hofmann SG. Gender differences in anxiety disorders: prevalence, course of illness, comorbidity and burden of illness. *J Psychiatr Res* 2011;45(8):1027-35. DOI: 10.1016/j.jpsychires.2011.03.006.

## **CHAPTER 5: OPHTHALMIC IMAGING IN IRD**



Manuscript 15

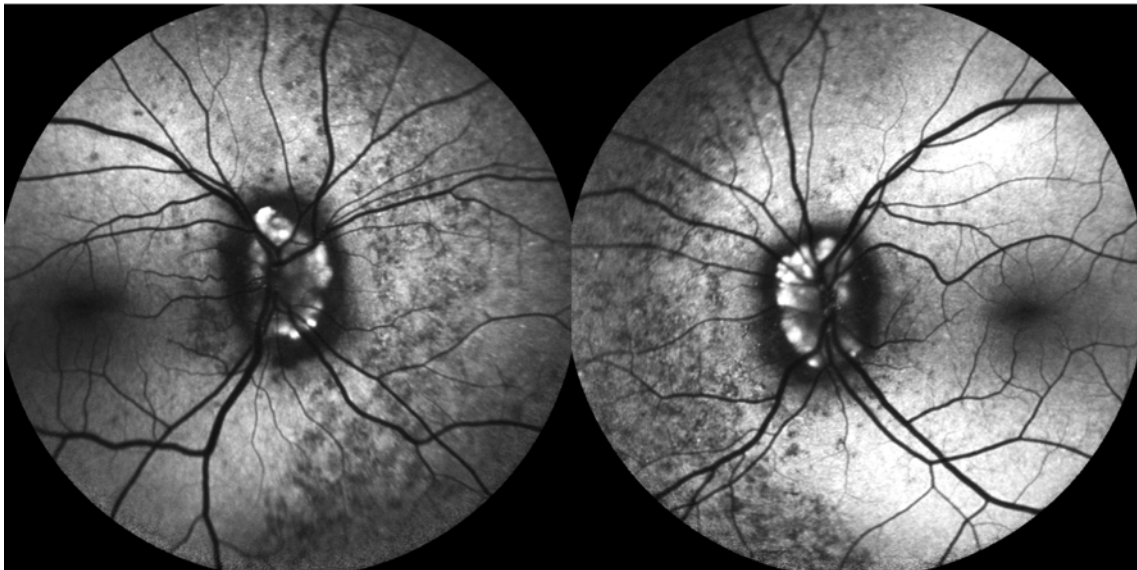
**5.1. MFRP-Related Nanophthalmos-Retinitis Pigmentosa-Foveoschisis-Optic Disc Drusen Syndrome**

João Pedro Marques

*Published in: Ophthalmic Surg Lasers Imaging Retina. 2021 Feb 1;52(2):110.*

## MANUSCRIPT

First described in 2006,<sup>1</sup> this syndrome is an extremely rare autosomal recessive disorder caused by biallelic variants in the membrane frizzled-related protein (MFRP) gene. Located on chromosome 11q23, and expressed mainly in the retinal pigment epithelium (RPE) and ciliary body, the *MFRP* gene is responsible for controlling eye growth and posterior segment development.<sup>2,3</sup> This 27 year-old male patient presented with high hyperopia, nanophthalmos, and complains of nyctalopia from an early age. The fundus was remarkable for the presence of bilateral optic disc drusen, patches of outer retinal atrophy and a few foci of pigment clumping in the midperiphery. These features can be clearly observed on fundus autofluorescence (Figure 1). Optical coherence tomography showed outer retinal layer schisis with absence of the foveal pit. Genetic testing revealed a likely pathogenic variant in the *MFRP* gene in homozygosity, thus establishing a final diagnosis.



**Figure 1.** Fundus Autofluorescence in MFRP-related retinal dystrophy. Multiple bilateral hyperautofluorescent globular structures in the optic nerve head represent optic disc drusen, while numerous hypoautofluorescent dots outside the vascular arcades represent patches of outer retinal atrophy.



## REFERENCES

1. Ayala-Ramirez R, Graue-Wiechers F, Robredo V, Amato-Almanza M, Horta-Diez I, Zenteno JC. A new autosomal recessive syndrome consisting of posterior microphthalmos, retinitis pigmentosa, foveoschisis, and optic disc drusen is caused by a MFRP gene mutation. *Mol Vis* 2006;12:1483-9.
2. Godinho G, Madeira C, Grangeia A, et al. A novel MFRP gene variant in a family with posterior microphthalmos, retinitis pigmentosa, foveoschisis, and foveal hypoplasia. *Ophthalmic Genet* 2020;41(5):474-479. DOI: 10.1080/13816810.2020.1795888.
3. Zenteno JC, Buentello-Volante B, Quiroz-Gonzalez MA, Quiroz-Reyes MA. Compound heterozygosity for a novel and a recurrent MFRP gene mutation in a family with the nanophthalmos-retinitis pigmentosa complex. *Mol Vis* 2009;15:1794-8.



Manuscript 16

**5.2. SLC24A1-Associated Congenital Stationary Night Blindness in a woman with an abnormal fundus**

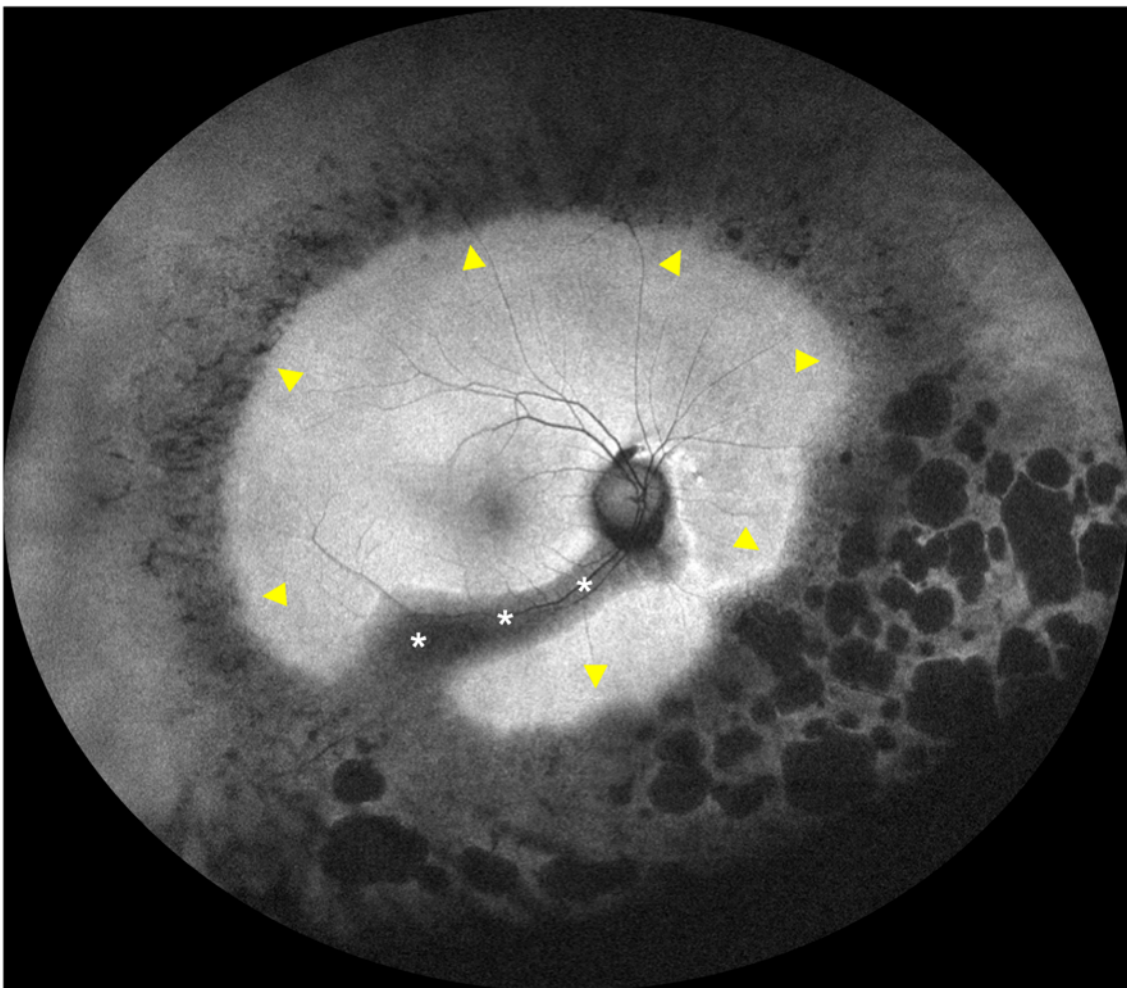
João Pedro Marques

João Chaves

*Published in: JAMA Ophthalmol. 2022 Apr 1;140(4):e216343.*

## MANUSCRIPT

Congenital stationary night blindness (CSNB) is genetically and phenotypically heterogeneous, with both complete (ON-bipolar dysfunction) and incomplete (both ON- and OFF-bipolar dysfunction) forms described. *SLC24A1*-associated CSNB is a rare form of autosomal recessive CSNB.<sup>1,2</sup> This case reports to a White female, by self-report, with a longstanding history of nyctalopia. Best-corrected visual acuity was 20/32 right eye and 20/25 left eye. Bilateral and symmetrical atrophic perivascular changes affecting the inferior temporal vascular arcade and merging into a 360° area of peripheral retinal pigment epithelium atrophy and bone-spicule hyperpigmentation were seen, with a peculiar fundus autofluorescence pattern (Figure 1). Electrophysiology testing showed a Riggs type CSNB and genetic testing identified the c.823\_824del p.(Val275Hisfs\*15) variant in homozygosity in the *SLC24A1* gene.



**Figure 1.** Ultra-widefield fundus autofluorescence of right eye in a female with *SLC24A1*-associated CSNB. Peripheral hypoautofluorescence for 360° (yellow arrowheads) and perivascular hypoautofluorescence affecting the inferior temporal vascular arcade (white asterisks) is observed.

## REFERENCES

1. Riazuddin SA, Shahzadi A, Zeitz C, et al. A mutation in *SLC24A1* implicated in autosomal-recessive congenital stationary night blindness. *Am J Hum Genet* 2010;87(4):523-31. DOI: 10.1016/j.ajhg.2010.08.013.
2. Neuille M, Malaichamy S, Vadala M, et al. Next-generation sequencing confirms the implication of *SLC24A1* in autosomal-recessive congenital stationary night blindness. *Clin Genet* 2016;89(6):690-9. DOI: 10.1111/cge.12746.



Manuscript 17

### **5.3. Multimodal Imaging in Hypotrichosis with Juvenile Macular Degeneration**

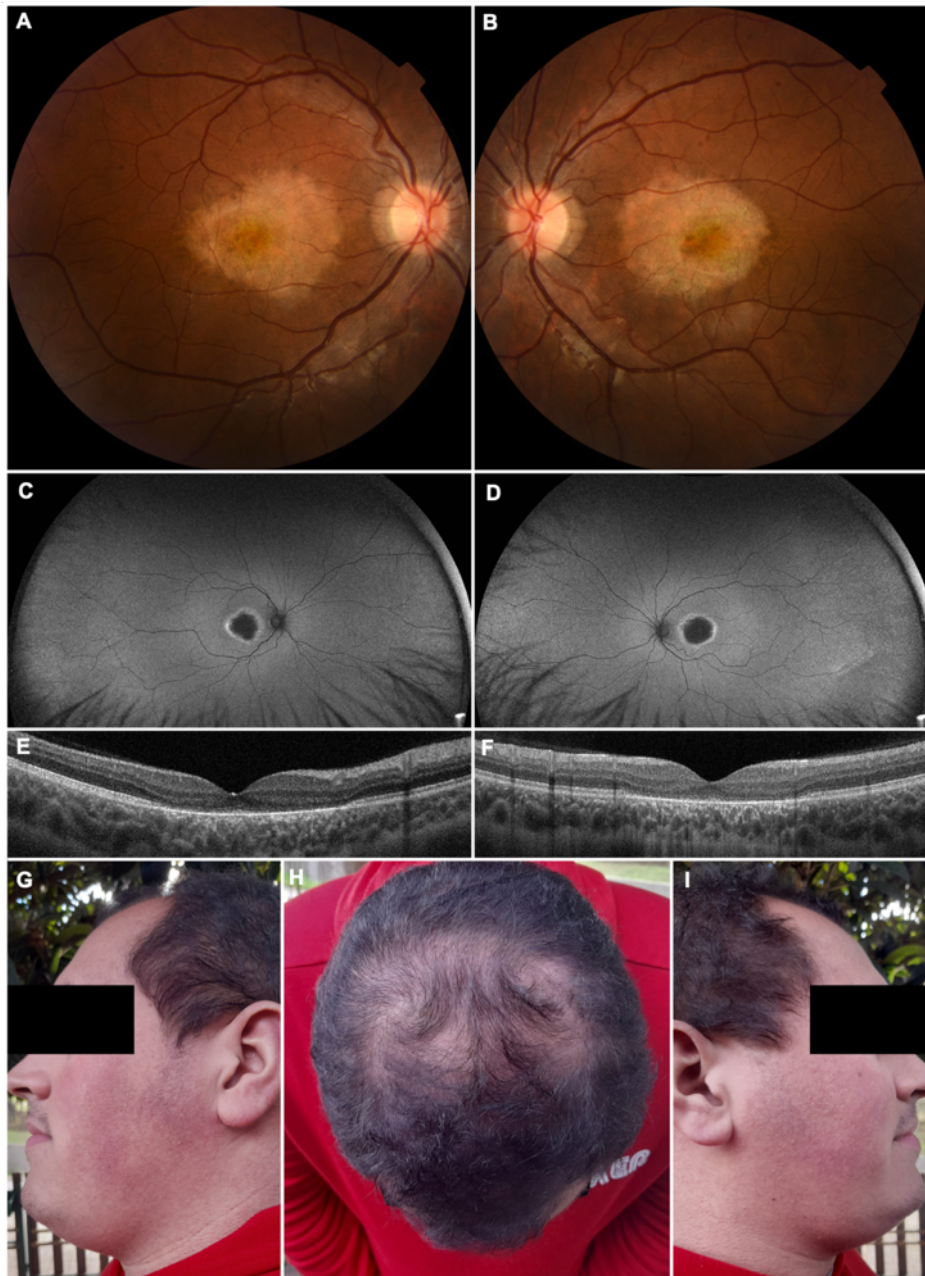
João Pedro Marques

Sara Geada

*Published in: Ophthalmol Retina. 2021 Jun;5(6):593.*

## DESCRIPTION

A 19-year-old male was referred due to progressive vision loss and hemeralopia since pre-school age. Best-corrected visual acuity was 20/40 OU. Bilateral and symmetrical macular atrophy was observed (A-B), translating into central hypoautofluorescence with an hyperautofluorescent border on fundus autofluorescence (C-D) and outer retinal atrophy with residual foveal sparing on optical coherence tomography (E-F). Physical examination revealed sparse, short and thin scalp hair (G-I), which according to the patient was present from the first months of life. No abnormalities were found in the skin, nails, limbs or teeth. Genetic testing revealed a likely pathogenic variant in the *CDH3* gene (16q22.1) in homozygosity, thus establishing the diagnosis of Hypotrichosis with Juvenile Macular Degeneration.





Manuscript 18

#### **5.4. Gyrate atrophy of the choroid and retina**

João Pedro Marques

Pedro Pereira

*Published in: Postgrad Med J. 2022 Apr;98(1158):308.*

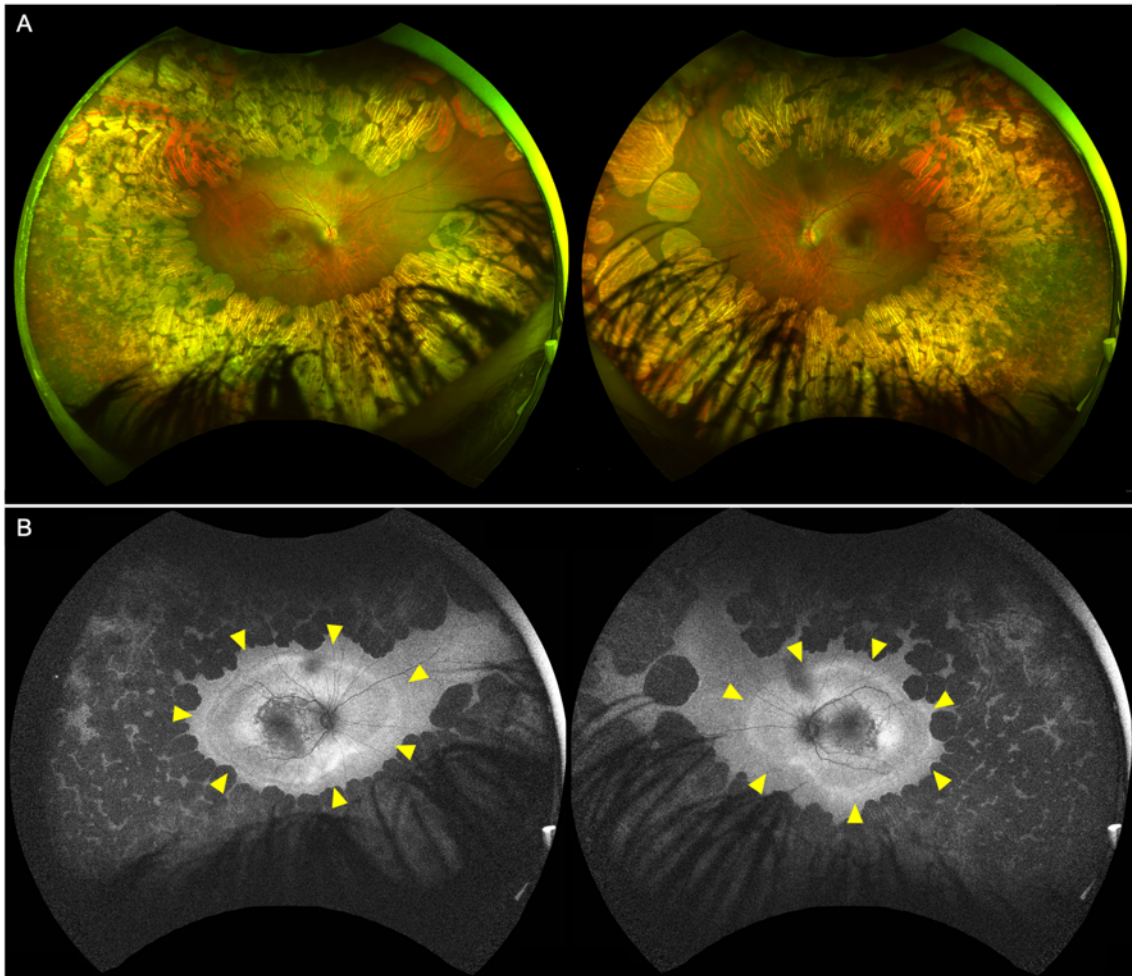
## DESCRIPTION

A 20-year-old high myope male was referred due to peripheral vision loss. Best-corrected visual acuity was 20/32 OD and 20/50 OS. On slit-lamp examination, mild bilateral posterior subcapsular cataract was observed. Peripheral areas of scalloped chorioretinal atrophy with macular sparing were identified on fundus examination (Figure 1). Humphrey 24-2 visual field testing revealed bilateral peripheral visual field amputation. A clinical diagnosis of gyrate atrophy of the choroid and retina (GACR, MIM #258870) was established, further supported by increased plasma and urine ornithine levels. The diagnosis was confirmed by genetic testing with the identification of compound heterozygous variants in the *OAT* gene.

GACR is a rare genetic condition of autosomal recessive inheritance resulting from mutations in the *OAT* gene (10q26) which codes for the ornithine-degrading, pyridoxal phosphate-dependent enzyme ornithine aminotransferase.<sup>1</sup> Defective ornithine metabolism results in the accumulation of ornithine in the plasma, urine, cerebrospinal fluid, and aqueous humor.<sup>2</sup> Although the *OAT* enzyme is expressed in many tissues, the main pathological manifestations involve the eye, possibly due to the toxic effects of hyperornithinemia on the retinal pigment epithelium.<sup>1,3</sup>

GACR is characterized by the development of chorioretinal atrophic patches starting in the mid-peripheral retina and spreading centrally, ultimately involving the macula. Myopia, early-onset posterior subcapsular cataracts and cystoid macular edema are frequently observed. Most patients will become legally blind by the fourth or fifth decade.<sup>4</sup> Treatment involves dietary modifications, low-vision aids and management of ocular complications.<sup>1</sup>

The patient was started on an arginine-restricted and low-protein diet, along with pyridoxine supplementation, as these have shown to slow the progression of the chorioretinal atrophy.<sup>2,5</sup>



**Figure 1. Ultra-widefield color fundus photography and fundus autofluorescence in Gyrate Atrophy of the Choroid and Retina.** Bilateral and symmetrical scalloped areas of peripheral chorioretinal atrophy with macular sparing (Figure 1A) are observed, translating in well-demarcated patches of hypoautofluorescence on fundus autofluorescence (Figure 1B). A hyperautofluorescent band (yellow arrowheads) defines the transition between affected and unaffected retina.

## REFERENCES

1. Elnahry AG, Tripathy K. Gyrate Atrophy Of The Choroid and Retina. StatPearls. Treasure Island (FL)2020.
2. Wang T, Steel G, Milam AH, Valle D. Correction of ornithine accumulation prevents retinal degeneration in a mouse model of gyrate atrophy of the choroid and retina. Proc Natl Acad Sci U S A 2000;97(3):1224-9. DOI: 10.1073/pnas.97.3.1224.

3. Simell O, Takki K. Raised plasma-ornithine and gyrate atrophy of the choroid and retina. *Lancet* 1973;1(7811):1031-3. DOI: 10.1016/s0140-6736(73)90667-3.
4. Takki KK, Milton RC. The natural history of gyrate atrophy of the choroid and retina. *Ophthalmology* 1981;88(4):292-301. DOI: 10.1016/s0161-6420(81)35031-3.
5. Kaiser-Kupfer MI, Caruso RC, Valle D. Gyrate atrophy of the choroid and retina. Long-term reduction of ornithine slows retinal degeneration. *Arch Ophthalmol* 1991;109(11):1539-48. DOI: 10.1001/archophth.1991.01080110075039.

Manuscript 19

**5.5. Double concentric hyperautofluorescent ring in EYS-Associated Retinitis Pigmentosa**

João Pedro Marques

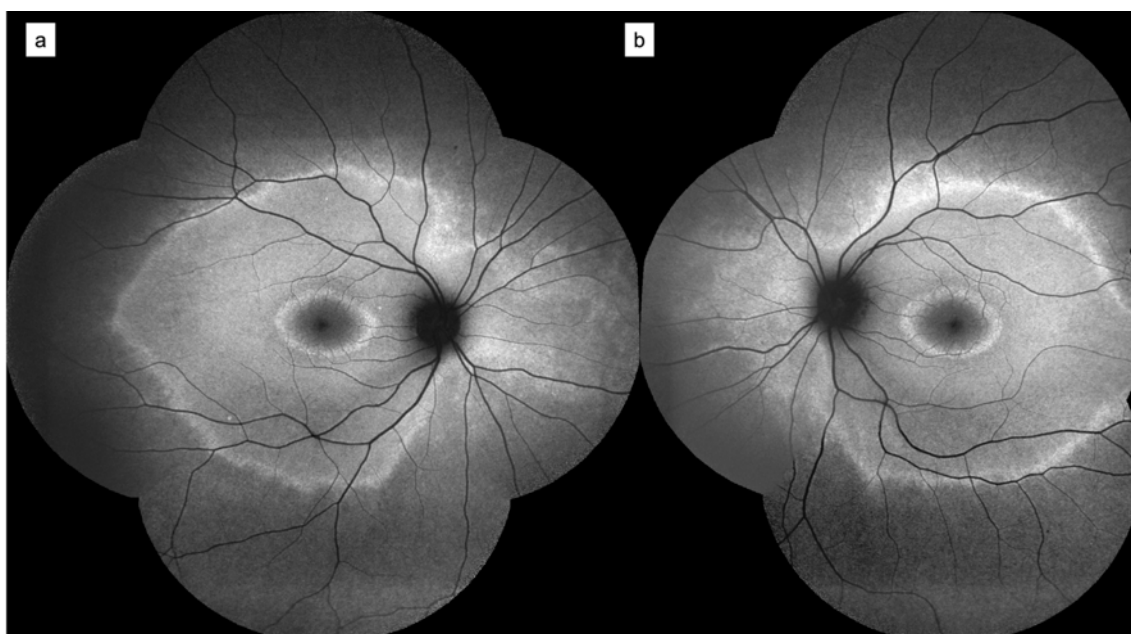
Jorge Simão

*Published in: Asia Pac J Ophthalmol (Phila). 2022 Feb 7. Online ahead of print.*

## MANUSCRIPT

A 37-year-old Caucasian female with consanguineous parents and a brother with non-syndromic retinitis pigmentosa (nsRP) presented with longstanding nyctalopia. Best-corrected visual acuity was 20/20 OU. Anterior segment examination and fundoscopy were unremarkable. Blue-light fundus autofluorescence (FAF) revealed a bilateral and symmetrical double concentric hyperautofluorescent ring (Figure 1). On spectral-domain optical coherence tomography, the retinal structure was preserved inside the inner ring, whereas outer retinal atrophy was observed outside its limits. Genetic testing identified the c.5928-2A>G p.? pathogenic variant in homozygosity in *EYS* gene.

Whereas a perifoveal/perimacular ring of hyperautofluorescence is a common FAF finding across several RP genotypes,<sup>1</sup> the presence of a double concentric hyperautofluorescent ring was deemed pathognomonic of *NR2E3*-associated autosomal-dominant RP.<sup>2</sup> We describe for the first time the occurrence of this peculiar FAF phenotype in *EYS*-associated nsRP, highlighting that FAF alone does not seem to be a reliable method of distinguishing between RP genotypes.



**Figure 1.** Double concentric hyperautofluorescent ring in *EYS*-associated retinitis pigmentosa. Right (a) and left (b) FAF highlights two hyperautofluorescent rings: an inner perifoveal ring; and an outer ring, located along the vascular arcades and demarcating a diffuse hyperautofluorescent annular surface area.

## REFERENCES

1. Lima LH, Cella W, Greenstein VC, et al. Structural assessment of hyperautofluorescent ring in patients with retinitis pigmentosa. *Retina* 2009;29(7):1025-31. DOI: 10.1097/IAE.0b013e3181ac2418.
2. Escher P, Tran HV, Vaclavik V, Borruat FX, Schorderet DF, Munier FL. Double concentric autofluorescence ring in NR2E3-p.G56R-linked autosomal dominant retinitis pigmentosa. *Invest Ophthalmol Vis Sci* 2012;53(8):4754-64. DOI: 10.1167/iovs.11-8693.





Manuscript 20

**5.6. Genetic, Anatomical, and Functional Correlation of Sector Retinitis Pigmentosa**

Mariana Oliveira

Emmanuel Neves

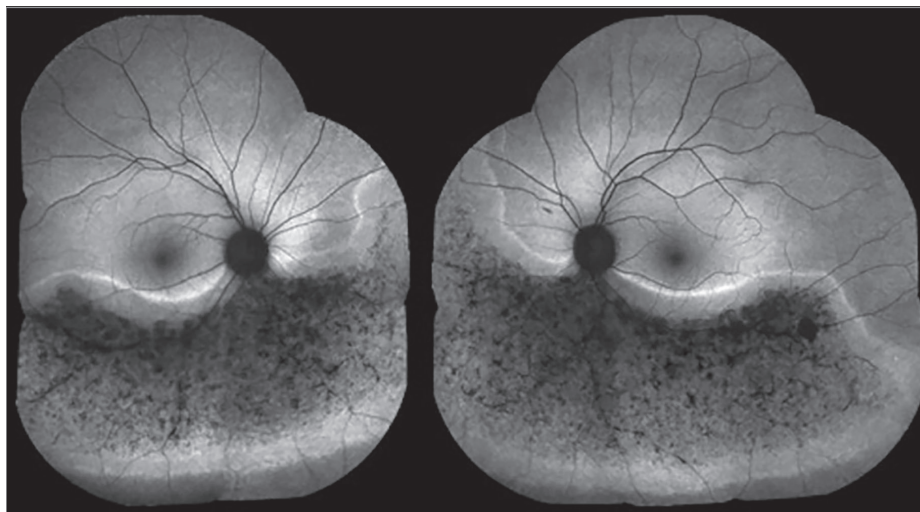
João Pedro Marques

*Published in: JAMA Ophthalmol. 2020 Jun 1;138(6):e193133.*

## MANUSCRIPT

A 40-year-old woman presented with floaters in her right eye after trauma. Her uncorrected visual acuity was 20/20 OU, and biomicroscopy generated unremarkable findings in both eyes. Symmetric bone-spicule hyperpigmentation circumscribed to the inferior quadrants was seen on ophthalmoscopy, with a corresponding hypoautofluorescent area on fundus autofluorescence (Figure 1). An anatomic-functional correlation was observed in automated perimetry, with a superior bilateral altitudinal defect. Genetic testing revealed a mutation in the rhodopsin (RHO) gene.

Sector retinitis pigmentosa is a rare and atypical form of retinitis pigmentosa in which only 1 or 2 retinal quadrants are affected. It is usually a stable or slowly progressive disorder. Patients may be completely asymptomatic or report visual field defects, depending on the extent of retinal involvement.<sup>1-3</sup>



**Figure 1.** Blue-light fundus autofluorescence of a patient with sector retinitis pigmentosa depicting inferior hypoautofluorescence corresponding to the bone-spicule hyperpigmentation observed on ophthalmoscopy, as well as a hyperautofluorescent band. The mosaic photographs were created using i2k Align Retina software, version 2.1.6 (DualAlign).

## REFERENCES

1. Van Woerkom C, Ferrucci S. Sector retinitis pigmentosa. *Optometry* 2005;76(5):309-17. DOI: 10.1016/s1529-1839(05)70314-6.
2. Berson EL, Howard J. Temporal aspects of the electroretinogram in sector retinitis pigmentosa. *Arch Ophthalmol* 1971;86(6):653-65. DOI: 10.1001/archopht.1971.01000010655008.
3. Omphroy CA. Sector retinitis pigmentosa and chronic angle-closure glaucoma: a new association. *Ophthalmologica* 1984;189(1-2):12-20. DOI: 10.1159/000309379.



Manuscript 21

**5.7. Subretinal bleb of Voretigene Neparvovec**

João Pedro Marques

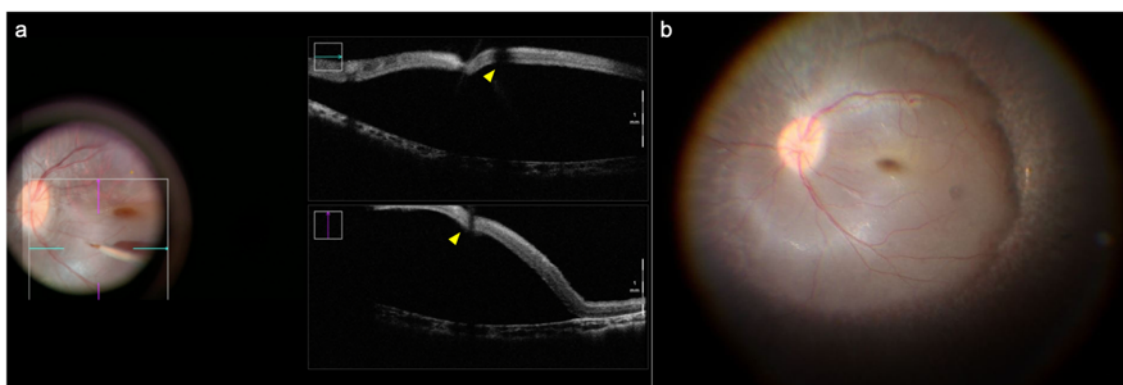
Mário Alfaiate

João Pereira Figueira

*Published in: Asia Pac J Ophthalmol (Phila). 2022 Mar-Apr;11(2):211.*

## MANUSCRIPT

Voretigene neparvovec (VN) was the first (and is currently the only) approved gene therapy for use in Ophthalmology. Treatment is directed at *RPE65*-associated retinal degeneration, a severe form of inherited retinal blindness. The procedure starts with a 3-port 25Ga pars plana vitrectomy. A normal copy of the native human RPE65 cDNA is delivered to the diseased retinal pigment epithelium (RPE) cells after subretinal injection of 0.3mL of the therapeutic solution containing a recombinant adeno-associated virus. Intraoperative optical coherence tomography (iOCT) can confirm the correct placement of the injection cannula and document the bleb formation in real time (Figure 1). The procedure is finalized with a fluid-air exchange in the vitreous cavity in order to remove any VN that may have refluxed from the subretinal injection site and to provide tamponade.



**Figure 1.** Intraoperative voretigene neparvovec bleb formation. The correct location of the injection cannula in the subretinal space can be confirmed with intraoperative optical coherence tomography (Figure 1a, yellow arrowheads). As a small bleb begins to form, the injection process continues slowly until the full 0.3mL of the therapeutic viral solution is injected subretinally. After completing the injection, a large subretinal bleb of voretigene neparvovec is observed (Figure 1b). Intraoperative images were captured with the Zeiss Artevo 800 surgical microscope.

## **CHAPTER 6: GENERAL DISCUSSION**





## **6. GENERAL DISCUSSION**

The global aim of the IRD-PT study was to improve the understanding of the clinical and molecular characteristics of IRDs in Portugal. In this chapter we elaborate on the main findings described in this thesis and their clinical relevance, placing them in a broader, future perspective.

### **6.1. Widely available genetic testing for IRDs: a clinical necessity**

Determining the genetic cause of an IRD allows accurate assessment of risk to other family members and can provide much-needed insight and understanding of the disease for those affected, including useful prognostic information. Furthermore, genetic stratification of affected individuals is increasingly being used to direct specific treatment options.<sup>1</sup> As ophthalmology takes a deep dive into precision medicine, effective and individualized approaches to clinical management of IRDs are consequently dependent upon a comprehensive means of delivering genetic or genomic testing.<sup>2</sup> While genetic testing for IRDs is now recognized as an important component of clinical care by clinicians, patient groups and clinical scientists, financial, and logistical barriers prevent its widespread application in European member states.<sup>3,4</sup> In an effort to overcome these barriers, the ERN-EYE published a position paper (Manuscript 2, chapter 2) emphasizing the clinical need and relevance of genetic testing in rare eye diseases.<sup>3</sup> Focusing on clinical benefit ('clinical utility') of genomic testing is an urgent requirement to provide governments with clear-cut evidence for widespread implementation. As pointed out in the EVICR.net IRD Survey that we co-authored (Annex I), inequalities in the access to genetic testing and in the time to receive results exist both across and within countries,<sup>4</sup> highlighting the need to develop guidelines for genetic testing in IRDs. This was one of the unmet needs identified in Manuscript 1 (chapter 2) and diligences have begun to elaborate Portuguese guidelines for genetic testing in IRDs, a joint project of the Portuguese Society of Ophthalmology and the Portuguese Society of Human Genetics.

### **6.2. The IRD-PT registry**

The IRD-PT registry is probably the single most valuable contribution brought by the IRD-PT study. A national, web-based registry for IRDs is able to empower patients and community organizations, while supporting formal partnerships with investigators and stakeholders in the global aim to develop high-value, high-utility research.<sup>5</sup> By resorting to common data elements, core outcome sets, and standardized data structures, the IRD-PT can support the exchange of data across datasets, facilitating its connection to other registries at an

international level. While Manuscript 3 (Chapter 2) thoroughly describes its design, development and deployment, Manuscript 4 (Chapter 2) provides evidence of its adoption across 4 Ophthalmology Departments in Portugal.

This invaluable resource has been able to boost and excel clinical research in the field of IRDs in our country and has fulfilled its mission to generate important knowledge and collect high-quality longitudinal data on the epidemiology, genomic landscape and natural history of IRDs in Portugal. An example, is a national multicenter study that we co-authored (Annex IV) designed to evaluate the molecular and multimodal imaging findings in Portuguese patients with STGD.<sup>6</sup> Another study aiming to characterize the genetic architecture of syndromic RP in Portugal is currently ongoing and counts with the contribution of several Portuguese Ophthalmology departments.

Nevertheless, the registry still has a lower-than-expected adoption rate and the reasons behind the lack of engagement were dissected, along with avenues for improvement (Manuscript 4, Chapter 2). Keeping the IRD-PT “alive and kicking” is essential given the inestimable benefits a platform like this offers IRD patients. Hopefully, this invaluable resource will continue to boost clinical research in the field of IRDs in our country, while facilitating patient access to clinical trials and new therapies in the years to come.

### **6.3. Disease awareness and medical education**

To expand the number of IRD patients receiving a correct diagnosis and (when possible) treatment, efforts to increase disease awareness and medical education are essential. Over the past few years, the field of Ophthalmic Genetics grew beyond itself. From the first ever approved gene therapy targeting a form of inherited retinal blindness, to a record number of new therapies in the pipeline, and to the spotlight in national and international congresses with delegates overcrowding conference rooms, interest in IRDs is clearly escalating. This interest favors IRD patients and may eventually translate in a higher number of patients referred to IRD expert centers for deep phenotyping, genotyping and treatment.

The explosive rise of social media facilitates knowledge dissemination in different areas, and medicine is no exception. By improving education and awareness through social media, a shift in focus to primary and secondary prevention of several eye diseases may ultimately be accomplished. With roughly 2 billion users,<sup>7</sup> Instagram® is an ideal vehicle to teach an image-rich specialism such as Ophthalmology. Specifically, the visually captivating nature of multimodal imaging features make image-based communication highly effective in IRDs, offering unlimited potential to engage with the target audience.<sup>8</sup> Manuscript 5 (Chapter 2) describes the creation of the Instagram profile @retinaldystrophies, developed to promote disease awareness and

medical education in IRDs.<sup>8</sup> This resource has been featured in research publications<sup>9</sup> and social media courses at a national (64<sup>th</sup> Congress of the Portuguese Society of Ophthalmology) and international level [Ocular Research By Integrated Training And Learning Marie Sklodowska-Curie Innovation Training Network (ORBITAL-ITN) and Ophthalmic Foundation – Ophthalmic Education Consortium]. Even though social media does not replace conventional teaching methods, clinical experience and peer-to-peer knowledge dissemination, it provides a way to rapidly and effectively transmit a message and research has shown its utility as a complement to formal teaching.<sup>7,10</sup>

Boosted by the recent COVID19 pandemic, webinars/online preceptorships became an important learning resource. The Portuguese Society of Ophthalmology partnered with the Portuguese Retina Study Group to launch the “Medical Retina Course”, composed of live and on-demand online teaching sessions extensively covering several topics, including IRDs (module #18). This free platform, especially targeting ophthalmology residents and medical retina fellows, is another way of promoting disease awareness and medical education.

Hopefully, these initiatives will contribute to facilitate the IRD patient journey. Better informed patients will seek specialized care earlier in the disease course, while better informed doctors will know when and where to refer IRD patients to specialized centers, thus minimizing the time to diagnosis and, in some cases, treatment.

#### **6.4. Voretigene Neparvovec: an igniting hope**

Voretigene Neparvovec is more than the first gene therapy targeting a form of inherited retinal blindness. The approval of this innovative therapy fueled interest in other therapies that may soon contribute to the therapeutic armamentarium in IRDs.<sup>11-13</sup> As chronic and visually incapacitating diseases, IRDs pose a significant burden to patients, caregivers, families and the society as a whole. Despite the astronomic price tag, improved light sensitivity, visual field, and navigational ability under dim lighting conditions were reported, with preservation of the clinically meaningful effect for at least 4 years.<sup>14</sup>

Manuscript 6 (Chapter 2) describes what was still an unmet need at the time of publication of Manuscript 1 (Chapter 2), i.e. the landmark treatment of the first Portuguese patient receiving Voretigene Neparvovec.<sup>15</sup> In Manuscript 21 (chapter 4), intraoperative OCT images illustrate the bleb formation with the subretinal administration of Voretigene Neparvovec in this first patient.<sup>16</sup> One year after, 10 patients (20 eyes) have been treated in our country, demonstrating the tremendous compromise that the Portuguese National Health System has with IRD patients. In times where reports on the inefficiency of our public health system cover the daily news, it is important to acknowledge that reimbursement of Voretigene Neparvovec

still is not available in many countries around the world, creating important patient inequalities in access to this groundbreaking therapy. The EVICR.net *RPE65* Survey that we co-authored (Annex II) highlights the heterogeneities in diagnosis and management practices of *RPE65* mutation-associated retinal degeneration across Europe.<sup>17</sup> Even though cross-border treatment is currently a reality in Europe, several patients are still waiting to be treated.

In a research project developed in collaboration with the Coimbra Institute for Biomedical Imaging and Translational Research (CIBIT) and the Institute for Nuclear Sciences Applied to Health (ICNAS), we are performing baseline and postoperative (6-12 months) functional magnetic resonance imaging (fMRI) to evaluate cortical function changes following retinal gene therapy with Voretigene Neparvovec. We are truly excited with this project and hope to demonstrate improvement in visual cortex activation following treatment. Another research topic that holds promise in this particular group of patients is the application of MRDQ and MVAQ at baseline and 1 year after treatment. We hope to document improvement in these two PRO measures, specifically developed and validated for use in IRDs (Chapter 4). Most importantly, we hope to continue to be able to use Voretigene Neparvovec in newly diagnosed patients with *RPE65*-associated retinal degeneration and be able to offer our IRD patients access to other IRD therapies currently being investigated in clinical trials, either in Portugal or abroad.

## **6.5. Extending the mutational and phenotypical spectrum of Retinitis Pigmentosa**

RP is the single most prevalent IRD, affecting ~1:4000 individuals worldwide.<sup>18</sup> The condition is both clinically and genetically heterogeneous. Thus far, clinically significant variants in more than 80 genes have been implicated in nonsyndromic RP.<sup>18</sup> Genetic overlap exists with other IRDs (e.g. *ABCA4*, *BEST1* and *PRPH2* may cause RP, cone-rod disease or a macular dystrophy) and even with syndromic RP (e.g. apart from nonsyndromic RP, *USH2A* and *BBS2* are associated with Usher syndrome type 2A and Bardet-Biedl syndrome, respectively), which accounts for 20-30% of all RP cases.<sup>19,20</sup> In the “classic” presentation of RP, difficulty with dark adaptation begins in adolescence, and visual loss in the mid-peripheral field becomes apparent in young adulthood. However, the age of onset varies widely and some RP patients may have central involvement (due to macular atrophy) soon in the disease course (e.g. *PROM1* and *RPGR*-associated RP). Three clinical features – bone spicule pigmentation, attenuation of retinal vessels, and a waxy pallor of the optic nerve – are the hallmark signs of RP. However, not all RP patients develop typical bone spicule pigmentation and there is inter- and intrafamilial heterogeneity in the clinical presentation.<sup>18</sup> Additionally, atypical phenotypes have been described, including sector RP,<sup>21-24</sup> clumped pigmented retinal degeneration,<sup>18</sup> unilateral and asymmetric cases.<sup>25-27</sup> An interesting atypical RP phenotype that until recently was deemed pathognomonic of *NR2E3*-

p.G56R-linked AD RP is the presentation of a double concentric hyperautofluorescent ring on FAF imaging.<sup>28</sup> As many other genotype-phenotype correlations in IRDs, this one did not stand. Manuscript 19 (Chapter 5) illustrates this same phenotype in a case of *EYS*-associated RP, highlighting that FAF alone does not seem to be a reliable method of distinguishing between RP genotypes.<sup>29</sup>

By thoroughly analyzing solved and unsolved non-syndromic retinitis pigmentosa (RP) cases, manuscript 7 (Chapter 3) provides evidence that individual clinical/demographic, functional testing and multimodal imaging features should be considered when counselling patients about the probability of identifying disease-causing variants.<sup>30</sup> Unlike Birtel et al,<sup>31</sup> we did not find evidence pointing to a higher unsolved rate in atypical phenotypes. Atypical findings in at least one imaging modality were present in similar frequency between genetically solved and unsolved cases, thus emphasizing the phenotypic heterogeneity that characterizes nsRP.

The sector RP phenotype is a rare, atypical and milder form of rod-cone degeneration in which only one or two quadrants of the retina are involved.<sup>32,33</sup> Historically, this phenotype was almost pathognomonic of the rhodopsin gene (*RHO*, 3q22.1, MIM \*180380).<sup>23,34</sup> In fact, our group published a great example of *RHO*-associated sector RP (Manuscript 20, chapter 4).<sup>23</sup> However, the mutational spectrum of sector RP is evolving, with recent additions to the list of associated genes.<sup>22,35</sup> One of these genes is *EYS* (6q12, MIM \*612424), a frequent cause of autosomal-recessive retinal degeneration in Asian and European populations,<sup>36-39</sup> and the single most prevalent IRD-associated gene in our country, according to data from the IRD-PT. In Manuscript 8 (chapter 3), we used multimodal imaging and visual field testing to deeply characterize phenotypic features in a multicentric cohort of *EYS*-associated sector RP and identified four novel *EYS* variants that were reported for the first time: 1 pathogenic, 1 likely pathogenic and 2 variants of uncertain significance (VUS) according to the ACMG classification.<sup>24</sup> In the case of the latter 2 variants, family studies allowed reclassification of the variants as likely pathogenic. This study was important to consolidate the role of *EYS* as a frequent gene associated with the sector RP phenotype. In fact, in a later publication from our group (Annex V), we have shown that *EYS* was the most frequently implicated gene in sector RP in our population, harboring disease-causing variants in 4 families (4 individuals). *RHO* in 2 families (4 individuals), and finally nephrocystin 1 (*NPH1*, 2q13, MIM \*607100) and myosin VIIA (*MYO7A*, 11q13.5 MIM \*276903) affecting one family/individual each were the other genes associated with the sector RP phenotype in our cohort.<sup>21</sup>

In Portugal, *EYS* is responsible for ~28% of arRP cases and accounts for 9% of all IRD cases in the IRD-PT registry, making it the most commonly mutated IRD gene in our country. Manuscript 9 (chapter 3) describes the natural history, genetic landscape and phenotypic spectrum of *EYS*-associated retinal degeneration (*EYS*-RD) in a large Portuguese cohort (58

patients). Among 20 distinct identified *EYS* variants, we reported 8 novel mutations in this gene for the first time, thus expanding its the mutational spectrum. Additionally, we were able to separate typical (75%) from atypical (25%) *EYS*-RD phenotypes by means of multimodal retinal imaging, underlining the phenotypical heterogeneity that exists in *EYS*-RD. Interestingly, patients with atypical forms showed significantly better BCVA and significantly larger EZ widths on SD-OCT than patients with a typical RP phenotype. As others have suggested, we believe that modifier genes, gene modulators, or additional environmental factors may be responsible for the heterogeneity observed in *EYS*-RD, which warrants further investigation. We are currently about to start a natural history study in *EYS*-RD hoping to further understand disease mechanisms. The project received an investigation grant from Abbvie® and the Portuguese Retina Study Group and we are currently awaiting approval from the Ethics Committee to start enrolling patients.

Clinically significant variants in Retinitis Pigmentosa GTPase Regulator (*RPGR*) gene account for 70-80% of XL RP.<sup>40,41</sup> Furthermore, according to the GRID dataset, *RPGR* is one of the top 5 most frequently implicated IRD genes worldwide.<sup>13</sup> To date, more than 600 variants in the *RPGR* gene have been described.<sup>42</sup> Manuscript 10 (Chapter 3) adds to the current knowledge of *RPGR*-associated retinal degeneration by reporting 3 novel clinically significant variants in this gene: 2 likely pathogenic frameshift variants in the ORF15 region and 1 pathogenic variant located in exon 11. Additionally, we described a high number of females presenting with a male-type phenotype, thus showing that this presentation is not infrequent and alerting for the need to test for XL RP even in the presence of affected females (this should include the ORF15 region as a hotspot in *RPGR*-associated retinal degeneration). Finally, we described for the first time that females with an advanced phenotype present increased peripapillary retinal nerve fiber layer (pRNFL) thickness, especially in the temporal sector, thus mimicking what has been reported by Birtel et al<sup>43</sup> in male patients with *RPGR*-associated XL RP. Neuronal-glial remodeling associated with outer retinal atrophy or altered metabolic signaling, blood vessel architecture of the inner retina, or yet unknown factors have been proposed as explanations for the increased pRNFL thickness in RP.<sup>43-46</sup> Even though we were not able to elucidate why this happens beyond a reasonable doubt and rely mostly on these speculative mechanisms to attempt an explanation, our findings may have implications for ongoing and future trials.

Cystoid macular edema (CME) and vitreomacular interface disorders (VMID) frequently complicate both syndromic and nonsyndromic RP.<sup>18,47</sup> Screening for these potentially treatable central vision-threatening conditions may improve the QoL of RP patients. There is no clear explanation for the development of CME in RP. The role of low-grade inflammation caused by antiretinal antibodies, the release of toxic by-products by dying retinal cells, the remodeling of the neurovascular unit involving Müller cell dysfunction and blood-retinal barrier breakdown, or the decrease in retinoschisin levels secondary to photoreceptor loss have all been suggested as

possible causes of cystoid fluid accumulation in RP.<sup>48-51</sup> Irrespective of its pathogenesis, it is interesting to note that cystoid spaces are usually located in macular areas where the outer retina is rather well preserved and the EZ can be identified.<sup>48,49</sup> In manuscript 11 (Chapter 3) we evaluated patients with genetically solved syndromic (n=88) and nonsyndromic RP (n=37). We found that no significant differences exist in the frequency of CME and VMID between genetically solved syndromic and non-syndromic RP, and that the burden of epiretinal membrane (~50%) and CME (~17%) is high in both groups.<sup>52</sup> Most epiretinal membranes in our cohort were graded as stage I of the Govetto SD-OCT classification,<sup>53</sup> i.e. without loss of the normal foveal contour; thus, without surgical indication. This probably explains why there was not a statistically significant association between the presence of ERM and lower BCVA. Regarding CME, since its pathogenesis in RP is not well understood, the optimal treatment remains controversial. However, several studies have shown CME improvement after treatment with carbonic anhydrase inhibitors (CAIs), and these remain the gold standard treatment for cystoid maculopathy in RP.<sup>54,55</sup>

## **6.6. Deep phenotyping: the more detailed, the better**

Advancements in multimodal retinal imaging have transformed the practice of ophthalmic genetics, shedding light on disease mechanisms, allowing early disease detection (thus shortening the IRD patient diagnostic odyssey), directing genetic testing, facilitating more accurate advice on prognosis, allowing sensitive measurements of change over time and contributing to treatment development and outcome validation.<sup>56</sup> Complementary information results from the combination of multimodal retinal imaging and functional evaluation, allowing full characterization of the patient's phenotype. Given the specificities and precision of most IRD-related investigational products, accurate descriptions of the natural history of IRD genotypes by means of deep phenotyping is necessary to define who to treat and when.

As described above, deep phenotyping was a key component of Manuscripts 7, 8, 9, 10 and 11 (Chapter 3). On manuscript 12 (Chapter 3), multimodal retinal imaging was used to characterize the retinal phenotype of a large Portuguese cohort of Pseudoxanthoma elasticum (PXE; MIM #264800; ORPHA #758). Using OCT angiography, we reported for the first time the prevalence and natural history of non-exudative macular neovascularization (MNV) in this *ABCC6*-associated disease.<sup>57</sup> We found that non-exudative MNV is a frequent finding in PXE, even though the majority of eyes did not develop exudation during follow-up. Aside from conventional structural imaging, our findings established the utility of OCT angiography in the management of PXE.

Manuscripts 15, 16, 17, 18, 19, 20 and 21 (Chapter 5) are other great examples of the utility of deep phenotyping in IRDs. While Manuscripts 15, 16, 17, 18, 19 and 20 illustrate uncommon phenotypes by means of multimodal imaging,<sup>23,29,58-61</sup> Manuscript 21 depicts the utility of intraoperative OCT in the subretinal administration of gene therapy.<sup>16</sup>

### **6.7. Patient-reported outcomes: measuring results that matter**

When an IRD patient undergoes an eye assessment, the measures used are purely technical (e.g. visual acuity, visual field, OCT) and do not routinely address the patient's experience.<sup>62-64</sup> These clinician-reported outcomes do not really reflect how patients' vision affects their daily lives. Because of (very) low visual function due to limited retinal photoreceptor cell function and/or low numbers of remaining cells from the outset, what can ultimately be achieved with innovative treatments is often limited when assessed by conventional outcome measures (e.g. BCVA). Consequently, improvements that represent significant and meaningful gains for IRD patients may not attain what have been traditionally considered thresholds often applied to other, more common ocular diseases, such as age-related macular degeneration, glaucoma or diabetic retinopathy. Indeed, it is unrealistic to compare outcomes initially derived from common ophthalmic diseases to IRDs.

The increasing need to assess meaningful health outcomes in IRD patients prompted the development of two IRD-specific PRO measures: MRDQ and MVAQ.<sup>65,66</sup> In an effort to use these important measures of self-perceived visual function in Portuguese-speaking IRD patients, Manuscript 13 (Chapter 4) describes the Portuguese translation and linguistic validation of both questionnaires.<sup>67</sup> All the process was conducted following the recommendations of the *International Society for Pharmacoeconomics and Outcomes Research* (ISPOR) task force for linguistic and cultural validation of PROs and *PRO Consortium* consensus of updated best practices.<sup>68,69</sup> The Portuguese versions of MRDQ and MVAQ are semantically, conceptually and operationally equivalent to the original English versions, and are now ready to be integrated in clinical practice or clinical trials involving Portuguese-speaking IRD patients.<sup>67</sup> An example of the applicability of these questionnaires is shown in Manuscript 14 (Chapter 4), where both PRO measures were used in combination with structural and functional data to deeply characterize EYS-RD. Additionally, we believe these important measures of self-perceived visual function will help identify treatment efficacy. We are currently conducting a study in RPE65 patients undergoing gene therapy with Voretigene Neparvovec where both PRO measures are used at baseline and then yearly after treatment.



## 6.8. Final Remarks

The IRD-PT study generated more than 20 publications in peer reviewed journals and established an important foundation for the growth of IRD-related research in Portugal. By identifying pivotal unmet medical needs, we focused on solutions to address and overcome those needs. An invaluable contribution to the field was the development of a national, web-based IRD patient registry that is currently being used by 4 different healthcare providers in the country and has more than 1000 IRD patients enrolled. The translation of two IRD-specific PRO measures allows the application of these questionnaires to Portuguese-speaking patients across the globe, in an effort to better understand IRD patients' needs and provide a more holistic form of patient care. These efforts fostered national and international collaborations that will boost knowledge generation and develop high-quality clinical research in the field.

The IRD-PT study also provided novel insights into the genetic architecture and phenotypic spectrum of IRDs in Portugal. We described previously unreported variants in two of the most frequently implicated genes in IRDs: *EYS* (12 novel variants) and *RPGR* (3 novel variants). We have also thoroughly described distinctive IRD phenotypes by means of multimodal retinal imaging, contributing to a better understanding of the retinal changes observed across different genotypes.

In conclusion, IRD patient management warrants an integrative approach combining deep phenotyping, genotyping, lifestyle interventions and psychosocial support. We believe the IRD-PT study established an important foundation and opened several doors to make the Portuguese ophthalmic genetics field flourish over the years to come. By partnering with national and international research teams, we grew a network of connections that share a common compromise: to give a voice to IRD patients and provide them with all the available tools to live their lives to the maximum, irrespective of their disability.

## REFERENCES

1. Claussnitzer M, Cho JH, Collins R, et al. A brief history of human disease genetics. *Nature* 2020;577(7789):179-189. DOI: 10.1038/s41586-019-1879-7.
2. Lenassi E, Clayton-Smith J, Douzougou S, et al. Clinical utility of genetic testing in 201 preschool children with inherited eye disorders. *Genet Med* 2020;22(4):745-751. DOI: 10.1038/s41436-019-0722-8.

3. Black GC, Sergouniotis P, Sodi A, et al. The need for widely available genomic testing in rare eye diseases: an ERN-EYE position statement. *Orphanet J Rare Dis* 2021;16(1):142. DOI: 10.1186/s13023-021-01756-x.
4. Lorenz B, Tavares J, van den Born LI, Marques JP, Scholl HPN, Group EVn. Current Management of Inherited Retinal Degeneration Patients in Europe: Results of a Multinational Survey by the European Vision Institute Clinical Research Network. *Ophthalmic Res* 2021;64(4):622-638. DOI: 10.1159/000514540.
5. Marques JP, Carvalho AL, Henriques J, Murta JN, Saraiva J, Silva R. Design, development and deployment of a web-based interoperable registry for inherited retinal dystrophies in Portugal: the IRD-PT. *Orphanet J Rare Dis* 2020;15(1):304. DOI: 10.1186/s13023-020-01591-6.
6. Geada S, Santos C, Vaz-Pereira S, et al. Molecular and Multimodal Retinal Imaging Findings in a Multicentric Portuguese Cohort of Stargardt Disease. *Revista Sociedade Portuguesa de Oftalmologia* 2022;46(1):15-24. DOI: 10.48560/rspo.25968.
7. Nguyen AAK, Tsui E, Smith JR. Social media and ophthalmology: A review. *Clin Exp Ophthalmol* 2022;50(4):449-458. DOI: 10.1111/ceo.14091.
8. Marques JP. Instagram as a vehicle to promote disease awareness and medical education in #retinaldystrophies. *Postgrad Med J* 2022;98(e3):e167. DOI: 10.1136/postgradmedj-2021-140041.
9. Leitao Guerra RL. A perspective on retina education through social media. *Int J Retina Vitreous* 2020;6:44. DOI: 10.1186/s40942-020-00244-x.
10. Tsui E, Rao RC. Navigating Social Media in #Ophthalmology. *Ophthalmology* 2019;126(6):779-782. DOI: 10.1016/j.ophtha.2019.02.015.
11. Botto C, Rucli M, Tekinsoy MD, Pulman J, Sahel JA, Dalkara D. Early and late stage gene therapy interventions for inherited retinal degenerations. *Prog Retin Eye Res* 2022;86:100975. DOI: 10.1016/j.preteyeres.2021.100975.
12. Fenner BJ, Tan TE, Barathi AV, et al. Gene-Based Therapeutics for Inherited Retinal Diseases. *Front Genet* 2021;12:794805. DOI: 10.3389/fgene.2021.794805.
13. Schneider N, Sundaresan Y, Gopalakrishnan P, et al. Inherited retinal diseases: Linking genes, disease-causing variants, and relevant therapeutic modalities. *Prog Retin Eye Res* 2022;89:101029. DOI: 10.1016/j.preteyeres.2021.101029.
14. Maguire AM, Russell S, Wellman JA, et al. Efficacy, Safety, and Durability of Voretigene Neparvovec-rzyl in RPE65 Mutation-Associated Inherited Retinal Dystrophy: Results of Phase 1 and 3 Trials. *Ophthalmology* 2019;126(9):1273-1285. DOI: 10.1016/j.ophtha.2019.06.017.

15. Marques JP, Raimundo M, Paiva C, et al. Treating the first Portuguese patient with Luxturna: A small step for world science, a giant leap for Portuguese Ophthalmology. *Revista Sociedade Portuguesa de Oftalmologia* 2021;45(2):67-69. DOI: 10.48560/rspo.24654.
16. Marques JP, Alfaiate M, Figueira JP. Subretinal Bleb of Voretigene Neparvovec. *Asia Pac J Ophthalmol (Phila)* 2022;11(2):211. DOI: 10.1097/APO.0000000000000431.
17. Lorenz B, Tavares J, van den Born LI, Marques JP, Scholl HPN, Group EVn. Current Management of Patients with RPE65 Mutation-Associated Inherited Retinal Degenerations in Europe: Results of a Multinational Survey by the European Vision Institute Clinical Research Network. *Ophthalmic Res* 2021;64(5):740-753. DOI: 10.1159/000515688.
18. Verbakel SK, van Huet RAC, Boon CJF, et al. Non-syndromic retinitis pigmentosa. *Prog Retin Eye Res* 2018;66:157-186. DOI: 10.1016/j.preteyeres.2018.03.005.
19. Sanchez-Bellver L, Toulis V, Marfany G. On the Wrong Track: Alterations of Ciliary Transport in Inherited Retinal Dystrophies. *Front Cell Dev Biol* 2021;9:623734. DOI: 10.3389/fcell.2021.623734.
20. Tatour Y, Ben-Yosef T. Syndromic Inherited Retinal Diseases: Genetic, Clinical and Diagnostic Aspects. *Diagnostics (Basel)* 2020;10(10). DOI: 10.3390/diagnostics10100779.
21. Cortinhal T, Geada S, Neves E, et al. Genomic Landscape and Natural History of Sector Retinitis Pigmentosa. *Revista Sociedade Portuguesa de Oftalmologia* 2022;46(1):25-32. DOI: 10.48560/rspo.25958.
22. Georgiou M, Grewal PS, Narayan A, et al. Sector Retinitis Pigmentosa: Extending the Molecular Genetics Basis and Elucidating the Natural History. *Am J Ophthalmol* 2021;221:299-310. DOI: 10.1016/j.ajo.2020.08.004.
23. Oliveira MA, Neves E, Marques JP. Genetic, Anatomical, and Functional Correlation of Sector Retinitis Pigmentosa. *JAMA Ophthalmol* 2020;138(6):e193133. DOI: 10.1001/jamaophthalmol.2019.3133.
24. Marques JP, Porto FBO, Carvalho AL, et al. EYS-Associated Sector Retinitis Pigmentosa. *Graefes Arch Clin Exp Ophthalmol* 2022;260(4):1405-1413. DOI: 10.1007/s00417-021-05411-w.
25. Sujirakul T, Davis R, Erol D, et al. Bilateral Concordance of the Fundus Hyperautofluorescent Ring in Typical Retinitis Pigmentosa Patients. *Ophthalmic Genet* 2015;36(2):113-22. DOI: 10.3109/13816810.2013.841962.
26. Farrell DF. Unilateral retinitis pigmentosa and cone-rod dystrophy. *Clin Ophthalmol* 2009;3:263-70. DOI: 10.2147/ophth.s5130.

27. Jauregui R, Chan L, Oh JK, Cho A, Sparrow JR, Tsang SH. Disease asymmetry and hyperautofluorescent ring shape in retinitis pigmentosa patients. *Sci Rep* 2020;10(1):3364. DOI: 10.1038/s41598-020-60137-9.
28. Escher P, Tran HV, Vaclavik V, Borruat FX, Schorderet DF, Munier FL. Double concentric autofluorescence ring in NR2E3-p.G56R-linked autosomal dominant retinitis pigmentosa. *Invest Ophthalmol Vis Sci* 2012;53(8):4754-64. DOI: 10.1167/iovs.11-8693.
29. Marques JP, Simao J. Double Concentric Hyperautofluorescent Ring in EYS-Associated Retinitis Pigmentosa. *Asia Pac J Ophthalmol (Phila)* 2022. DOI: 10.1097/APO.0000000000000473.
30. Marques JP, Marta A, Geada S, et al. Clinical/Demographic Functional Testing and Multimodal Imaging Differences between Genetically Solved and Unsolved Retinitis Pigmentosa. *Ophthalmologica* 2022;245(2):134-143. DOI: 10.1159/000520305.
31. Birtel J, Gliem M, Oishi A, et al. Genetic testing in patients with retinitis pigmentosa: Features of unsolved cases. *Clin Exp Ophthalmol* 2019;47(6):779-786. DOI: 10.1111/ceo.13516.
32. Massof RW, Finkelstein D. Vision threshold profiles in sector retinitis pigmentosa. *Arch Ophthalmol* 1979;97(10):1899-904. DOI: 10.1001/archopht.1979.01020020347012.
33. Van Woerkom C, Ferrucci S. Sector retinitis pigmentosa. *Optometry* 2005;76(5):309-17. DOI: 10.1016/s1529-1839(05)70314-6.
34. Xiao T, Xu K, Zhang X, Xie Y, Li Y. Sector Retinitis Pigmentosa caused by mutations of the RHO gene. *Eye (Lond)* 2019;33(4):592-599. DOI: 10.1038/s41433-018-0264-3.
35. Coussa RG, Basali D, Maeda A, DeBenedictis M, Traboulsi EI. Sector retinitis pigmentosa: Report of ten cases and a review of the literature. *Mol Vis* 2019;25:869-889.
36. Arai Y, Maeda A, Hirami Y, et al. Retinitis Pigmentosa with EYS Mutations Is the Most Prevalent Inherited Retinal Dystrophy in Japanese Populations. *J Ophthalmol* 2015;2015:819760. DOI: 10.1155/2015/819760.
37. Audo I, Sahel JA, Mohand-Said S, et al. EYS is a major gene for rod-cone dystrophies in France. *Hum Mutat* 2010;31(5):E1406-35. DOI: 10.1002/humu.21249.
38. Barragan I, Borrego S, Pieras JI, et al. Mutation spectrum of EYS in Spanish patients with autosomal recessive retinitis pigmentosa. *Hum Mutat* 2010;31(11):E1772-800. DOI: 10.1002/humu.21334.
39. Yang L, Fujinami K, Ueno S, et al. Genetic Spectrum of EYS-associated Retinal Disease in a Large Japanese Cohort: Identification of Disease-associated Variants with Relatively High Allele Frequency. *Sci Rep* 2020;10(1):5497. DOI: 10.1038/s41598-020-62119-3.

40. Nanda A, Salvetti AP, Clouston P, Downes SM, MacLaren RE. Exploring the Variable Phenotypes of RPGR Carrier Females in Assessing their Potential for Retinal Gene Therapy. *Genes (Basel)* 2018;9(12). DOI: 10.3390/genes9120643.
41. De Silva SR, Arno G, Robson AG, et al. The X-linked retinopathies: Physiological insights, pathogenic mechanisms, phenotypic features and novel therapies. *Prog Retin Eye Res* 2021;82:100898. DOI: 10.1016/j.preteyeres.2020.100898.
42. Yang J, Zhou L, Ouyang J, et al. Genotype-Phenotype Analysis of RPGR Variations: Reporting of 62 Chinese Families and a Literature Review. *Front Genet* 2021;12:600210. DOI: 10.3389/fgene.2021.600210.
43. Birtel TH, Birtel J, Hess K, et al. Analysis of imaging biomarkers and retinal nerve fiber layer thickness in RPGR-associated retinitis pigmentosa. *Graefes Arch Clin Exp Ophthalmol* 2021;259(12):3597-3604. DOI: 10.1007/s00417-021-05233-w.
44. Vecino E, Rodriguez FD, Ruzafa N, Pereiro X, Sharma SC. Glia-neuron interactions in the mammalian retina. *Prog Retin Eye Res* 2016;51:1-40. DOI: 10.1016/j.preteyeres.2015.06.003.
45. Rattner A, Nathans J. The genomic response to retinal disease and injury: evidence for endothelin signaling from photoreceptors to glia. *J Neurosci* 2005;25(18):4540-9. DOI: 10.1523/JNEUROSCI.0492-05.2005.
46. Aleman TS, Cideciyan AV, Sumaroka A, et al. Inner retinal abnormalities in X-linked retinitis pigmentosa with RPGR mutations. *Invest Ophthalmol Vis Sci* 2007;48(10):4759-65. DOI: 10.1167/iovs.07-0453.
47. Liew G, Strong S, Bradley P, et al. Prevalence of cystoid macular oedema, epiretinal membrane and cataract in retinitis pigmentosa. *Br J Ophthalmol* 2019;103(8):1163-1166. DOI: 10.1136/bjophthalmol-2018-311964.
48. Strong S, Liew G, Michaelides M. Retinitis pigmentosa-associated cystoid macular oedema: pathogenesis and avenues of intervention. *Br J Ophthalmol* 2017;101(1):31-37. DOI: 10.1136/bjophthalmol-2016-309376.
49. Gaudric A, Audo I, Vignal C, et al. Non-vasogenic cystoid maculopathies. *Prog Retin Eye Res* 2022:101092. DOI: 10.1016/j.preteyeres.2022.101092.
50. Pfeiffer RL, Marc RE, Kondo M, Terasaki H, Jones BW. Muller cell metabolic chaos during retinal degeneration. *Exp Eye Res* 2016;150:62-70. DOI: 10.1016/j.exer.2016.04.022.
51. Ivanova E, Alam NM, Prusky GT, Sagdullaev BT. Blood-retina barrier failure and vision loss in neuron-specific degeneration. *JCI Insight* 2019;5. DOI: 10.1172/jci.insight.126747.
52. Marques JP, Neves E, Geada S, et al. Frequency of cystoid macular edema and vitreomacular interface disorders in genetically solved syndromic and non-syndromic

- retinitis pigmentosa. *Graefes Arch Clin Exp Ophthalmol* 2022. DOI: 10.1007/s00417-022-05649-y.
53. Govetto A, Lalane RA, 3rd, Sarraf D, Figueroa MS, Hubschman JP. Insights Into Epiretinal Membranes: Presence of Ectopic Inner Foveal Layers and a New Optical Coherence Tomography Staging Scheme. *Am J Ophthalmol* 2017;175:99-113. DOI: 10.1016/j.ajo.2016.12.006.
  54. Huang Q, Chen R, Lin X, Xiang Z. Efficacy of carbonic anhydrase inhibitors in management of cystoid macular edema in retinitis pigmentosa: A meta-analysis. *PLoS One* 2017;12(10):e0186180. DOI: 10.1371/journal.pone.0186180.
  55. Liew G, Moore AT, Webster AR, Michaelides M. Efficacy and prognostic factors of response to carbonic anhydrase inhibitors in management of cystoid macular edema in retinitis pigmentosa. *Invest Ophthalmol Vis Sci* 2015;56(3):1531-6. DOI: 10.1167/iovs.14-15995.
  56. Daich Varela M, Esener B, Hashem SA, Cabral de Guimaraes TA, Georgiou M, Michaelides M. Structural evaluation in inherited retinal diseases. *Br J Ophthalmol* 2021;105(12):1623-1631. DOI: 10.1136/bjophthalmol-2021-319228.
  57. Marques JP, Bernardes J, Geada S, et al. Non-exudative macular neovascularization in pseudoxanthoma elasticum. *Graefes Arch Clin Exp Ophthalmol* 2021;259(4):873-882. DOI: 10.1007/s00417-020-04979-z.
  58. Marques JP. MFRP-Related Nanophthalmos-Retinitis Pigmentosa-Foveoschisis-Optic Disc Drusen Syndrome. *Ophthalmic Surg Lasers Imaging Retina* 2021;52(2):110. DOI: 10.3928/23258160-20210201-09.
  59. Marques JP, Chaves J. SLC24A1-Associated Congenital Stationary Night Blindness in a Woman With an Abnormal Fundus. *JAMA Ophthalmol* 2022;140(4):e216343. DOI: 10.1001/jamaophthalmol.2021.6343.
  60. Marques JP, Geada S. Multimodal Imaging in Hypotrichosis with Juvenile Macular Degeneration. *Ophthalmol Retina* 2021;5(6):593. DOI: 10.1016/j.oret.2021.02.014.
  61. Marques JP, Pereira P. Gyrate atrophy of the choroid and retina. *Postgrad Med J* 2022;98(1158):308. DOI: 10.1136/postgradmedj-2021-139807.
  62. Selvan K, Abalem MF, Lacy GD, Vincent A, Heon E. The State of Patient-Reported Outcome Measures for Pediatric Patients with Inherited Retinal Disease. *Ophthalmol Ther* 2022;11(3):1031-1046. DOI: 10.1007/s40123-022-00514-x.
  63. Jayasundera KT, Abuzaitoun RO, Lacy GD, et al. Challenges of Cost-Effectiveness Analyses of Novel Therapeutics for Inherited Retinal Diseases. *Am J Ophthalmol* 2022;235:90-97. DOI: 10.1016/j.ajo.2021.08.009.

64. Lacy GD, Abalem MF, Musch DC, Jayasundera KT. Patient-reported outcome measures in inherited retinal degeneration gene therapy trials. *Ophthalmic Genet* 2020;41(1):1-6. DOI: 10.1080/13816810.2020.1731836.
65. Lacy GD, Abalem MF, Andrews CA, et al. The Michigan Vision-Related Anxiety Questionnaire: A Psychosocial Outcomes Measure for Inherited Retinal Degenerations. *Am J Ophthalmol* 2021;225:137-146. DOI: 10.1016/j.ajo.2020.12.001.
66. Lacy GD, Abalem MF, Andrews CA, et al. The Michigan Retinal Degeneration Questionnaire: A Patient-Reported Outcome Instrument for Inherited Retinal Degenerations. *Am J Ophthalmol* 2021;222:60-68. DOI: 10.1016/j.ajo.2020.08.032.
67. Marques JP, Bernardes L, Oliveira C, et al. Portuguese translation and linguistic validation of the Michigan Retinal Degeneration Questionnaire and the Michigan Vision-Related Anxiety Questionnaire in a cohort with inherited retinal degenerations. *Ophthalmic Genet* 2022;43(1):137-139. DOI: 10.1080/13816810.2022.2025609.
68. Wild D, Grove A, Martin M, et al. Principles of Good Practice for the Translation and Cultural Adaptation Process for Patient-Reported Outcomes (PRO) Measures: report of the ISPOR Task Force for Translation and Cultural Adaptation. *Value Health* 2005;8(2):94-104. DOI: 10.1111/j.1524-4733.2005.04054.x.
69. Eremenco S, Pease S, Mann S, Berry P, Subcommittee PROCsP. Patient-Reported Outcome (PRO) Consortium translation process: consensus development of updated best practices. *J Patient Rep Outcomes* 2017;2(1):12. DOI: 10.1186/s41687-018-0037-6.





## **CHAPTER 7: LIST OF PUBLICATIONS**



**Inherited Retinal Degenerations in Portugal: Addressing the unmet needs**

Marques JP, Pires J, Costa J, Murta J, Silva R.

*Acta Med Port.* 2021 May 2;34(5):332-334.

**The need for widely available genomic testing in rare eye diseases: an ERN-EYE position statement**

Black GC, Sergouniotis P, Sodi A, Leroy BP, Van Cowenberg C, Liskova P, Grønskov K, Klett A, Kohl S, Taurina G, Sukys M, Haer-Wigman L, Nowomiejska K, Marques JP, Leroux D, Cremers FPM, De Baere E, Dollfus H, ERN-EYE study group

*Orphanet J Rare Dis.* 2020 Oct 27;15(1):304.

**Design, development and deployment of a web-based interoperable registry for inherited retinal dystrophies in Portugal: the IRD-PT**

Marques JP, Carvalho AL, Henriques J, Murta JN, Saraiva J, Silva R

*Orphanet J Rare Dis.* 2020 Oct 27;15(1):304.

**Challenges, facilitators and barriers to the adoption and use of a web-based national IRD registry: lessons learned from the IRD-PT registry**

Marques JP, Vaz-Pereira S, Costa J, Marta A, Henriques J, Silva R

*Orphanet J Rare Dis.* 2022 Aug 26;17(1):323.

**Instagram as a vehicle to promote disease awareness and medical education in #retinaldystrophies**

Marques JP

*Postgrad Med J.* 2022 May;98(e3):e167.

**Treating the first Portuguese patient with Luxturna: A small step for world science, a giant leap for Portuguese Ophthalmology**

Marques JP, Raimundo M, Paiva C, Figueira J, Alfaiate M, Silva R, Murta J

*Revista Sociedade Portuguesa de Oftalmologia.* 2021;45(2):67-69.

**Clinical/demographic, functional testing and multimodal imaging differences between genetically solved and unsolved Retinitis Pigmentosa**

Marques JP, Marta A, Carvalho AL, Menéres P, Murta J, Saraiva J, Silva R

*Ophthalmologica.* 2022;245(2):134-143.

**EYS-Associated Sector Retinitis Pigmentosa**

Marques JP, Porto FBO, Carvalho AL, Neves E, Chen R, Sampaio SAM, Murta J, Saraiva J, Silva R  
*Graefes Arch Clin Exp Ophthalmol.* 2022 Apr;260(4):1405-1413.

**Genetic spectrum, retinal phenotype and peripapillary RNFL thickness in RPGR heterozygotes**

Marques JP, Pinheiro R, Carvalho AL, Raimundo M, Soares M, Melo P, Murta J, Saraiva J, Silva R  
*Graefes Arch Clin Exp Ophthalmol.* 2022 Sep 2. Online ahead of print.

**Frequency of cystoid macular edema and vitreomacular interface disorders in genetically solved syndromic and non-syndromic Retinitis Pigmentosa**

Marques JP, Neves E, Geada S, Carvalho AL, Murta J, Saraiva J, Silva R  
*Graefes Arch Clin Exp Ophthalmol.* 2022 Sep;260(9):2859-2866.

**Non-exudative macular neovascularization in pseudoxanthoma elasticum**

Marques JP, Bernardes J, Geada S, Soares M, Teixeira D, Farinha C, Pires I, Cachulo ML, Silva R  
*Graefes Arch Clin Exp Ophthalmol.* 2021 Apr;259(4):873-882.

**Portuguese translation and linguistic validation of the Michigan Retinal Degeneration Questionnaire and the Michigan Vision-Related Anxiety Questionnaire in a cohort with Inherited Retinal Degenerations**

Marques JP, Bernardes L, Oliveira C, Fonseca G, Gil JQ, Sotero L, Relvas AP, Murta J, Silva R, Lacy GB, Abalem MF, Jayasundera KT  
*Ophthalmic Genet.* 2022 Feb;43(1):137-139.

**MFRP-Related Nanophthalmos-Retinitis Pigmentosa-Foveoschisis-Optic Disc Drusen Syndrome**

Marques JP  
*Ophthalmic Surg Lasers Imaging Retina.* 2021 Feb 1;52(2):110.

**SLC24A1-Associated Congenital Stationary Night Blindness in a woman with an abnormal fundus**

Marques JP, Chaves J  
*JAMA Ophthalmol.* 2022 Apr 1;140(4):e216343.

### **Multimodal Imaging in Hypotrichosis with Juvenile Macular Degeneration**

Marques JP, Geada S

*Ophthalmol Retina*. 2021 Jun;5(6):593.

### **Gyrate atrophy of the choroid and retina**

Marques JP, Pereira P

*Postgrad Med J*. 2022 Apr;98(1158):308.

### **Double concentric hyperautofluorescent ring in EYS-Associated Retinitis Pigmentosa**

Marques JP, Simão J

*Asia Pac J Ophthalmol (Phila)*. 2022 Feb 7. Online ahead of print.

### **Genetic, Anatomical, and Functional Correlation of Sector Retinitis Pigmentosa**

Oliveira M, Neves E, Marques JP

*JAMA Ophthalmol*. 2020 Jun 1;138(6):e193133.

### **Subretinal bleb of Voretigene Neparvovec**

Marques JP, Alfaiate M, Figueira J

*Asia Pac J Ophthalmol (Phila)*. 2022 Mar-Apr;11(2):211.

### **Eyes Shut Homolog-Associated Retinal Degeneration: Natural History, Genetic Landscape, and Phenotypic Spectrum**

Soares RM, Carvalho AL, Simão S, Soares CA, Raimundo M, Alves CH, Ambrósio AF, Murta J, Saraiva J, Silva R, Marques JP

*Ophthalmol Retina*. 2023 Feb 9;S2468-6530(23)00054-4. Online ahead of print.

### **Self-reported visual function and psychosocial impact of visual loss in EYS-Associated Retinal Degeneration in a Portuguese population**

Marques JP, Soares RM, Simão S, Abuzaitoun R, Andrews C, Alves CH, Ambrósio F Silva R, Abalem MF, Jayasundera KT

*Ophthalmic Genet*. 2023 Mar 22;1-7. Online ahead of print.

**Current Management of Inherited Retinal Degeneration Patients in Europe: Results of a Multinational Survey by the European Vision Institute Clinical Research Network**

Lorenz B, Tavares J, van den Born LI, [Marques JP](#), Scholl HPN, EVICR.net Group  
*Ophthalmic Res.* 2021;64(4):622-638.

**See Annex I**

**Current Management of Patients with RPE65 Mutation-Associated Inherited Retinal Degenerations in Europe: Results of a Multinational Survey by the European Vision Institute Clinical Research Network**

Lorenz B, Tavares J, van den Born LI, [Marques JP](#), Scholl HPN, EVICR.net Group  
*Ophthalmic Res.* 2021;64(5):740-753.

**See Annex II**

**Response to "Comment on the Article: Subretinal bleb of Voretigene Neparvovec"**

[Marques JP](#), Alfaiate M, Figueira J

*Asia Pac J Ophthalmol (Phila).* 2022 Mar 25. Online ahead of print.

**See Annex III**

**Molecular and Multimodal Retinal Imaging Findings in a Multicentric Portuguese Cohort of Stargardt Disease**

Geada S, Santos C, Vaz-Pereira S, Marta A, Correia M, Sousa K, Soares M, Carvalho AL, Saraiva J, Murta J, Silva R, Coutinho-Santos L, [Marques JP](#)

*Revista Sociedade Portuguesa de Oftalmologia* 2022;46(1):15-24.

**See Annex IV**

**Genomic Landscape and Natural History of Sector Retinitis Pigmentosa**

Cortinhal T, Geada S, Neves E, Carvalho AL, Saraiva J, Silva R, Murta J, [Marques JP](#)

*Revista Sociedade Portuguesa de Oftalmologia* 2022;46(1):25-32.

**See Annex V**

## **CHAPTER 8: FUNDING**





## **8. FUNDING**

The IRD-PT registry received specific funding for its development and implementation, namely for IT support, data management activities, design and layout. This came as a grant from Novartis® Portugal and the Portuguese Society of Ophthalmology. Neither entity had, has or will have any interference on the collection, analysis, and/or interpretation of data, nor have any type of proprietary interest in the generated data. Additional funding from the Portuguese Society of Ophthalmology was used to pay for scientific publications in open access journals.

Recently, a research project in the scope of the IRD-PT: 'EYS ON' RETINITIS PIGMENTOSA 25, received an investigation grant from Abbvie® and the Portuguese Retina Study Group and we are currently awaiting approval from the Ethics Committee to start enrolling patients.



## **CHAPTER 9: ANNEXES**



ANNEX I

**9.1. Current Management of Inherited Retinal Degeneration Patients in Europe:  
Results of a Multinational Survey by the European Vision Institute Clinical Research  
Network**

Lorenz B, Tavares J, van den Born LI, Marques JP, Scholl HPN, EVICR.net Group  
*Ophthalmic Res.* 2021;64(4):622-638.



# Current Management of Inherited Retinal Degeneration Patients in Europe: Results of a Multinational Survey by the European Vision Institute Clinical Research Network

Birgit Lorenz<sup>a, b</sup> Joana Tavares<sup>c</sup> L. Ingeborgh van den Born<sup>d</sup>  
João P. Marques<sup>e, f, g</sup> Hendrik P. N. Scholl<sup>h, i, j</sup> the EVICR.net Group

<sup>a</sup>Department of Ophthalmology, Justus-Liebig-University Giessen, Giessen, Germany; <sup>b</sup>Department of Ophthalmology, University Hospital Bonn, Bonn, Germany; <sup>c</sup>Association for Innovation and Biomedical Research on Light and Image (AIBILI), Coimbra, Portugal; <sup>d</sup>Rotterdam Eye Hospital and Rotterdam Ophthalmic Institute, Rotterdam, The Netherlands; <sup>e</sup>Center for Clinical Trials, Association for Innovation and Biomedical Research on Light and Image (AIBILI), Coimbra, Portugal; <sup>f</sup>Department of Ophthalmology, Centro Hospitalar e Universitário de Coimbra (CHUC), Coimbra, Portugal; <sup>g</sup>Faculty of Medicine, University of Coimbra (FMUC), Coimbra, Portugal; <sup>h</sup>Institute of Molecular and Clinical Ophthalmology Basel (IOB), Basel, Switzerland; <sup>i</sup>Department of Ophthalmology, University of Basel, Basel, Switzerland; <sup>j</sup>Wilmer Eye Institute, Johns Hopkins University, Baltimore, MD, USA

## Keywords

Inherited retinal degenerations · Management · Europe · EVICR.net clinical centers

## Abstract

**Purpose:** An increasing number of gene therapies are developed for Inherited Retinal Degenerations (IRD). To date, 1 treatment has been approved for clinical use (FDA USA 2017, EMA Europe 2018, MoHAP UAE 2019, SFDA Saudi Arabia 2019, Swiss Medic Switzerland 2020, TGA Australia 2020, and BFR Brazil 2020). While such therapies do not provide complete cure, they may halt degeneration or partially restore function. Identification of well-characterized patients is an emerging need. We conducted the first multinational survey to understand the management of IRDs in Europe. **Methods:** An electronic survey questionnaire containing 112 ques-

tions was developed and sent to the 101 EVICR.net clinical centers (14 European countries and Israel). **Results:** The overall response rate was 49%. Only 14% of responding centers do not see IRD patients; 52% that manage IRD patients follow  $\geq 200$  patients, 16%  $> 1,000$ . Databases exist in 86% of the centers; of these, 75% are local files, 28% local Web-based database, and 19% national Web-based. IRD patients are referred to EVICR.net centers mainly by general ophthalmologists, patient self-referrals, and medical retina specialists. Most IRD patients are first seen in adulthood. Most prominent signs and symptoms depend on the age of onset, for example, nystagmus in infancy, or night blindness, and reduced visual acuity at older age. The time from inquiring for first appointment and clinical diagnosis varies among

Birgit Lorenz and Joana Tavares contributed equally.

countries: in 29% of centers, the mean time is <4 weeks, although can be up to 35 months in others. The time to genetic diagnosis is  $\geq 4$  weeks, the maximum 10 years, likely depending on access to genetic testing, and the improvement of the tests available. Comprehensive eye examination always includes autofluorescence imaging and perimetry (86% static, 76% kinetic, and 21% microperimetry), and frequently optical coherence tomography (OCT) (95%), electroretinography (93%), and fundus photography (93%). Identified genotypes were reported in 40–80% patients by 69% of centers, and in 80–100% by 5%. Genetic testing is provided by public health insurance in 77% of centers, private health insurance in 38%, center budget in 13%, research funds in 18%; and 15% of centers do not have access to genetic testing. **Conclusion:** At the start of this era of ocular gene therapy for IRD patients, this first international survey on management of IRDs in Europe highlights significant heterogeneity between centers and across countries and provides important baseline data for researchers, clinicians, pharmaceutical companies, and investors.

© 2021 The Author(s)

Published by S. Karger AG, Basel

## Introduction

Inherited retinal degenerations (IRDs) are both, genetically and clinically, extremely heterogeneous, with mutations in over 300 genes identified as of April 2020 [1]. They are potentially blinding disorders with a prevalence of about 1 in 3,000 [2] and no medical treatment for the vast majority until very recently. The interest has increased significantly in recent years due to the development of therapies for an increasing number of disease-causing genes [3–5]. The aim of this study was to conduct the first international survey to understand management and experience of IRDs across Europe because of a lack of data, and because of potential differences among and within countries. The clinical research network established by the European Vision Institute (EVICR.net) appeared to be an appropriate platform for the survey. At the time of the survey, the network had 101 registered members.

We aimed to explore throughout Europe, nation wise and across nations, the following variables: distribution of IRDs, diagnosis and management of IRDs, availability of genetic testing and genetic counseling, as well as actual involvement in clinical trials. In addition, we wanted to get detailed information about diagnosis, prevalence, and management of patients with RPE65 mutation-associated IRDs [3, 6, 7]. For the latter, an approved gene ther-

apy is now available in an increasing number of countries worldwide (FDA USA 2017, EMA Europe 2018, MoHAP United Arab Emirates 2019, SFDA Saudi Arabia 2019, Swiss Medic Switzerland 2020, TGA Australia 2020, and BFR Brazil 2020) at considerable cost for the national health-care system [8–10]. The results of that part of the survey will be reported in a separate article. The hypothesis was that IRDs are still underdiagnosed, and that a significant number of patients suitable for clinical trials and clinically available therapy remain unidentified to date. We sought to answer questions as to IRD demographics, local set-up to diagnose and follow patients with IRDs, availability and application of genetic testing as well as genetic counseling, and involvement in clinical trials on IRDs. The survey allowed the identification of significant bottlenecks to optimal care by IRD patients in Europe. Consequently, it may help to improve these shortcomings.

## Materials and Methods

### *Study Design and Questionnaire*

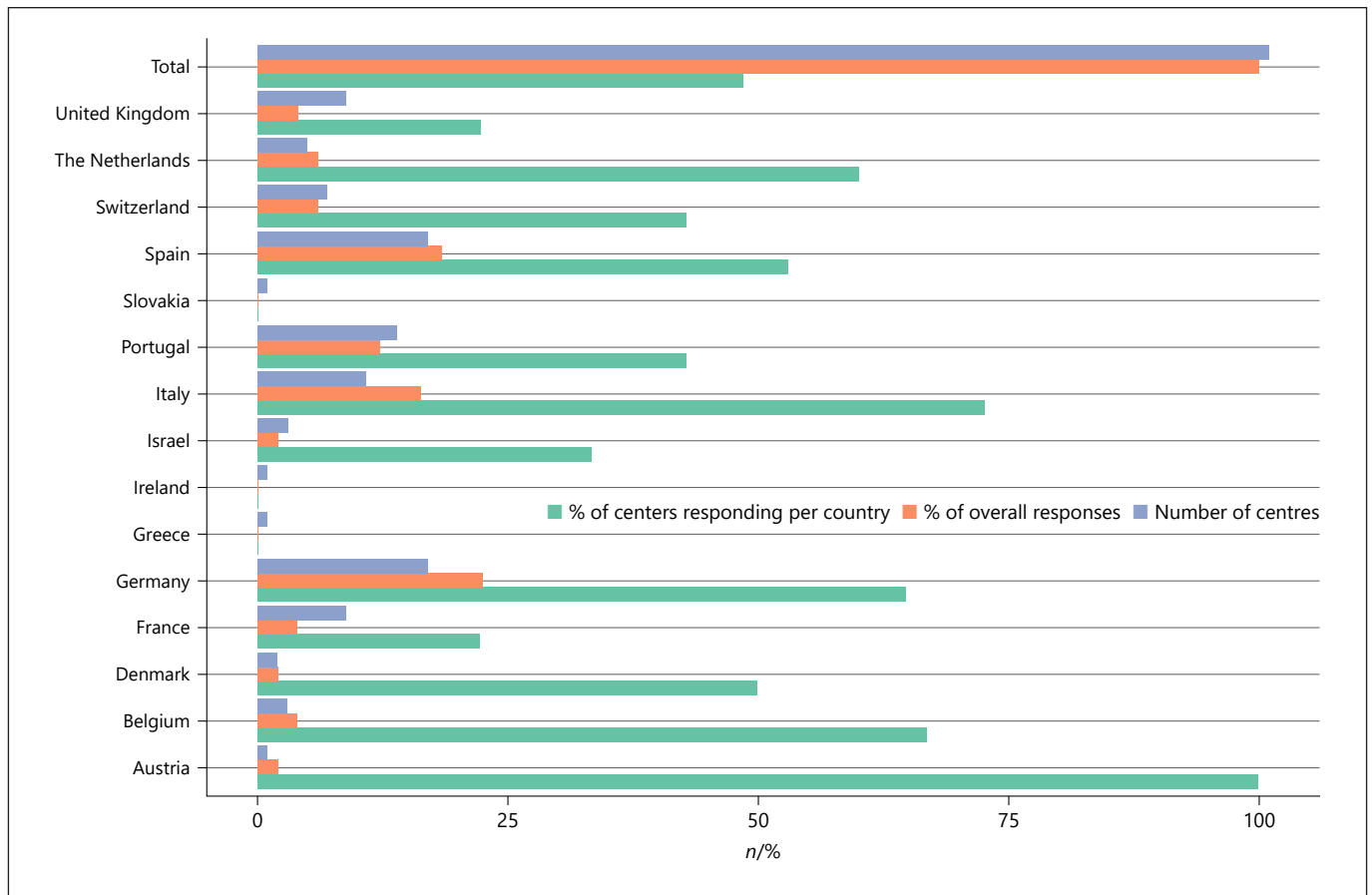
An IRD Survey Expert Committee developed the IRD Survey Questionnaire. The Committee was composed by Birgit Lorenz, MD PhD, Germany (Scientific Coordinator), Hendrik Scholl, MD PhD, Switzerland, Isabelle Audo, MD PhD, France, Ingeborgh van den Born, MD PhD, The Netherlands, and João Pedro Marques, MD, Portugal.

The electronic questionnaire comprised 112 questions arranged in 5 sections: (1) IRD demographics, (2) local setting, (3) IRD genetic testing and counseling, (4) involvement in clinical trials, and (5) RPE65 mutation-associated IRDs, which followed a conditional branching (see online suppl. Material; for all online suppl. material, see [www.karger.com/doi/10.1159/000514450](http://www.karger.com/doi/10.1159/000514450)). The questionnaire was designed to have mostly multiple-choice questions and single choice questions (closed-ended items), in which the options represent a range of values, which means that only estimates were requested. Here, we present the results from sections 1 to 4.

In May 2019, all EVICR.net clinical centers, comprising 14 European countries, that is, Austria, Belgium, Denmark, France, Germany, Greece, Italy, The Netherlands, Portugal, Spain, Slovakia, Switzerland, Portugal, UK, and Israel, were invited by e-mail to complete the online questionnaire. This invitation was sent to the responsible person of the clinical center and also to its representative for the EVICR.net Retinal Dystrophies Scientific Section; however, no restrictions were imposed to participate in the survey (shared via public link). Therefore, any member of the clinical center staff (e.g., medical retina ophthalmologist, general ophthalmologist, pediatric ophthalmologist, and other) could have replied to the survey on their center's behalf. Only 1 reply per clinical center was considered. Of the 101 member centers, 63 are EVICR.net-certified clinical centers and the remaining are under the certification process.

The identification of the EVICR.net member as well as name, function, and contacts (e-mail and telephone) of the replier was





**Fig. 1.** Distribution of IRD Survey replies by country (green and red bars) and the number of EVICR.net clinical centers per country (blue bars). The mean number of replies was 49%. IRD, inherited retinal degeneration.

requested as they are all EVICR.net members with a Confidentiality Disclosure Agreement in place. A reminder was sent to the non-repliers after 2 weeks, the deadline was extended for 2 more weeks, and new reminders were sent on week 3 and week 4, 2 days before the final deadline. Strategies to maximize the response rate were follow-up contact, hard copy of the questionnaire, personalized e-mails, and giving an ultimate deadline.

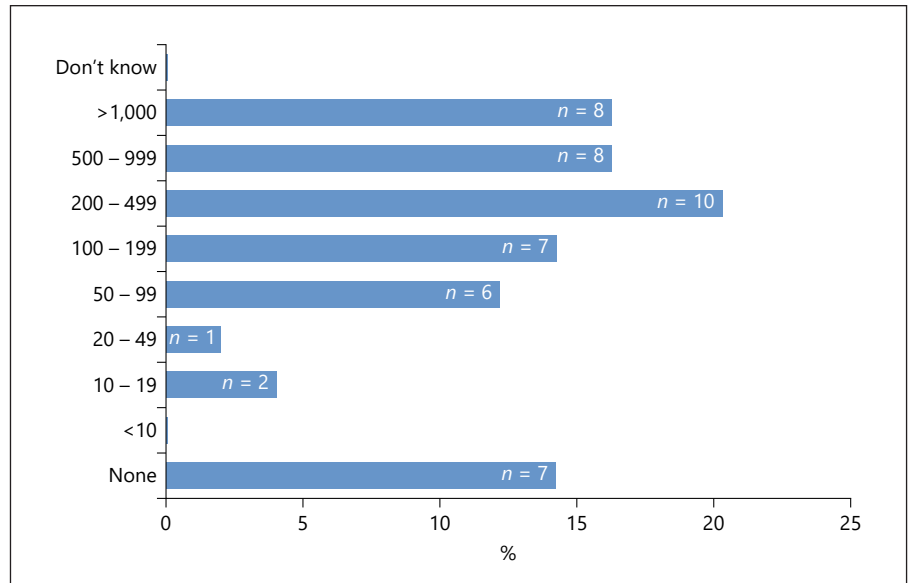
#### Statistical Analysis

A descriptive analysis was conducted for all variables. Continuous variables were summarized using the following statistics: number (*n*), mean, standard deviation (SD), median (P50), first and third quartiles (P25 and P75), minimum (Min), and maximum (Max). The frequency and percentages of observed levels were reported for all categorical measures. Statistical analyses were performed with Excel version 15.0.4433.1508 (Microsoft Office Home and Business 2013) and R version 3.6.0 (2019-04-26). We did not exclude questionnaires due to missing values. However, each analysis was restricted to repliers with no missing values for the respective question, that is, the total number of repliers differed between questions.

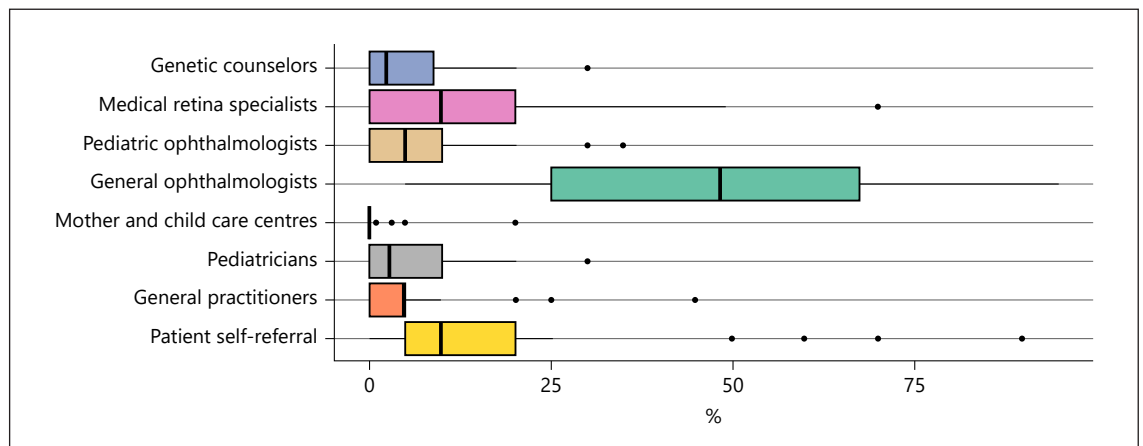
## Results

Forty-nine percent of the 101 EVICR.net Clinical Research Centers in 15 countries who had received the online survey responded (49 centers, Fig. 1). In 9/15 countries, the response rate per country was at least 43%. There was no significant difference in the response rate of certified versus non-certified EVICR.net centers (28 [57%] vs. 21 [43%]). Sixty-seven percent of responding centers are tertiary academic centers.

Most of the time, the survey was filled out by general ophthalmologists (43%), medical retina specialists (39%) and less often by pediatric ophthalmologists (4%), study coordinators (4%), pediatric ophthalmologists and ophthalmogeneticists (2%), assistant directors/pharmacists (2%), medical retina specialist and electrophysiology (ERG) specialists (2%), medical retina specialists and ophthalmogeneticists (2%) and medical/surgical retina, and uveitis specialists (2%).



**Fig. 2.** Distribution of the number of IRD patients currently managed by centers. IRD, inherited retinal degeneration.

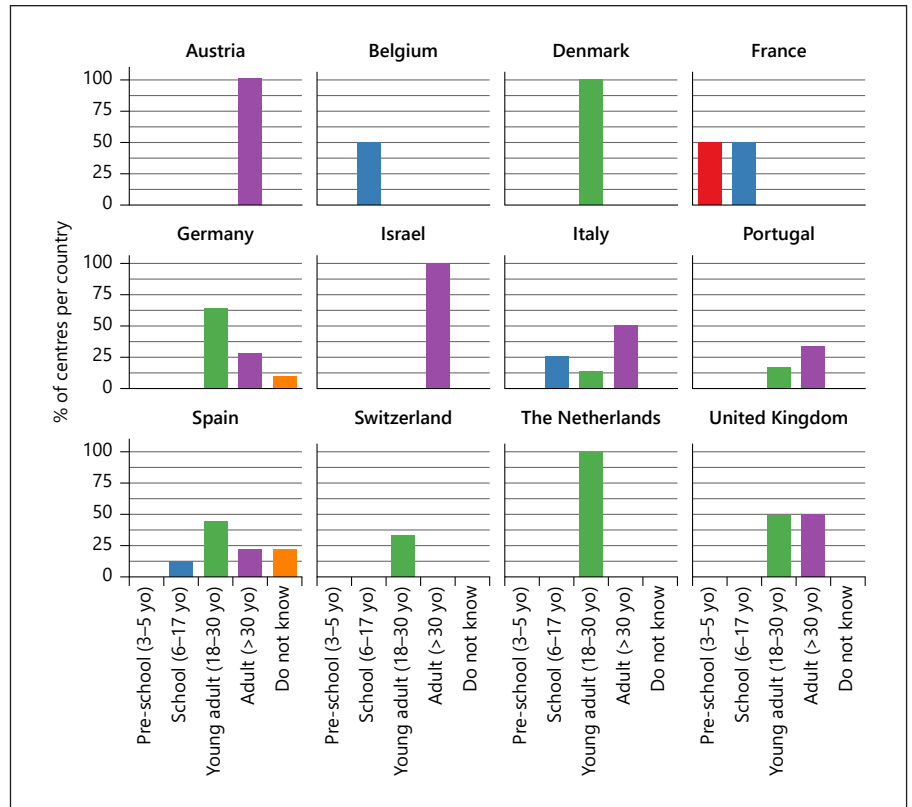


**Fig. 3.** Referral pathways. Box plots of the percentage of the referees of IRD patients to the EVICR.net clinical centers: the box signifies the third quartile (Q3) and first quartile (Q1) range of data, and the median is represented by a black line within the box for each type of referees of IRD patients. Data falling outside the Q1–Q3 range are plotted as outliers of the data and are depicted by black dots. IRD, inherited retinal degeneration.

### IRD Demographics

Only 14% of the responding centers (7/49) do not see IRD patients; these are centers from Switzerland (2/3), Portugal (3/6), Belgium (1/2), and Italy (1/8). All centers that see IRD patients have at least 10 patients currently managed at their centers (Fig. 2), 52% actually manage at least 200 patients. Centers in Spain and Portugal currently manage the lowest number of IRD patients. Highest numbers of IRD patients being currently managed were reported in centers from The Netherlands, France, Germany, Spain, and Switzerland.

When questioned about the use of a database for IRD patients, 86% of the centers have 1. Of these, 75% have IRD patients registered in local files, such as Excel, 28% in local Web-based databases, and 19% have access to national Web-based databases. The majority of the centers (67%) have between 100 and 1,999 IRD patients in the database. The Netherlands, Italy, Germany, and Spain are the countries with centers that have databases with >2,000 IRD patients (online suppl. Table 1). All centers manage IRD patients themselves; however, 17% of these centers also refer IRD patients to expert centers. On the other



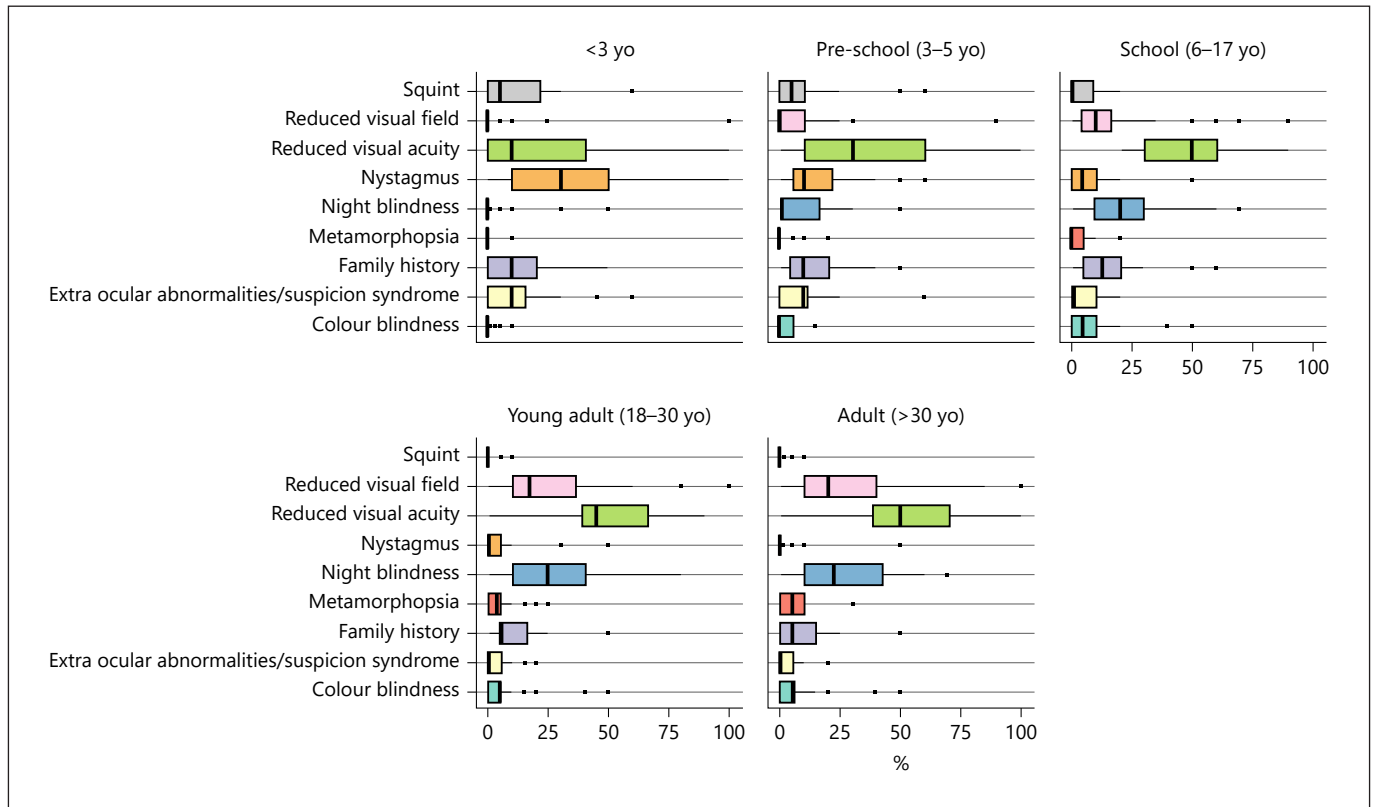
**Fig. 4.** Current age of the majority of the diagnosed IRD cases distributed by the country. The percentage of centers per country was calculated based on the total number of centers that replied for each country. IRD, inherited retinal degeneration.

hand, general ophthalmologists are the main referees of IRD patients to the EVICR.net centers, followed by patient self-referral and medical retina specialists (Fig. 3).

For the majority of IRD patients, the first visit occurs at an adult age (online suppl. Fig. 1). In 45% of the centers, the majority of the diagnosed IRD cases occur in young adults, followed by adults in 33% of the centers (online suppl. Table 2). This trend is verified per country, with the exception of the centers in France, where the majority of the diagnosed IRD cases occurs in preschool and school ages (Fig. 4). Of note, only 22% of the EVICR.net centers in France participated in the survey.

Main signs and/or symptoms implicating a visit in the centers are nystagmus and reduced visual acuity followed by positive family history in infants and young children ( $\leq 5$  years old); reduced visual acuity followed by night blindness in children/adolescents from 6 to 17 years old; reduced visual acuity, reduced visual field, and night blindness in young adults and adults (Fig. 5). When questioned about the mean time between inquiry of an appointment and the first contact with a retina expert and final diagnosis, 43% of the centers reported a time of  $<4$  weeks between inquiry of appointment and first contact

(most of the centers in Italy [5/8] and Spain [7/9], online suppl. Fig. 2), and 29% of the centers reported a time of  $<4$  months between inquiry of an appointment and final ophthalmological diagnosis. On the other hand, the longest mean time between inquiry of appointment and first contact with a retina expert for IRD patients is 30 months in Germany (online suppl. Fig. 2). Consequently, the longest mean time between inquiry of appointment and the final ophthalmological diagnosis for IRD patients is 35 months in Germany (online suppl. Fig. 3). Adding a final genetic diagnosis increases the mean time between inquiry of appointment and final ophthalmological and genetic diagnosis. For 95% of centers, the mean time between inquiry of appointment and final ophthalmological and genetic diagnosis is at least 4 weeks (5% of the repliers did not know the meantime, online suppl. Fig. 4). Of these, for 28% of the centers, it takes 12 months to get a final genetic diagnosis; for 21%, it takes 6 months, and only for 33%, it takes less than 6 months. The highest mean time between inquiry of appointment and final ophthalmological and genetic diagnosis for IRD patients is 10 years in the UK (online suppl. Fig. 4).



**Fig. 5.** Reasons for referral of IRD patients to the EVICR.net clinical centers. Box plots of the percentage of signs/symptoms of IRD patients implicating a visit at a center: the box signifies the third quartile (Q3) and first quartile (Q1) range of data, and a black line within the box for each sign/symptom represents the median. Data falling outside the Q1–Q3 range are plotted as outliers of the data and are depicted by black dots. IRD, inherited retinal degeneration.

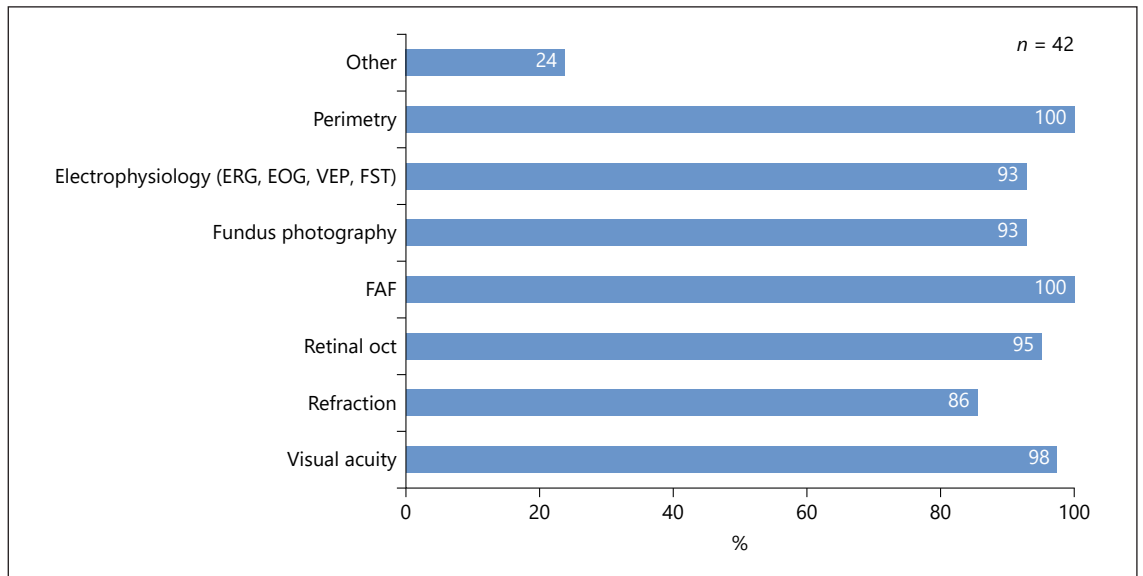
### Local Setting

For centers that selected “Refer IRD patients to expert centers” in Question 2 of Section 1, the basic tests performed in IRD patients referenced to expert centers are visual acuity, fundus imaging, fundus autofluorescence (FAF), and retinal stratification (online suppl. Fig. 5). Eighty-six percent of the centers that refer IRD patients also perform visual fields, 71% perform ERG, and 14% perform optical coherence tomography angiography, fluorescein angiography, and indocyanin angiography, if deemed necessary.

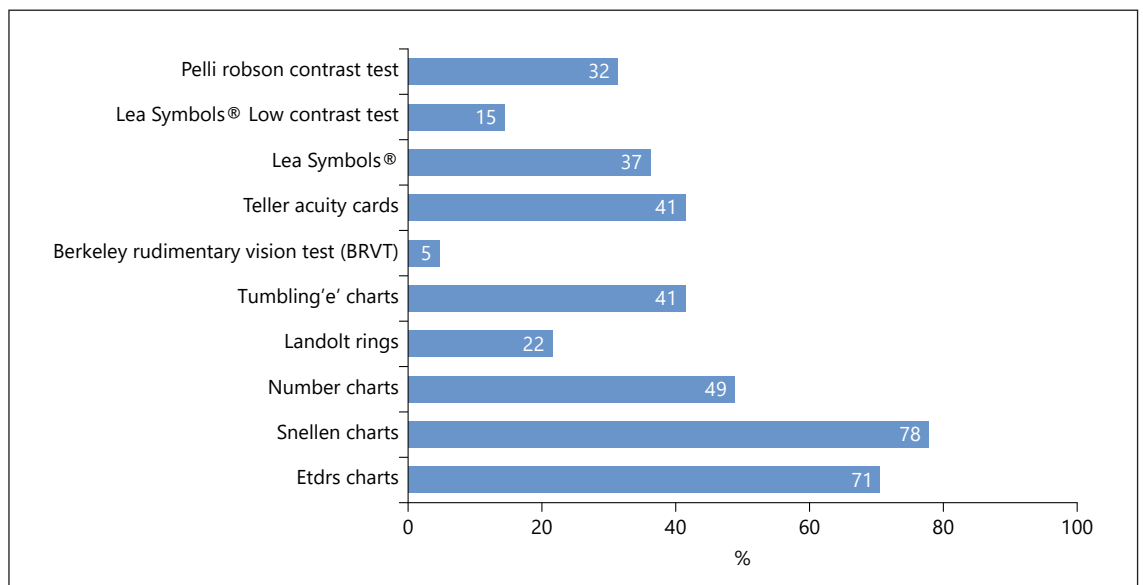
In centers that manage the IRD patients themselves, FAF and perimetry are always performed for setting a clinical diagnosis of IRD in addition to a comprehensive clinical standard examination (Fig. 6). Additionally, visual acuity (98%), retinal stratification by optical coherence tomography (OCT) (95%), fundus photography (93%), (ERG, electrooculography [EOG], and visual evoked potentials [VEP]), including full-field sensitivity

threshold testing (FST) (93%), and refraction (86%) are parameters highly applied for setting a clinical diagnosis of IRD (Fig. 6). Section 2 of the IRD survey included also an option “Other,” where additional methods could be added as free text. Answers included personal and family history, optical coherence tomography angiography, retinal vessel oximetry, microperimetry, 2-color-threshold perimetry, gene testing, fluorescein angiography color vision testing, contrast sensitivity, biomicroscopy with fundus examination, adaptive optics, and own diagnostics development in 2% of the centers.

For visual acuity testing in IRD patients, centers use mainly Snellen charts (78%), ETDRS charts (71%), number charts (49%), Tumbling “E” charts (41%), Teller acuity cards (41%), Lea Symbols® (37%), and Pelli Robson contrast test (32%). All results are displayed in Figure 7. Regarding refraction, 94% of the centers use autorefractometer in IRD patients and 58% of the centers use retinoscopy. For detailed results see Table 1.



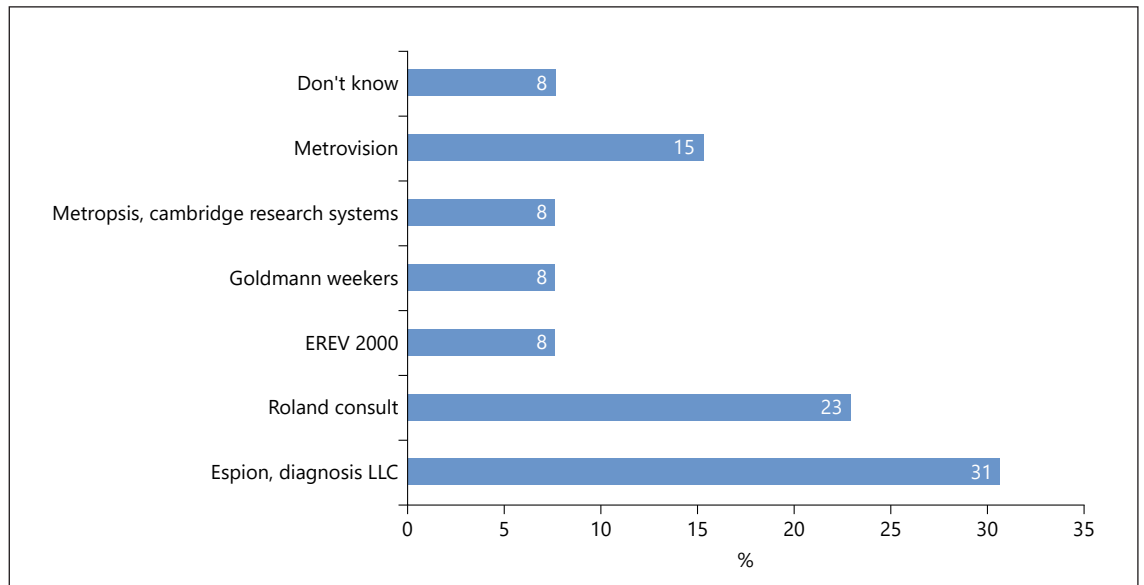
**Fig. 6.** Parameters applied for setting a clinical diagnosis of IRD in centers that manage IRD patients. Multiple choices were allowed. For explanation of FST, see text. ERG, electroretinogram; EOG, electrooculography; FAF, fundus autofluorescence; FST, full-field sensitivity threshold; OCT, optical coherence tomography; VEP, visual evoked potential.



**Fig. 7.** Methods for visual acuity testing used in IRD patients. Multiple choices were allowed. IRD, inherited retinal degeneration.

Regarding retinal stratification (OCT), 88% of the centers use Spectralis® Heidelberg Engineering GmbH in IRD patients, specifically OCT (83%), and OCT EDI (74%). To evaluate FAF, 88% of the centers use Spectralis® Heidelberg Engineering GmbH in IRD patients, 12%

use Optomap® Panoramix 200 Tx (Optomap; Optos, Dunfermine, Scotland), 10% use Triton (Topcon Medical Systems, Oakland, NJ, USA), and 7% use Clarus (Carl Zeiss Meditec, Jena, Germany).



**Fig. 8.** Dark adaptometry devices used in IRD patients. IRD, inherited retinal degeneration.

**Table 1.** Devices/test for refractometry used in IRD patients

	<i>n</i>	%
Retinoscopy	21	58
Autorefractometer	34	94
NIDEK Co., LTD, Aichi, Japan	22	65
Topcon medical systems, Oakland, NJ, USA	14	41
Reichert Inc., Depew, NY, USA	2	6
<i>Total</i>	55	153*
<i>Total of Centers applying refraction</i>	36	100

IRD, inherited retinal degeneration. \* Multiple choices allowed.

**Table 2.** Methods of visual field testing used in IRD patients

	<i>n</i>	%
Kinetic perimetry	32	76
Static perimetry	36	86
Fundus-controlled perimetry	9	21
<i>Total</i>	77	183*
<i>Total of centers applying perimetry</i>	42	100

IRD, inherited retinal degeneration. \* Multiple choices allowed.

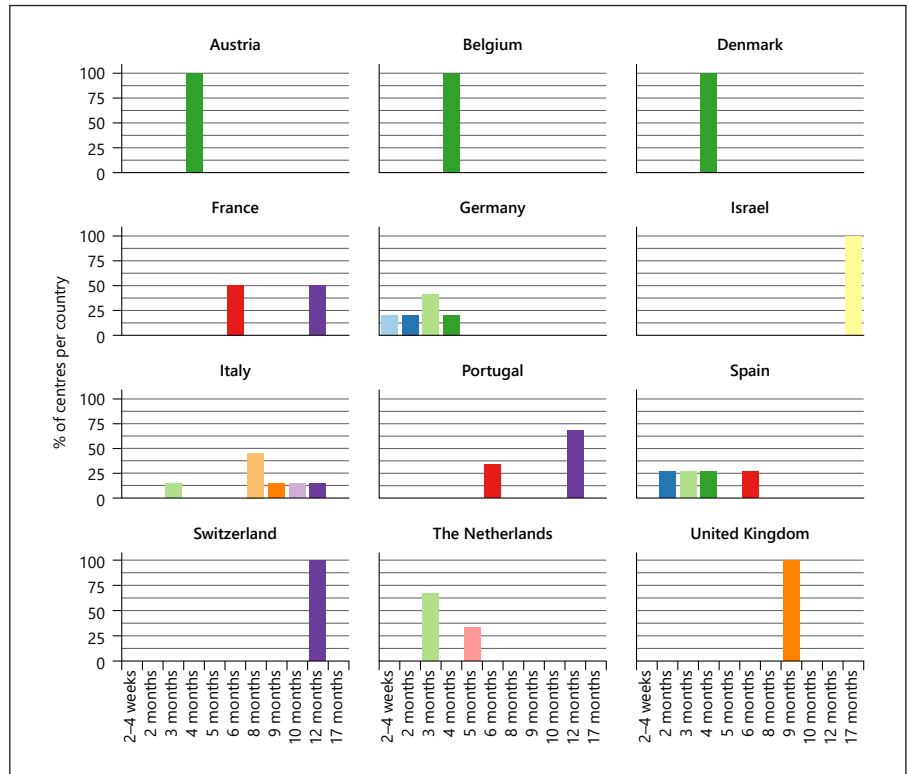
Regarding fundus photography, 87% of the centers use standard fundus cameras, whereas 56% use wide-field fundus cameras in IRD patients. From centers that use standard fundus cameras, 53% use Topcon Medical

Systems (Oakland, NJ, USA) device and 41% a Carl Zeiss Meditec (Jena, Germany) device. An Optos (Dunfermline, Scotland) wide-field fundus camera is used in 68% of the centers performing wide-field fundus photography.

Regarding ERG, the main tests used in IRD patients are full-field ERG (95%), multifocal ERG (90%), EOG (85%), and VEP (77%). For full-field ERG, the devices used most frequently are Espion (Diagnosys LLC, Lowell, MA, USA) (38%) and RETIport/Scan21 (Roland Consult Stasche & Finger GmbH, Brandenburg an der Havel, Germany) (35%). RETIport/Scan21 (Roland Consult Stasche & Finger GmbH, Brandenburg an der Havel, Germany) is the device used most frequently in multifocal ERG (40%), and VEP (40%). On the other hand, Espion (Diagnosys LLC, Lowell, MA, USA) is the most frequently used device in EOG (42%), dark adaptation (31%, Fig. 8), and FST (80%). Eighty percent of the centers using FST in IRD patients perform chromatic FST (blue, red, and white), whereas 20% of the centers performs the white testing only. Regarding perimetry, centers use mainly static perimetry (86%) and kinetic perimetry (76%) (Table 2). For detailed information as to the instruments used see online suppl. Table 3a–c.

#### *IRD Genetic Testing and Counseling*

From the centers that manage IRD patients themselves, 93% perform genetic testing at their centers, and 54% of these centers have more than 61% of their IRD



**Fig. 9.** Mean time to get the genetic test result in IRD patients distributed by country. The percentage of centers per country was calculated based on the total number of centers that replied for each country. IRD, inherited retinal degeneration.

**Table 3.** Centers genetically testing IRD patients and with genetic testing laboratory certified distributed by country

Country	Centers genetically testing IRD patients				Centers with genetic testing laboratory certified			
	no	total centers that replied per country	% centers per country	% overall responses	no	total centers that replied per country	% centers per country	% overall responses
Austria	1	1	100	3	1	1	100	3
Belgium	1	2	50	3	1	1	100	3
Denmark	1	1	100	3	1	1	100	3
France	2	2	100	5	2	2	100	7
Germany	10	11	91	26	9	10	90	30
Israel	1	1	100	3	1	1	100	3
Italy	7	8	88	18	6	7	86	20
Portugal	3	6	50	8	2	3	67	7
Spain	8	9	89	21	4	8	50	13
Switzerland	1	3	33	3	0	3	0	0
The Netherlands	3	3	100	8	3	3	100	10
UK	1	2	50	3	0	2	0	0
<i>Total</i>	39	49	-	100	30	-	-	100

IRD, inherited retinal degeneration.

patients genetically tested. Five percent do not genetically test IRD patients due to (1) hospital administration constraints, (2) no practical benefit for patient, or (3) no geneticist in the center. From those, 50% refer patients to

other institutions/laboratories. Table 3 shows centers that genetically test their IRD patients distributed by country.

From the centers that genetically test their IRD patients, 74% perform genetic tests externally (79% in a na-

**Table 4.** Estimated percentage of IRD patients that has been genetically solved at each center distributed by country

Country	<i>n</i>	Total centers at section 3 per country	% per country
0–20%			
Germany	1	10	10
Italy	1	7	14
Spain	1	8	13
UK	1	1	100
21–40%			
France	1	2	50
Spain	3	8	38
41–60%			
Denmark	1	1	100
France	1	2	50
Germany	3	10	30
Israel	1	1	100
Italy	5	7	71
Spain	1	8	13
The Netherlands	3	3	100
61–80%			
Austria	1	1	100
Belgium	1	1	100
Germany	4	10	40
Italy	1	7	14
Portugal	1	3	33
Spain	3	8	38
Switzerland	1	1	100
81–100%			
Germany	1	10	10
Portugal	1	3	33
Do not know			
Germany	1	10	10
Portugal	1	3	33
<i>Total</i>	39	–	–

The percentage of centers per country was calculated based on the total number of centers that responded for each country. IRD, inherited retinal degeneration.

tional lab, 55% in an external research lab, and 21% in an international lab) and 38% perform in house (87% clinical care and 40% in research lab). In 77% of the centers, the genetic testing laboratory is certified. All centers responding from Austria, Belgium, Denmark, France, Israel, and The Netherlands have their genetic testing laboratory certified (Table 3). Ninety percent of centers in Germany and 86% of Italian centers have their genetic testing laboratory certified (Table 3). Thirty-three percent of centers that perform genetic testing refer to Clinical Laboratory Improvement Amendments, and 49% refer to national guidelines and protocols. Of the 39 centers

**Table 5.** Type of IRD-specific gene panel performed

	<i>n</i>	%
General panel	19	73
LCA panel	19	73
RP panel	20	77
CRD panel	18	69
Optic atrophy panel	18	69
Other: blindness	1	4
Other: macular dystrophy	1	4
Other: mtDNA	1	4
Other: genetics lab decides	1	4
Do not know	1	4
<i>Total</i>	99	381*
<i>Total of centers performing IRD-specific gene panel</i>	26	100

LCA, Leber congenital amaurosis; RP, retinitis pigmentosa; CRD, cone-rod dystroph; mtDNA, mitochondrial DNA; IRD, inherited retinal degenerations. \* Multiple choices allowed.

that genetically test their IRD patients, 36 (92%) offer genetic counseling. In other centers, genetic counseling is center-based (33%) or provided by external genetic counselors (67%).

When questioned on the mean time to get the genetic test result, the lowest mean time was between 2 and 4 weeks reported in Germany (2/10) (Fig. 9). In 95% of centers, the time to receiving the genetic test result is higher than 1 month. The mean time to get the genetic test result for IRD patients is higher in Israel, France, Italy, Portugal, Switzerland, and UK, with the highest mean time of 17 months in Israel (Fig. 9).

Sixty-nine percent of the centers replied that only 41–80% of the IRD patients have been genetically solved, and only 5% of the centers have 81–100% of the IRD patients genetically solved. Table 4 shows the estimated percentage of IRD patients that has been genetically solved at each center by country.

In most centers, IRD patients are only tested with clinical grade tests, followed by centers that tested with research and clinical grade tests (Fig. 10). The most used technologies for genetic testing in IRD patients were IRD-specific gene panels (67%), WES (49%), and diagnosis-directed Sanger sequencing (41%). Details as to the extent of genetic testing are seen in online suppl. Fig. 6.

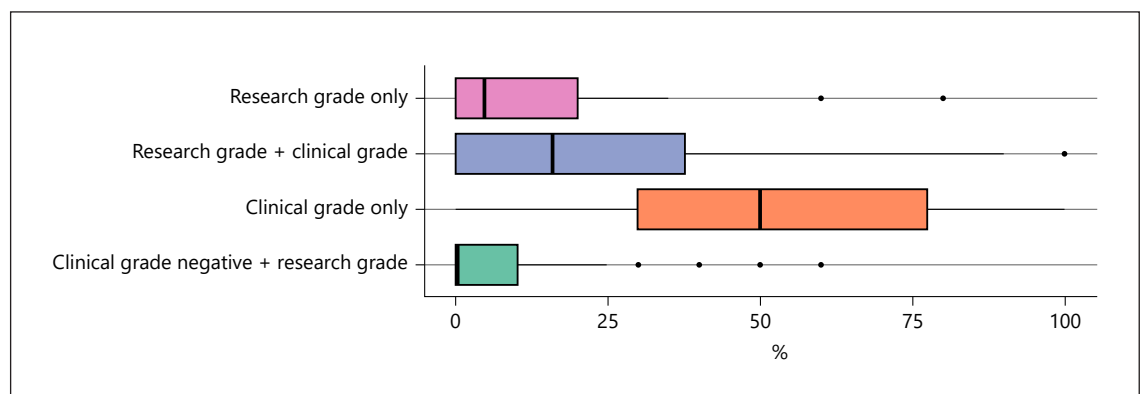
Regarding IRD-specific gene panels, an RP panel was performed in 77% of the centers, a general panel and Leber congenital amaurosis (LCA) panel in 73%, a CRD panel, and an optic atrophy panel in 69% (Table 5). Within the gene panel used, the number of genes tested varied



**Table 6.** Costs of genetic testing in IRD patients by country

Who covers the costs of genetic testing in your IRD patients?	Country	<i>n</i>	Total centers at section 3 per country	% Centers per country
Covered by public health service	Austria	1	1	100
	Denmark	1	1	100
	France	2	2	100
	Germany	10	10	100
	Israel	1	1	100
	Italy	7	7	100
	Portugal	3	3	100
	Spain	3	8	38
	The Netherlands	1	3	33
	UK	1	1	100
	<i>Total</i>		30	-
Covered by private health insurance	Germany	8	10	80
	Spain	3	8	38
	Switzerland	1	1	100
	The Netherlands	3	3	100
	<i>Total</i>	15	-	-
Covered by center budget	Austria	1	1	100
	Belgium	1	1	100
	Denmark	1	1	100
	Spain	2	8	25
	<i>Total</i>	5	-	-
Research funding only	Germany	2	10	20
	Israel	1	1	100
	Italy	1	7	14
	Spain	1	8	13
	The Netherlands	1	3	33
	UK	1	1	100
	<i>Total</i>	7	-	-
No coverage available	Spain	6	8	75
	<i>Total</i>	6	-	-

The percentage of centers per country was calculated based on the total number of centers that replied per country. Multiple choices were allowed. IRD, inherited retinal degeneration.



**Fig. 10.** Percentage of IRD patients tested with clinical grade and research grade tests. IRD, inherited retinal degeneration.

**Table 7.** Involvement in clinical studies with gene therapies for IRD by country

Country	<i>n</i>	Total centers at section 4 per country	% Centers per country
<b>Currently involved</b>			
France	2	2	100
Germany	3	10	30
Italy	1	7	14
Spain	1	8	13
The Netherlands	2	3	67
<i>Total</i>	9	–	–
<b>Previously involved</b>			
Belgium	1	1	100
The Netherlands	1	3	33
<i>Total</i>	2	–	–
<b>Not involved</b>			
Germany	2	10	20
Portugal	1	3	33
Spain	1	8	13
UK	1	1	100
<i>Total</i>	5	–	–
<b>Interested in being involved</b>			
Austria	1	1	100
Denmark	1	1	100
Germany	5	10	50
Israel	1	1	100
Italy	6	7	86
Portugal	2	3	67
Spain	6	8	75
Switzerland	1	1	100
<i>Total</i>	23	–	–

IRD, inherited retinal degeneration.

widely from just a few to several thousand, and some centers noted that the panels were regularly updated. This high variance reflects the evolution of genetic testing in recent years. Online suppl. Table 4 indicates the panel sizes used in the 20 centers that answered to using gene panel testing.

Costs of genetic testing are covered by public health service in 77% of the centers, private health insurance in 38%, center budget in 13%, research funding only in 18%, and not covered in 15%. Interestingly, the cost of genetic testing is not covered in 75% of the centers from Spain (6/8). On the other end, costs of genetic testing are covered by public health service in Austria, Denmark, France, Germany, Israel, Italy, Portugal, and UK (Table 6).

**Table 8.** Centers currently or previously involved in clinical study with gene therapies for IRD by country

Countries currently or previously involved in clinical study with gene therapies for IRD	<i>n</i>	%
Belgium	1	9
France	2	18
Germany	3	27
Italy	1	9
Spain	1	9
The Netherlands	3	27
<i>Total</i>	11	100

IRD, inherited retinal degeneration.

### *Involvement in Clinical Trials*

From the centers that manage and genetically test IRD patients themselves, 23% are currently involved in clinical studies with gene therapies for IRD, 5% were previously involved, 13% are not involved, and 59% are interested in getting involved, in clinical studies with gene therapies for IRD. Belgium, France, Germany, Italy, Spain, and The Netherlands have centers currently involved, or were previously involved in clinical studies with gene therapies for IRD (Tables 7, 8). Only 33% of these centers are/were the leading PI, and in 75% patients were enrolled during the clinical studies. The clinical study ILLUMINATE (for CEP290 mutation-associated IRD) (ClinicalTrials.gov Identifier: NCT03913143), and the post-authorization safety study with voretigene neparvovec (Luxturna<sup>®</sup>) are being performed in 25 and 17% of the centers that are currently involved in clinical studies with gene therapies for IRD, respectively (Table 9). LCA was addressed in 58% of the studies, followed by LHON (25%), choroideremia (17%), and retinitis pigmentosa (17%) (Table 10), whereas CEP290 was addressed in 50% of the studies, followed by RPE65 (42%) and RPGR (25%) (Table 11).

### **Discussion**

IRDs have an estimated overall prevalence rate of 1 in 3,000 [2, 11]. Although categorized as rare diseases, their impact on the lives of the patients as well for the society are enormous. A recent report from the UK and Ireland provides not only estimated prevalence data of IRDs in the 2 countries, but also elaborates on the high socioeconomic burden of IRDs [11]. For example, total costs at-

**Table 9.** Type of clinical study with gene therapies for IRD

	<i>n</i>	%
Natural history		
CEP290 (NCT03396042)	1	9
NIGHT (NCT03359551), STAR (NCT03496012), XOLARIS	1	9
Historical case record survey LHON (NCT02796274)	1	9
Premarketing clinical studies		
USHTher (NCT03814499)	1	9
Illuminate (NCT03913143)	3	27
Safety study of RPE65 gene therapy to treat LCA (NCT00643747)	2	18
Post-marketing		
Luxturna® (EUPAS31153)	2	18
LEROS (NCT02774005)	1	9
Multiple trials		
Multiple trials	3	27
<i>Total</i>	15	136*
<i>Total of centers currently or previously involved in clinical study(ies) with gene therapies for IRD</i>	11	100

LCA, Leber congenital amaurosis; LHON, Leber's hereditary optic neuropathy; IRD, inherited retinal degeneration. \* Multiple choices allowed.

**Table 10.** Retinal diseases addressed in clinical studies with gene therapies for IRD

	<i>n</i>	%
LHON	3	20
LCA	7	47
EOSRD	1	7
Choroideremia	2	13
Retinitis pigmentosa	2	13
Cone rod dystrophy	0	0
Achromatopsia	1	7
Stargardt disease	0	0
Usher syndrome	1	7
<i>Total</i>	17	113*
<i>Total of clinical studies</i>	15	100

LCA, Leber congenital amaurosis; LHON, Leber's hereditary optic neuropathy; EOSRD, Early-onset severe retinal dystrophy; IRD, inherited retinal degeneration. \* Multiple choices allowed.

**Table 11.** Gene addressed in clinical studies with gene therapies for IRD

	<i>n</i>	%
ABCA4	1	7
CHM	2	13
CEP290	6	40
CNGA3	2	13
CNGB3	1	7
MYO7A	2	13
RHO	0	0
RPGR	3	20
RPE65	5	33
Gene independent	2	13
mtDNA	1	7
<i>Total</i>	22	147*
<i>Total of clinical studies</i>	15	100

IRD, inherited retinal degeneration. \* Multiple choices allowed.

tributable to 10 IRDs in the Republic of Ireland were estimated to be £42.6 million in 2019, comprising economic (£28.8 million) and well-being costs (£13.8 million). Well-being costs were estimated using the WHO burden of disease methodology, a nonfinancial approach, where pain, suffering, and premature mortality are measured in terms of disability-adjusted-life-years. The overall prevalence of the 10 major IRDs was estimated to be from

0.0311 to 0.052% in Republic of Ireland, which accounts for about 1,500–2,500 cases in 2019. This translates to an annual cost per patient of £ 20,000 on average. Development of effective therapies for the most frequent forms in the future may alleviate this burden, although actual therapies are associated with high cost for the medication, yet with measurable gain in quality-adjusted life years [8, 10, 12]. The effect on disability-adjusted-life-years may be

significantly higher. Identifying patients that can be recruited for clinical trials is therefore very important. In Europe, no good prevalence data are available, yet a consortium was started already in 2008 (the European Retinal Disease Consortium), where 22 partners from Europe (17), Israel (3), Canada (1), and USA (1) work together [13]. Throughout the world, several new consortia have been established in recent years to collect data on IRDs. These are Japan Eye Genetics Consortium with 38 institutes since 2011 [14], East Asia Inherited Retinal Disease Society with 68 institutes from 5 countries (Japan, South Korea, China, Singapore, and Australia) since 2016 [15], and Global Eye Genetics Consortium with 20 countries and 150 researchers since 2014 and member of the ICO [16].

Our survey is the first to investigate in 101 EVICR.net centers throughout Europe, the prevalence and distribution of IRDs, diagnosis and management of IRDs, availability of genetic testing and genetic counseling, as well as actual involvement in clinical trials. The response rate to our survey was 49% that was similar to other surveys conducted among EVICR.net members. However, this response rate does not imply that the nonresponders are centers that do not manage many IRD cases, but could also reflect centers that are less motivated to complete the questionnaire.

We observed different response rates and answers by country (Fig. 1b). The survey results presented here were mostly driven by the responses from Spain, Germany, Italy, and Portugal (Fig. 1b). Moreover, the response rate by country was also dependent on the number of centers per country. In a country with 2 or 3 centers, we have a high response rate only because these centers are responsive. It is important to understand why response rates were low in specific countries, namely in France. One reason could be that they do not manage IRD patients or other centers in that country are dedicated IRD expert centers, and so they assumed that those would answer. Yet another reason could be a general lack of interest in surveys. One further reason could be that some centers are part of a recently established network on rare eye diseases, the European Reference Network for Rare Eye Diseases (ERN-Eye) [16] that also requires substantial work. In fact, 14% of EVICR.net centers are also members of ERN-Eye, and 16% of the EVICR.net centers that responded are members or ERN-EYE.

One interesting finding is that few centers manage high numbers of IRD patients: 31 centers manage between 50 and 1,000 IRD patients and only 8 centers manage >1,000 IRD patients. This result might also depend on

the interpretation of the word “currently” (Fig. 2; online suppl. Table 1). Another possible explanation is that IRD patients are distributed among several expert centers within each country and some of these centers did not complete the survey.

From the 86% of centers that indicated the current number of IRD patients they managed, only 17% refer IRD patients to expert centers. No centers indicated referral of IRD patients to ERN-EYE health care providers. Of the 14 EVICR.net centers that are also ERN-EYE members, only 8 replied to the survey (1 from France, 2 from Germany, 2 from Italy, 2 from The Netherlands, and 1 from Portugal). The ERN-EYE does not have representatives from all the EU countries and not all expert centers within countries are members of the ERN-EYE. Those centers who do not refer patients to ERN-EYE health-care providers either may not because they are expert centers themselves or are not familiar with the ERN-EYE. They may also not be aware that the centers to whom they refer their patients are ERN-EYE members.

The prevalence of IRDs starting in infancy is considerably lower than the prevalence of IRDs starting later in life, so it is expected that the vast majority of patients per center are adult patients, as observed in this survey. The problem is that LCA-type IRDs are much rarer than RP type IRDs. Taking all IRDs together, LCA type is only about 5%, so the likely answer is a later age. Even when children are diagnosed with IRDs, which is certainly the case for some centers, the majority of patients are diagnosed later in life. We have noticed that the majority of the diagnosed IRD cases in the participating centers in France occur mainly at preschool (Fig. 4). This could indicate that these centers are specialized in early onset retinal dystrophies. In addition, France has a specific network for rare diseases, where each center is in charge of a subset of IRDs. Some of these expert centers may not be EVICR.net members, or did not participate in the survey.

Given the overall number of patients listed as “actually followed” in the centers that did respond, it becomes clear that only a small percentage of patients with IRDs are currently followed. For example, in Germany with an overall population of about 83 million people, and given the estimated prevalence of 1:3,000 [2], the expected number of patients with IRDs is 27,670. As only estimated data were collected, it is not possible to give a precise percentage, but it could be in the order from 14% to about 22%. It was, however, on purpose that we asked only for estimated numbers in order to maximize the number of repliers.

Another interesting result was that the time from inquiring for an appointment and the appointment actually taking place differs significantly. Possible explanations are travel distances for patients to treatment centers or center-limited examination capacities to respond immediately to an examination request.

The time from appointment to final diagnosis including molecular genetic confirmation also differed significantly among countries. One reason is that local health policies, for example, private versus public health systems vary widely. The time can be as short as 4 weeks, but also as long as 10 years (online suppl. Fig. 4). However, the latter long-time interval very likely reflects the fact that only recently a more general access outside research has become available in some countries and that molecular genetic testing as a routine was started only recently. Most of the centers that manage IRDs, that is, 93%, order genetic testing. However, only 54% of the centers have at least 60% of the patients tested, and 5% of the centers do not provide access to genetic testing. The mutation detection rate is reported to be 40–80% (Table 4). The time to a molecular result varies widely and can be as long as 17 months (Fig. 9). A faster result would be desirable as patients are anxious to know their result as soon as possible. To note that no question was made to specify the time to get a result according to the type of test. Possibly the type of test performed in each center/country (for instance sequencing a single gene vs. WES/WGS) is the major factor influencing the time to get the final genetic result.

As only about half of centers have >50% of their IRD patients tested genetically, improvements in the availability of genetic testing should be attempted. Genetic counseling is provided by 92% of the centers that manage IRD patients which is very patient-oriented. Of note, in this survey no countries from Eastern Europe were included as they are not yet the members of EVICR.net. On the other hand, it is well known that genetic testing is less widely available in Eastern Europe for several reasons.

Genetic testing is most frequently done on clinical grades, which may miss the diagnosis. In case of a negative result, it would, however, be desirable to continue with research grade testing. Most centers use panel testing as a routine, where the number of genes per panel increase constantly. This will likely result in an even higher mutation detection rate and should encourage centers to repeat testing in previously unsolved IRD cases. This maybe challenging as patient databases will need constant reevaluation that is both time and money consuming. Yet, in order to verify older results and to increase the percentage of molecular genetic solved cases this is an im-

portant task. Nationwide electronic databases would be most helpful and should be established in an increasing number of countries.

A recent article summarizes state-of-the-art examinations of patients with IRD in view of existing and upcoming therapies [17]. The authors recommend visual acuity testing with ETDRS charts as a routine, which is not yet universal even in specialized centers. One reason could be that this test is rather time-consuming when it is accurately performed by a well-trained technician. In the present survey, ETDRS charts were used in 71% (Fig. 7). The use of other tests like TAC and Lea symbols reflects the different age-groups. The authors also recommend to use low luminance visual acuity testing that is performed by using 2.0 log unit neutral density filters while reading normally illuminated ETDRS charts that will reduce the luminance by 100 times. The low luminance deficit is then defined as the difference between low luminance visual acuity and the standard VA level in logMAR units. This test was not mentioned in our survey, and also not indicated by the repliers in the free text part. The test is certainly clinically relevant and centers involved in the management of IRD patients should consider this relatively simple test despite the additional examination time. The authors also mention the multiple luminance mobility test and FST. In our survey we did not ask specifically for the multiple luminance mobility test that to date is only available in few centers and even more time-consuming, but we did ask for the FST. The FST may not yet been applied as a routine test but is available in 93% of centers that manage IRD patients themselves (Fig. 6). The authors conclude that both tests are not essential for routine testing, as it might be difficult to adopt them universally. Our results indicate that at least FST is already widely available in the centers that manage IRD patients. Of note, perimetry is always included in the workup, but fundus-controlled perimetry that is also considered state-of-the-art, is only used in 21% of the centers that manage IRD patients (Table 2 and online suppl. Table 3a–c). Analysis of retinal stratification by OCT and FAF are widely used tests as well as ERG with standardized protocols.

Several factors complicated the analysis of our data. Sometimes questions were not optimal, thus leading to ambiguous answers or absence of answer. For instance, only in 52% of the cases (22/42) the question 6 in section 1, in which a percentage of the IRD patient's signs/symptoms implicating a visit was requested, was correctly replied. From that, 6 did not reply. As we tried to make the survey as quick to answer as possible, we had to include a

significant number of questions with multiple choices that are difficult to analyze in a quantitative way. In addition, we included in some instances space for free text to give the possibility to add aspects that we might have forgotten to include in the survey. In fact, 59 questions had space for free text. Most of the space for free text was in the format of “Other” and “Please specify,” in order to give the opportunity to the centers to reply with a different option than the presented ones. In other cases, options instead of free text space might have provided more clear answers. For instance, section 4 about the Involvement in Clinical Trials has 2 questions about the name of the studies and NCT number (the latter was only replied in 50% of the cases). This was difficult to analyze. A brief literature review prior to the survey might have been useful to have the options with the name and the NCT numbers of the clinical studies with gene therapies for IRD.

#### *Our Survey Has Several Strengths*

An expert committee on IRDs developed a thorough questionnaire based on the practices and experiences in the IRD centers from where the members of the expert committee have been based for many years. The survey used the EVICR.net, which currently has 101 members with certified SOPs, hence comparable data collection.

The survey provides detailed knowledge on the devices and tests used for the management of IRDs in a significant number of EVICR.net centers managing patients with IRDs (42 centers). The survey provides an overview of the availability and application of molecular genetic testing in the responding European centers that manage IRDs. The difference in time from clinical diagnosis to molecular genetic testing likely reflects a historical phenomenon, that is, the different start of molecular genetic testing as a generally available tool paid for by health insurances (Table 6).

#### *Limitations of Our Study*

Not all European university centers and other major ophthalmic care centers are members of EVICR.net. For example, given the response rate of EVICR.net member centers in Germany, only data from 16/35 university departments and 1/65 non-university hospitals with eye departments are available. Hence, no conclusions as to the true prevalence of IRDs per nation can be drawn.

The response rate was 49% on average and in line with response rates of other surveys, hence quite realistic. On the other hand, it varied widely from 0% to 100% in different countries (Fig. 1b). One reason for the varying response rate could be the number of questions (112) that

we considered necessary to obtain information beyond what was previously known. Future surveys should also avoid the factors mentioned before complicating quantitative analysis of the data collected.

## **Conclusion**

This first European Survey on the Management of IRDs provides important baseline information on local and national differences in diagnosing and managing affected IRD patients and their families. The EVICR.net provided a unique platform to collect the data. These baseline data, previously not explored on such a scale, are of great importance to researchers, policy makers, clinicians, patient advocate groups and others to inform, and improve bottlenecks in the provision of optimal care for patients and families affected with IRDs, and in preparation of a fast-emerging era of ocular gene therapy. Patient registries such as the My-Retina-Tracker<sup>®</sup>-Registry initiated by the Foundation Fighting Blindness in 2014 and consisting of 2 very extensive questionnaires, 1 for the patient and 1 for the treating physician (<https://www.fightingblindness.org/my-retina-tracker-registry>), or the patient registry initiated by Pro Retina Germany (<https://www.pro-retina.de/patientenregister>) may want to make use of this data.

The limited number of EVICR.net member centers in general, and of participating centers in particular, hampers the robustness of the collected data. The basic clinical workup in the centers that manage IRD patients is similar; tests that are more specific are not universally in use. Coverage of molecular genetic testing is still limited and should be increased. National databases, already in use in some countries, should be encouraged and supported and will help identify and provide patients eligible for actual and upcoming treatment modalities.

## **Acknowledgements**

We thank Dr. Sue Lacey, PhD (former Novartis employee), for providing valuable comments in the design and content of the IRD questionnaire, as well as to the results report. We thank Dr. Isabelle Audo, MD PhD (CHNO of Quinze-Vingts, Paris, France), for reviewing the first draft of the survey. We also thank Markus Preisling, PhD (Dept. of Ophthalmology, Justus-Liebig-University Gießen, Germany), who helped with the format and contents of the first draft of the survey. We thank the Novartis team for the final review of this manuscript and for providing valuable scientific and editorial comments.

## Statement of Ethics

This survey was reviewed and approved by the AIBILI Ethics Committee – Comissão de Ética para a Saúde prior to its dissemination to the 101 EVICR.net clinical centers members and was in accordance with the World Medical Association Declaration of Helsinki. As no personal data were collected, the use of a written and informed consent form was not applicable.

## Conflict of Interest Statement

The authors have no conflicts of interest to declare.

## References

- 1 Daiger SP. RetNet [Internet]. *RetNet Summ Genes Loci Causing Retin Dis*. 2020 Apr 27. Available from: <https://sph.uth.edu/retnet/sum-dis.htm>.
- 2 Khan M, Cornelis SS, Khan MI, Elmelik D, Manders E, Bakker S, et al. Cost-effective molecular inversion probe-based ABCA4 sequencing reveals deep-intronic variants in stargardt disease. *Hum Mutat*. 2019 Oct; 40(10):1749–59.
- 3 Russell S, Bennett J, Wellman JA, Chung DC, Yu Z-F, Tillman A, et al. Efficacy and safety of voretigene neparvovec (AAV2-hRPE65v2) in patients with RPE65-mediated inherited retinal dystrophy: a randomised, controlled, open-label, phase 3 trial. *Lancet*. 2017 Aug; 390(10097):849–60.
- 4 Gill JS, Georgiou M, Kalitzeos A, Moore AT, Michaelides M. Progressive cone and cone-rod dystrophies: clinical features, molecular genetics and prospects for therapy. *Br J Ophthalmol*. 2019 May;103(5):711–20.
- 5 Maloney DM, Chadderton N, Palfi A, Millington-Ward S, Farrar GJ. Retinal bioenergetics: new insights for therapeutics. In: Rickman CB, Grimm C, Anderson RE, Ash JD, LaVail MM, Hollyfield JG, editors. *Retinal degenerative diseases*. Cham: Springer; 2019. Vol. 1185. p. 275–9. [Biol](#)
- 6 Chung DC, Bertelsen M, Lorenz B, Pennesi ME, Leroy BP, Hamel CP, et al. The natural history of inherited retinal dystrophy due to biallelic mutations in the RPE65 gene. *Am J Ophthalmol*. 2019 Mar;199:58–70.
- 7 Bennett J, Wellman J, Marshall KA, McCague S, Ashtari M, DiStefano-Pappas J, et al. Safety and durability of effect of contralateral-eye administration of AAV2 gene therapy in patients with childhood-onset blindness caused by RPE65 mutations: a follow-on phase 1 trial. *Lancet*. 2016 Aug;388(10045):661–72.
- 8 Johnson S, Buessing M, O'Connell T, Pitluck S, Ciulla TA. Cost-effectiveness of voretigene neparvovec-rzyl versus standard care for RPE65-mediated inherited retinal disease. *JAMA Ophthalmol*. 2019 Oct;137(10):1115.
- 9 Zimmermann M, Lubinga SJ, Banken R, Rind D, Cramer G, Synnott PG, et al. Cost utility of voretigene neparvovec for biallelic RPE65-mediated inherited retinal disease. *Value in Health*. 2019 Feb;22(2):161–7.
- 10 Viriato D, Bennett N, Sidhu R, Hancock E, Lomax H, Trueman D, et al. An economic evaluation of voretigene neparvovec for the treatment of biallelic RPE65-mediated inherited retinal dystrophies in the UK. *Adv Ther*. 2020 Mar;37(3):1233–47.
- 11 Galvin O, Chi G, Brady L, Hippert C, Del Valle Rubido M, Daly A, et al. The impact of inherited retinal diseases in the republic of Ireland (ROI) and the United Kingdom (UK) from a cost-of-illness perspective. *Clin Ophthalmol*. 2020 Mar;14:707–19.
- 12 Uhrmann MF, Lorenz B, Gissel C. Cost effectiveness of voretigene neparvovec for RPE65-mediated inherited retinal degeneration in Germany. *Transl Vis Sci Technol*. 2020 Aug; 9(9):17.
- 13 European Retinal Disease Consortium [Internet]. ERDC. [cited 2020 May 12]. Available from: <https://www.ercd.info/>
- 14 Japan Eye Genetics Consortium [Internet]. JEGC. [cited 2020 May 12]. Available from: <http://www.jegc.org/>
- 15 East Asia Inherited Retinal Disease Society [Internet]. EAIRDS. [cited 2020 Nov 23]. Available from: <https://www.eairds.org/>
- 16 Global Eye Genetics Consortium [Internet]. GEGC. [cited 2020 May 12]. Available from: <http://gegco.org/>
- 17 Menghini M, Cehajic-Kapetanovic J, MacLaren RE. Monitoring progression of retinitis pigmentosa: current recommendations and recent advances. *Expert Opin Orphan Drugs*. 2020 Mar;8(2–3):67–78.

## Funding Sources

This study was funded by Novartis Pharma AG through a Scientific Collaboration Agreement between Novartis and AIBILI and the Coordinating Center of EVICR.net. Novartis provided non-binding comment/input to the IRD Survey Expert Committee into all elements of the scientific collaboration agreement.

## Author Contributions

The IRD questionnaire was designed by B.L., J.T., L.I.B., J.P.M., and H.P.N.S. J.T., and B.L. analyzed the data. B.L. and J.T. wrote the manuscript. L.I.B., J.P.M., and H.P.N.S. reviewed and complemented the manuscript. B.L., J.T., L.I.B., J.P.M., and H.P.N.S. approved the final manuscript.





ANNEX II

**9.2. Current Management of Patients with *RPE65* Mutation-Associated Inherited Retinal Degenerations in Europe: Results of a Multinational Survey by the European Vision Institute Clinical Research Network**

Lorenz B, Tavares J, van den Born LI, Marques JP, Scholl HPN, EVICR.net Group  
Ophthalmic Res. 2021;64(5):740-753.



# Current Management of Patients with *RPE65* Mutation-Associated Inherited Retinal Degenerations in Europe: Results of a Multinational Survey by the European Vision Institute Clinical Research Network

Birgit Lorenz<sup>a, b</sup> Joana Tavares<sup>c</sup> L. Ingeborgh van den Born<sup>d</sup>  
João P. Marques<sup>e, f, g</sup> Hendrik P.N. Scholl<sup>h, i, j</sup> The EVICR.net Group

<sup>a</sup>Department of Ophthalmology, Justus-Liebig-University Giessen, Giessen, Germany; <sup>b</sup>Department of Ophthalmology, University Hospital Bonn, Bonn, Germany; <sup>c</sup>Association for Innovation and Biomedical Research on Light and Image (AIBILI), Coimbra, Portugal; <sup>d</sup>Rotterdam Eye Hospital and Rotterdam Ophthalmic Institute, Rotterdam, The Netherlands; <sup>e</sup>Center for Clinical Trials, Association for Innovation and Biomedical Research on Light and Image (AIBILI), Coimbra, Portugal; <sup>f</sup>Department of Ophthalmology, Centro Hospitalar e Universitário de Coimbra (CHUC), Coimbra, Portugal; <sup>g</sup>Faculty of Medicine, University of Coimbra (FMUC), Coimbra, Portugal; <sup>h</sup>Institute of Molecular and Clinical Ophthalmology Basel (IOB), Basel, Switzerland; <sup>i</sup>Department of Ophthalmology, University of Basel, Basel, Switzerland; <sup>j</sup>Wilmer Eye Institute, Johns Hopkins University, Baltimore, MD, USA

## Keywords

Inherited retinal degenerations · *RPE65* · Management · Europe · European Vision Institute Clinical Research Network clinical centers

## Abstract

**Purpose:** The first ocular gene augmentation therapy, voretigene neparvovec (VN) (Luxturna<sup>®</sup>), has been approved for clinical use in an increasing number of countries (FDA USA 2017, EMA Europe 2018, MoHAP United Arab Emirates 2019, SFDA Saudi Arabia 2019, Swiss Medic Switzerland 2020, TGA Australia 2020, BFR Brazil 2020). Among the EVICR.net clinical centers, we conducted the first multinational survey to understand distribution, diagnostic work-up, and manage-

ment of inherited retinal degeneration (IRD) cases in Europe with a special focus on *RPE65* mutation-associated IRDs. **Methods:** An electronic survey questionnaire including 35 questions specifically addressing *RPE65* mutation-associated IRDs was developed and sent to the 101 EVICR.net clinical centers. **Results:** The overall response rate was 49%. Forty-two centers see IRD patients, and 22/42 follow patients with confirmed biallelic *RPE65* mutations. Fifteen of the 22 centers (68%) and 3/22 (14%) follow 1–5 and 6–10 patients with homozygous *RPE65* mutations, respectively. Additionally, 15/22 (68%) and 3/22 (14%) follow 1–5 and >20 patients with compound heterozygous *RPE65* mutations, respectively. Fif-

Birgit Lorenz and Joana Tavares contributed equally.

ty-nine percent of mutations were ACMG Class 4 and 5 (at least 1 allele), 82.8% reported previously and 17.2% novel. Referral diagnoses (the mean per center) were Leber congenital amaurosis (38.2%), early-onset severe retinal degeneration (16.8%), rod-cone-dystrophy/retinitis pigmentosa (RP) (28.1%), and unclassified visual impairment (17.0%). Twenty-five percent of the centers changed the referral diagnosis in >47.5% of cases; 32% follow a specific referral process for *RPE65* mutation-associated IRD patients. Annual follow-up visits are done in 55% of the centers and biannual visits in 23%. In 32%, other centers also follow the patients. Kinetic perimetry is done in 82%, static perimetry in 45%, and microperimetry in 18% of the centers. Full-field light stimulus threshold testing with blue and red stimuli to quantify the rod and cone function is used in 6/22 centers (27%). A mobility course is available in one center (5%). **Conclusion:** This first multinational survey on management of patients with *RPE65* mutation-associated IRDs in Europe shows that about half of the responding EVICR.net centers have such patients under care. There is heterogeneity in diagnoses and management practices. At the start of clinical practice experience with VN, these data provide a useful baseline and highlight the need for consensus/guidelines to inform standard of care in this new era of gene therapy.

© 2021 The Author(s)  
Published by S. Karger AG, Basel

## Introduction

*RPE65* mutation-associated inherited retinal degenerations (IRDs) are of great interest as an approved therapy is now available in an increasing number of countries worldwide (FDA USA 2017, EMA Europe 2018, MoHAP United Arab Emirates 2019, SFDA Saudi Arabia 2019, Swiss Medic Switzerland 2020, TGA Australia 2020, BFR Brazil 2020). Cost-effectiveness of this therapy for the national health-care system is actually discussed in a number of articles [1–5]. The gene was identified by 2 groups independently in 1997 [6, 7], and while Marlhens et al. [6] reported mutations in patients with autosomal recessive Leber congenital amaurosis, Gu et al. [7] had found mutations in patients with autosomal recessive childhood-onset severe retinal dystrophy. Recent reports have described a yet wider range of diagnoses [8–12], which has important implications as to the population that should be screened for biallelic mutations in *RPE65*.

The aim of this study is to specifically report and analyze in detail diagnosis and management of *RPE65* mutation-associated IRDs [8, 13, 14] across Europe. The

EVICR.net retinal dystrophies Expert Committee conducted an electronic survey questionnaire aimed to understand the current management of IRD cases across the 101 EVICR.net clinical centers [15]. We complemented the general survey by 35 additional questions specifically related to *RPE65* mutation-associated IRDs. The survey gives important insights into the epidemiology of *RPE65* mutation-associated IRDs and the range of clinical diagnoses in a number of patients eventually amenable to therapy. Increased awareness for the range of first diagnoses of *RPE65* mutation-associated IRDs will help identify more patients that might benefit from therapy. It will also further improve our understanding of the disease course in relation to the underlying mutations, since some exceptional patients have a slower progression than others [11]. These observations are important to decide on the best time point in the disease course for gene augmentation therapy, since the optimal window for successful treatment remains yet to be identified. The typically used readout parameters are still not optimal to identify cells that can be salvaged by the intervention [16]. In treated 5- to 6-year-old dogs with biallelic *RPE65* mutations, during an observation period of 4–5 years, areas with >63% of retained photoreceptors at the time of treatment showed robust retention of photoreceptors, whereas areas with less retained photoreceptors showed continuous degeneration similar to what had been reported earlier [17]. An unexpected finding was that both treated and untreated regions in study eyes tended to have less degeneration compared to matched locations in untreated control eyes. Although animal data cannot be strictly compared to the human phenotype, the findings do open new aspects on when and where to treat and underline the need of identifying as many patients with *RPE65* mutation-associated IRDs as possible to answer such questions. *RPE65* mutation-associated IRDs are a rare form of IRD with an estimated prevalence of about 1 in 300,000 [1, 18]. Given the overall population of Europe of 747,700,446 as of Friday, August 21, 2020, based on the latest United Nations estimates, we can expect about 2,500 patients with biallelic mutations in *RPE65* in Europe. As many of the patients are blind by the end of the third or fourth decade of life [8, 12, 19], the number of patients who might benefit from gene supplementation therapy is likely much lower. Early diagnosis is important to investigate treatment potential at early stages of the disease, aiming not only to improve and preserve the rod function, but also to improve and maintain the cone function.

**Table 1.** Estimate number of IRD patients with confirmed homozygous and compound heterozygous mutations in *RPE65*

	Homozygous mutations			Compound heterozygous mutations		
	<i>n</i>	%	min/max	<i>n</i>	%	min/max
0	2	9	0/0	2	9	0/0
1–5	15	68	15/75	15	68	15/75
6–10	3	14	18/30	0	0	0/0
11–20	1	5	11/20	1	5	11/20
>20	1	5	21/30 <sup>a</sup>	3	14	63/90 <sup>a</sup>
Do not know	0	0	0/0	1	5	1/2 <sup>b</sup>
<b>Total</b>	<b>22</b>	<b>100</b>	<b>65/155</b>	<b>22</b>	<b>100</b>	<b>90/187</b>
Total of centers with <i>RPE65</i> mutation-associated IRD patients	22	100	–	22	100	–

*N* refers to the number of centers. IRD, inherited retinal degeneration. <sup>a</sup> Estimated number assuming 30 patients as maximum for centers with >20 patients. <sup>b</sup> Estimated number assuming 2 patients as maximum for centers answering do not know.

## Materials and Methods

### Study Design

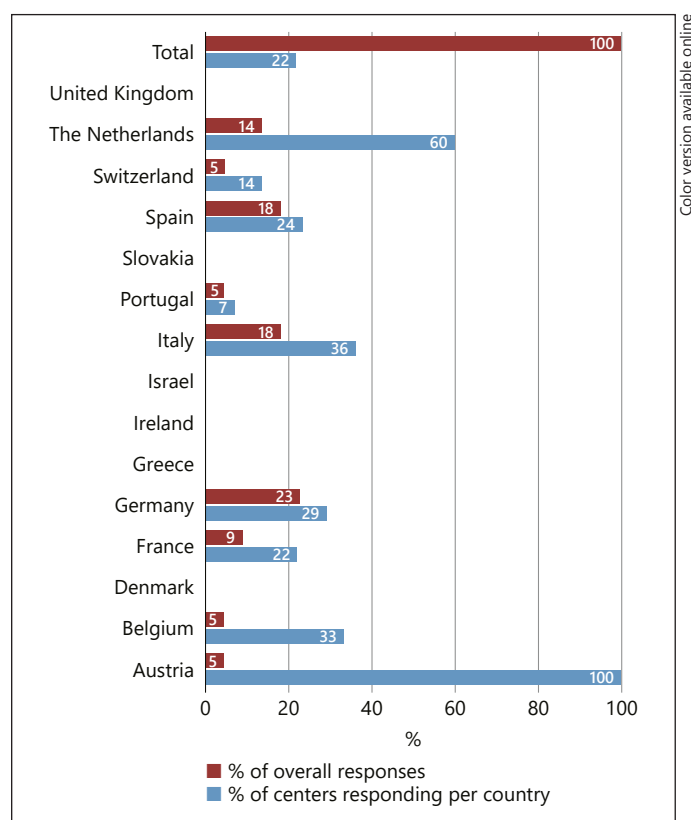
We carried out a cross-sectional study among ophthalmic clinical centers with an EVICR.net membership from 14 European countries (CH, DE, FR, IT, UK, SP, DK, AU, BE, GR, IL, NL, PT, and SK) and Israel. In May 2019, all EVICR.net clinical centers were invited by e-mail to complete the online questionnaire. This invitation was sent to the responsible person of the clinical center and also to its representative for the EVICR.net Retinal Dystrophies Scientific Section; however, no restrictions were imposed to participate in the survey (shared via public link). Therefore, any member of the clinical center staff (e.g., medical retina ophthalmologist, general ophthalmologist, pediatric ophthalmologist, and other) could have replied to the survey on their behalf. Only one reply per clinical center was considered.

A reminder was sent to the non-repliers after 2 weeks, the deadline was extended for 2 more weeks, and new reminders were sent on week 3 and week 4 (2 days before deadline). Several strategies were applied to increase the response rate, namely, follow-up contact, hard copy of the questionnaire, personalized e-mails, and giving a deadline.

### Questionnaire

An IRD Expert Committee developed the IRD survey questionnaire. This Committee members were Birgit Lorenz, MD PhD, Germany (Scientific Coordinator); Hendrik Scholl, MD PhD, Switzerland; Isabelle Audo, MD PhD, France; Ingeborgh van den Born, MD PhD, the Netherlands; and João Pedro Marques, MD, Portugal.

The questionnaire was divided in 5 sections: section 1: IRD demographics, section 2: local setting, section 3: IRD genetic testing and counselling, section 4: involvement in clinical trials, and section 5: *RPE65* mutation-associated IRDs. The results from sections 1 to 4 have been reported separately [15]. Here, we present the results from section 5. Section 5 comprised 35 questions that followed a conditional branching (see online suppl. material – online questionnaire; see [www.karger.com/doi/10.1159/000515688](http://www.karger.com/doi/10.1159/000515688) for all online suppl. material). The questionnaire was designed to



**Fig. 1.** Centers that reported to have IRD patients with confirmed biallelic mutations in *RPE65* identified in their centers by country. IRD, inherited retinal degeneration.

have mostly multiple-choice questions and single choice questions (closed-ended items), in which the options represent a range of values, which means that only estimates were requested. Due to the low number of patients with *RPE65* biallelic mutations, we decided

**Table 2.** Estimate number of IRD patients with confirmed biallelic mutations in *RPE65* distributed by country

Country	N	Total centers at section 5 per country	% per country	Min/max
<i>Homozygous mutations in RPE65</i>				
<b>Total</b>	22	22	–	65/155
0				
Austria	1	1	100	0/0
Germany	1	5	20	0/0
Total	2	–	–	0/0
1–5				
Belgium	1	1	100	1/5
France	2	2	100	2/10
Germany	2	5	40	2/10
Italy	3	4	75	3/15
Portugal	1	1	100	1/5
Spain	3	4	75	3/15
Switzerland	1	1	100	1/5
The Netherlands	2	3	67	2/10
Total	15	–	–	15/75
6–10				
Germany	2	5	40	12/20
Italy	1	4	25	6/10
Total	3	–	–	18/30
11–20				
The Netherlands	1	3	33	11/20
Total	1	–	–	11/20
>20				
Spain	1	4	25	21/30 <sup>a</sup>
Total	1	–	–	21/30
<i>Compound heterozygous mutations in RPE65</i>				
<b>Total</b>	22	22	–	90/187
0				
Germany	1	5	20	0/0
Italy	1	4	25	0/0
Total	2	–	–	0/0
1–5				
Austria	1	1	100	1/5
Belgium	1	1	100	1/5
France	2	2	100	2/10
Germany	2	5	40	2/10
Italy	3	4	75	3/15
Portugal	1	1	100	1/5
Spain	2	4	50	2/10
Switzerland	1	1	100	1/5
The Netherlands	2	3	67	2/10
Total	15	–	–	15/75
11–20				
Germany	1	5	20	11/20
Total	1	–	–	11/20
>20				
Germany	1	5	20	21/30 <sup>a</sup>
Spain	1	4	25	21/30 <sup>a</sup>
The Netherlands	1	3	33	21/30 <sup>a</sup>
Total	3	–	–	63/90
Do not know				
Spain	1	4	25	1/2 <sup>b</sup>
Total	1	–	–	1/2

The percentage of centers per country was calculated based on the total number of centers that replied for each country. *N* refers to the number of centers. IRD, inherited retinal degeneration. <sup>a</sup> Estimated number assuming 30 patients as maximum for centers with >20 patients. <sup>b</sup> Estimated number assuming 2 patients as maximum for centers answering do not know.

to only ask for estimated numbers in order to respect patient's confidentiality. It is important to recognize that not all variants in genes were disease-causing. An actual classification comprises at least 5 major types of mutations, that is, (1) pathogenic, (2) likely pathogenic, (3) uncertain significance, (4) likely benign, and (5) benign [20]. Likely pathogenic corresponds to class 4 and pathogenic to class 5. Only class 4 and 5 mutations are considered to be clearly disease-causing, hence a genotype, where gene supplementation therapy with voretigene neparvovec (VN) is indicated [21]. Classification of missense mutations as pathogenic or likely pathogenic, that is, class 4 or 5, can be challenging but is mandatory prior to treatment [20]. Previously unclassified mutations may be definitely identified as disease-causing with additional investigations such as segregation of the mutation in the family [22], or by testing the enzymatic activity of the mutant [9, 23]. We, therefore, asked specifically for the estimated number of patients with biallelic class 4 and 5 mutations.

The identification of the EVICR.net member and name, function and contacts (e-mail and telephone) of the replier were requested as they are all EVICR.net members with a Confidentiality Disclosure Agreement in place.

#### Statistical Analysis

We conducted a descriptive analysis to all variables that was the same as recently reported for the general IRD survey [15]. Continuous variables were summarized using the following statistics: number (*n*), mean, standard deviation (SD), median (P50), first and third quartiles (P25 and P75), minimum (Min), and maximum (Max). The frequency and percentages of observed levels were reported for all categorical measures. Statistical analyses were performed with Excel version 15.0.4433.1508 (Microsoft Office Home and Business 2013) and R version 3.6.0 (2019-04-26). We did not exclude questionnaires due to missing values. However, each analysis was restricted to repliers with no missing values for the respective question (i.e., total number of repliers differed between questions).

## Results

### Demographics of RPE65 Mutation-Associated IRDs in 22 EVICR.net Centers

The IRD survey was sent to 101 EVICR.net clinical research centers from 14 European countries and Israel [15]. Forty-nine percent of the 101 EVICR.net clinical research centers (49 centers) in 15 countries who had received the online survey responded. However, only 22 EVICR.net clinical centers have IRD patients with confirmed biallelic mutations in *RPE65* identified in their centers (Fig. 1). The Netherlands reported the highest percentage of centers with patients with *RPE65* mutation-associated IRDs, that is, 60%, except for Austria with only 1 center as EVICR.net member (100% of centers). Sixty-eight percent of the centers have only 1–5 IRD patients with confirmed homozygous mutations in *RPE65* as well as only 1–5 IRD patients with confirmed compound het-

**Table 3.** Estimate of the number of IRD patients with confirmed biallelic mutations in *RPE65* according to ACMG class 4 or 5

	N	%	Min/max
0	2	9	0/0
1–5	11	50	11/55
6–10	0	0	0/0
11–20	0	0	0/0
>20	2	9	42/60 <sup>a</sup>
Do not know	7	32	7/14 <sup>b</sup>
<b>Total</b>	<b>22</b>	<b>100</b>	<b>60/129</b>
<b>Total of centers with <i>RPE65</i> mutation-associated IRD patients</b>			
	22	100	–

*N* refers to the number of centers. IRD, inherited retinal degeneration. <sup>a</sup>Estimated number assuming 30 patients as maximum for centers with >20 patients. <sup>b</sup>Estimated number assuming 2 patients as maximum for centers answering do not know.

**Table 4.** Estimate of the number of IRD patients with confirmed biallelic mutations in *RPE65* currently observed

	N	%	Min/max
0	1	5	0/0
1–5	14	64	14/70
6–10	3	14	18/30
11–20	0	0	0/0
>20	3	14	63/90 <sup>a</sup>
Do not know	1	5	1/2 <sup>b</sup>
<b>Total</b>	<b>22</b>	<b>100</b>	<b>96/192</b>
<b>Total of centers with <i>RPE65</i> mutation-associated IRD patients</b>			
	22	100	–

*N* refers to the number of centers. IRD, inherited retinal degeneration. <sup>a</sup>Estimated number assuming 30 patients as maximum for centers with >20 patients. <sup>b</sup>Estimated number assuming 2 patients as maximum for centers answering do not know.

erozygous mutations in *RPE65* (Table 1). Table 2 shows the number of centers with confirmed homozygous and compound heterozygous mutations in *RPE65* per country and the estimated minimum and maximum number of patients.

The estimated number of IRD patients with confirmed biallelic mutations according to American College of Medical Genetics (ACMG) class 4 or 5 that have been identified per center was 0 in 9% of the centers, 1–5 in 50, and >20 in 9% of the centers (Table 3). The estimated number of IRD patients with confirmed biallelic

**Table 5.** Frequency to recall the patients for follow-up by country

Country	N	%	Total centers at section 5 per country	% per country
Every 6 months				
France	1	–	2	50
Italy	2	–	4	50
Portugal	1	–	1	100
Spain	1	–	4	25
Total	5	23	–	–
Annually				
Austria	1	–	1	100
Belgium	1	–	1	100
France	1	–	2	50
Germany	2	–	5	40
Italy	2	–	4	50
Spain	3	–	4	75
Switzerland	1	–	1	100
The Netherlands	1	–	3	33
Total	12	55	–	–
Biennially				
Germany	2	–	5	40
The Netherlands	2	–	3	67
Total	4	18	–	–
Longer				
Total	0	0	–	–
Do not know				
Total	0	0	–	–
Other: age-dependent semiannually to biannually				
Germany	1	–	5	20
Total	1	5	–	–
Total	22	100	–	–
Total of centers with <i>RPE65</i> mutation-associated IRD patients				
	22	100	–	–

The percentage of centers per country was calculated based on the total number of centers that replied for each country. *N* refers to the number of centers. IRD, inherited retinal degeneration.

mutations currently followed per center is 0 in 5% of the centers, 1–5 in 64, 6–10 in 14, and >20 in 14% of the centers (Table 4). The mean number of patients per center was 6.6; however, 25% of the centers identified >7 patients (maximum >20). Tables 3 and 4 also indicate the estimated overall minimum and maximum number of patients.

From the identified *RPE65* mutations, 82.8% were already reported mutations and 17.2% were novel mutations. Patients with biallelic *RPE65* mutation-associated IRD had as referral diagnosis: early-onset severe retinal dystrophy (EOSRD) in 16.8%, Leber congenital amaurosis (LCA) in 38.2%, retinitis pigmentosa (RP)/rod-cone dystrophy in 28.1%, and unclassified visual impairment

in 17.0% of the cases (the mean per center). The mean percentage of centers that changed the referral diagnosis of *RPE65* mutation-associated IRD patients was 30, and 25% of the centers changed the referral diagnosis in >47.5% of the cases. Only 32% of the centers follow a specific referral process for *RPE65* mutation-associated IRD patients. Online suppl. Table 1 shows the number of centers that follow a specific referral process per country.

#### Follow-Up Visits

##### Actual Practice

Fifty-five percent of the centers recall patients every year, 23% every 6 months, and 18% every 2 years (Table 5). The frequency of follow-up visits for *RPE65* mu-



**Table 6.** Frequency that centers perform VA testing in *RPE65* mutation-associated IRD patients

	N	%
Monthly	0	0
Quarterly	0	0
Twice a year	7	32
Annually	10	45
Biennially	4	18
Longer	0	0
Other: with every visit	1	5
Total	22	100
Total of centers with <i>RPE65</i> mutation-associated IRD patients	22	100

N refers to the number of centers. IRD, inherited retinal degeneration; VA, visual acuity.

tation-associated IRD patients is only every 2 years in 40% of the centers in Germany and in 67% of the centers in the Netherlands (Table 5). On the other hand, the highest frequency of follow-up visits of every 6 months was reported in France, Italy, Portugal, and Spain (Table 5). Thirty-two percent of the centers replied that another institution also follows the *RPE65* mutation-associated IRD patients.

#### Previous Practice

In the past, 59% of the centers saw patients every year, 14% every 6 months, 14% every 2 years, and 5% longer (online suppl. Table 2). The time between visits for IRD patients in the past varied significantly in Germany and was mostly biennially in the Netherlands (online suppl. Table 2). On the other hand, the shortest mean time between visits in the past was every 6 months reported in Italy and Spain (online suppl. Table 2).

#### Psychophysics

##### Visual Acuity and Color Vision Testing

Visual acuity (VA) is tested in 45% of the 22 centers in *RPE65* mutation-associated IRD patients every year, 32% every 6 months, and 18% every 2 years (Table 6). The methods applied for VA testing in *RPE65* mutation-associated IRD patients in the 22 centers are particularly ETDRS charts (59%), Snellen charts (59%), Number charts (41%), and Lea Symbols® (32%) (Table 7). The methods applied for color vision testing in *RPE65* mutation-associated IRD patients in the centers are particularly Farnsworth Panel D15 (68%) and Ishihara plates (55%).

**Table 7.** Methods applied for VA testing in *RPE65* mutation-associated IRD patients

	N	%
ETDRS charts	13	59
Snellen charts	13	59
Number charts	9	41
Landolt rings	4	18
Tumbling "E" charts	5	23
BRVT	2	9
Teller acuity cards	5	23
Lea symbols®	7	32
HOTV	1	5
Total	59	268 <sup>a</sup>
Total of centers with <i>RPE65</i> mutation-associated IRD patients	22	100

N refers to the number of centers. IRD, inherited retinal degeneration; VA, visual acuity; BRVT, Berkeley rudimentary vision test. <sup>a</sup> Multiple choices allowed.

**Table 8.** VF tests performed in *RPE65* mutation-associated IRD patients

	N	%
Static perimetry	10	45
Kinetic perimetry	18	82
Fundus-controlled perimetry	4	18
Total	32	145 <sup>a</sup>
Total of centers with <i>RPE65</i> mutation-associated IRD patients	22	100

N refers to the number of centers. IRD, inherited retinal degeneration; VF, visual field. For detailed information of the specific devices used, see online suppl. Table 3a–e. <sup>a</sup> Multiple choice allowed.

#### Visual Field Testing

Visual field (VF) testing results are listed in Table 8 and online suppl. Table 3a–e. Centers that manage *RPE65* mutation-associated IRD patients mainly use kinetic perimetry (82%) and static perimetry (45%) (Table 8). For static perimetry, all centers use Humphrey® (Carl Zeiss Meditec AG, Jena, Germany) (online suppl. Table 3a) and models of Octopus (Haag-Streit AG, Koeniz, Switzerland) used are shown in online suppl. Table 3b. Of the centers, 83% use Goldmann (manual) for kinetic perimetry (online suppl. Table 3c) and the models of Octopus (Haag-Streit AG, Koeniz, Switzerland) used are shown in

**Table 9.** Number of VF tests (static or kinetic) performed per each *RPE65* mutation-associated IRD patient

	Static		Kinetic	
	<i>n</i>	%	<i>n</i>	%
<5	15	68	14	64
5–10	4	18	5	23
11–20	1	5	2	9
>20	0	0	0	0
Do not know	2	9	1	5
Total	22	100	22	100
Total of centers with <i>RPE65</i> mutation-associated IRD patients	22	100	22	100

*n* refers to the number of centers. IRD, inherited retinal degeneration; VF, visual field.

**Table 10.** Centers performing FST in *RPE65* mutation-associated IRD patients

	<i>N</i>	%
Yes	8	36
Blue, red, white testing	6	–
White testing only	2	–
No	14	64
Total	22	100
Total of centers with <i>RPE65</i> mutation-associated IRD patients	22	100

*N* refers to the number of centers. FST, full-field stimulus testing; IRD, inherited retinal degeneration.

online suppl. Table 3d. For fundus-controlled perimetry, 75% of the centers use MP3 (NIDEK Co. Ltd., Aichi, Japan) (online suppl. Table 3e).

The number of VF tests (static) that each center performs per each *RPE65* mutation-associated IRD patient was <5 in 68% of the centers, 5–10 in 18, and 11–20 in 5% (Table 9). The number of VF tests (kinetic) that each center performs per each *RPE65* mutation-associated IRD patient was <5 in 64% of the centers, 5–10 in 23, and 11–20 in 9% (Table 9).

#### *Two-Color-Threshold Perimetry and Full-Field Stimulus Threshold*

Only 9% of the 22 centers that manage *RPE65* mutation-associated IRD patients perform Two-Color-Threshold perimetry (2 CT-perimetry), and 36% of the 22 centers perform Full-Field Stimulus Testing (FST) in IRD patients (Table 10). From those centers, 75% performs

red, blue, and white testing (Table 10). Online suppl. Table 4 shows the devices used in *RPE65* mutation-associated IRD patients.

#### *Pupillometry and Mobility Testing at Defined Light Levels*

Only 14% of the 22 centers that manage *RPE65* mutation-associated IRD patients perform pupillometry. From these 3 centers, 2 (67%) perform chromatic pupillometry [24–26]. Only 5% of the 22 centers that manage *RPE65* mutation-associated IRD patients perform mobility testing at defined light levels (Ora-VNC™, Ora, Inc., Andover, MA, USA).

#### *Retinal Imaging and Fundus Autofluorescence Recording*

Fifty percent of the centers perform fundus imaging in *RPE65* mutation-associated IRD patients every year, 27% every 6 months, and 18% every 2 years (Table 11). Fundus autofluorescence (FAF) recording is performed every year in 50% of their *RPE65* mutation-associated IRD patients, every 6 months in 18%, every 2 years in 14%, and at even longer intervals in 9% (Table 11). Spectral domain-optical coherence tomography (SD-OCT) is performed every year in 50% of the 22 centers in *RPE65* mutation-associated IRD patients, every 6 months in 27%, and every 2 years in 18% (Table 11).

## **Discussion**

This is the first comprehensive survey on diagnosis and management of *RPE65* mutation-associated IRDs among all EVICR.net centers in Europe and Israel. We

**Table 11.** Frequency that centers perform fundus imaging, FAF and SD-OCT recording in *RPE65* mutation-associated IRD patients

	Fundus imaging		FAF		SD-OCT	
	<i>n</i>	%	<i>n</i>	%	<i>n</i>	%
Monthly	0	0	0	0	0	0
Quarterly	0	0	0	0	0	0
Twice a year	6	27	4	18	6	27
Annually	11	50	11	50	11	50
Biennially	4	18	3	14	4	18
Longer	0	0	2	9	0	0
Other: with every visit	1	5	1	5	1	5
Other: we try to retrieve FAF images on the first visits, but if we do not succeed, and know that is not a hypomorph mutation, we do not repeat it on every follow-up visit	0	0	1	5	0	0
Total	22	100	22	100	22	100
Total of centers with <i>RPE65</i> mutation-associated IRD patients	22	100	22	100	22	100

*n* refers to the number of centers. IRD, inherited retinal degeneration; FAF, fundus autofluorescence; SD-OCT, spectral domain-optical coherence tomography.

are not aware of a similar survey in other parts of the world. Only 22 of the 49 responding centers follow *RPE65* mutation-associated IRD patients (Fig. 1).

Adding the estimated numbers in the 22 EVICR.net centers, the range of patients with homozygous mutations in *RPE65* goes from 65 to 155 and the range of patients with compound heterozygous mutations in *RPE65* goes from 90 to 187. Only 60 to 129 patients were estimated to carry class 4 and 5 mutations (Tables 1, 3, 4). So, a conservative estimation of patients eligible to gene augmentation therapy would be at least 60, and 129 at max. As we do not know the age or the current visual function of the estimated number of patients with class 4 and 5 mutations, the actual number is probably even lower. Given the estimated overall number of patients with biallelic mutations in Europe, that is, 2,500 patients based on a prevalence of 1:300,000 [1, 18], we can confirm an unmet need of patient identification. The fact that 17% of the cases were diagnosed as unclassified visual impairment and 28.1% with RP indicates that a significant number of patients may go undiagnosed if not referred to a specialized center. Without molecular genetic diagnostics, 45.1% of the patients are at risk not to be associated with the *RPE65* genotype. This is unfortunate, as cost-effectiveness of the gene augmentation therapy with VN has been shown by several groups, not to speak about the alleviation of the burden of a disease that left untreated usually ends in blindness by the end of the third to fourth decade of life [8, 12, 19]. To identify all patients eligible

for gene therapy with VN, patients with the diagnosis RP/rod-cone dystrophy and unclassified visual impairment summarizing to 45.1% are of particular interest. They might have received their diagnosis well before the advent of gene therapy, and therefore reevaluation and genetic testing should be considered in this patient group. Another reason could be that ophthalmologists, pediatricians, neurologists, or general practitioners are not yet aware of the availability of VN therapy. To reach those patients and their physicians, disease awareness and educational campaigns in scientific journals and conferences, patients' organizations meetings, and even in the public media might be useful. To detect early stages, it could be discussed to include testing of *RPE65* in the already established neonatal screening program for severe genetic diseases amenable to therapy.

Besides the established treatment with VN, improvements are sought by novel gene augmentation therapies explored in human induced pluripotent stem cell-derived retinal pigment epithelial cells [27, 28], and by gene correction via CRISPR-Cas9 [29]. At present, both developments are in the preclinical phase. To test such novel approaches, there is a need to identify more patients with the *RPE65* genotype, who would be interested to take part in further clinical trials.

#### *Psychophysics*

The survey asked for the work-up and follow-up of patients with suspected or confirmed biallelic mutations

in *RPE65*. All centers perform a comprehensive eye examination (Tables 6–10, online suppl. Tables 3, 4). The results concerning methods used for VA testing reflect the fact that young patients are less frequently seen in the 22 centers that do follow such patients (online suppl. Table 2). The most frequently used tests are ETDRS and Snellen charts, each at 59% (Table 7). As multiple answers were allowed, it is not possible to conclude about the absolute frequency of the use of ETDRS charts. Dong et al. [30] reported in 2003 that ETDRS charts were used in 16/19 studies since the publication of the charts in 1982. Kaiser compared the validity of ETDRS versus Snellen in his AOI thesis [31]. The validity of ETDRS charts was also tested in children [32]. Recently, repeatability and agreement of VA testing using the ETDRS Number chart, Landolt C chart, or ETDRS Alphabet chart in eyes with or without sight-threatening diseases was reported [33]. This is of interest for the PERCEIVE Registry, a post-authorization observational safety study for patients treated with VN, sponsored by Novartis (ENCePP CLT-W888A12401, <http://www.encepp.eu/encepp/viewResource.htm?id=37005>). If all centers treating patients with VN use ETDRS charts, the scientific value of the VA data will be high. LEA symbols are also available in the format used in the ETDRS charts. Interpretation of VA data should acknowledge that repeated measurements even the same day can vary significantly in patients with *RPE65* mutations [34].

Concerning VF testing, kinetic perimetry is done in most centers, mostly Goldmann perimetry (Table 8 and online suppl. Table 3c). Static perimetry is used in about half of the centers (Table 8 and online suppl. Table 3a). Fundus-controlled perimetry is only used in 4 centers (18%). As the PERCEIVE Registry does not require specific methods for VF testing, it is likely that quantitative data on the long-term effect of VN collected in all participating centers will be limited to kinetic perimetry. Unfortunately, VF data obtained with kinetic perimetry have to be interpreted with caution [35–38]. FDA encourages sponsors to explore a wide spectrum of potential clinical end points and other clinical effects in early-phase trials, such as retinal imaging, VA (low and high luminance), VFs, color vision, contrast sensitivity, and functional vision (i.e., how well the patient performs vision-related activities of daily living). For later phase trials, primary efficacy end points should reflect clinical benefit, such as improvement in function or symptoms (<https://www.fda.gov/media/124641/download>). Therefore, additional readout parameters were included in the phase 1–3 studies on *RPE65* gene therapy with VN such as the specifi-

cally developed multi-luminance mobility test (MLMT) [39]. The only spatially resolved VF testing separating the rod from the cone pathway is 2 CT-perimetry [26]. This is interesting as all data published so far on the effects of VN therapy indicate a clear effect on the rod function, but an ambiguous effect on the cone function [13, 40]. Unfortunately, this method is only used in 9% of the 22 EVICR.net centers that do manage *RPE65* patients as 2 CT-perimetry is not a commercially available device.

A psychophysical test that globally differentiates between the rod and cone pathway is chromatic FST [19, 26, 41]. In the 22 EVICR.net centers that follow *RPE65* patients, chromatic FST is used in only 6/8 centers that use FST (Table 10 and online suppl. Table 4). Ganzfeld electroretinogram (ERG) is an objective test that separates the global rod from the global cone function in the retina. Unfortunately, in the majority of patients with biallelic mutations in *RPE65*, rod and cone responses are not measurable at the time of diagnosis. The natural history study on 70 patients with *RPE65* mutation-associated IRDs found 98 full-field-ERGs on 60 patients. The scotopic ERG responses were extinguished in 78.6%, and the photopic, that is, cone-mediated responses in 61.2%. The mean age of patients with residual rod- and cone-mediated responses was 10.5 and 9.8 years [8, 9, 39].

Another test able to separate the rod from the cone function is chromatic pupillometry [26]. Only 3/22 EVICR.net centers that follow *RPE65* mutation-associated IRD patients perform pupillometry (14%), and only 2/3 (66%) perform chromatic pupillometry. The test that was decisive for the approval of VN for the treatment of biallelic *RPE65* mutation-associated IRDs was the MLMT, as a highly patient relevant readout parameter, and considered to be less variable than VA and VF results [42]. Only 5% of the 22 EVICR.net centers that follow *RPE65* patients have a mobility course, as it is expensive and time consuming. This is unfortunate as mobility is important for the quality of life, and hence one of the possible major benefits of VN therapy in patients with *RPE65* mutation-associated IRDs. Therefore, tests separating rod from cone-mediated vision including mobility testing may not yield statistically meaningful results in the PERCEIVE Registry due to limited data availability.

#### *Retinal Imaging*

Retinal fundus imaging including FAF recording is performed in all 22 EVICR.net centers following patients with *RPE65* mutation-associated IRDs (Table 11). Lack of FAF has been reported as a hallmark sign of the *RPE65* phenotype [9]. In patients with hypomorphic mutations,

some FAF may be present or develop over the years [29, Lorenz et al., unpublished data]. A recent study using quantitative FAF has shown that FAF may become noticeable after VN therapy [43]. As some centers reported to register FAF images only once when it is not measurable, it is now highly recommended to systematically take FAF images after VN therapy. SD-OCT is regularly tested in all EVICR.net centers following patients with *RPE65* mutation related IRDs. Half of the centers perform SD-OCT at an annual basis, and about a quarter twice every year (Table 11). SD-OCT is an important readout parameter, as has been shown again recently [44]. Following treatment, it should also be an obligatory test to monitor the disease course as it has been shown that degeneration may continue in the area treated [16], depending on the percentage of photoreceptors preserved at the time of treatment [17].

#### *Frequency of Follow-Up*

Half of the 22 EVICR.net centers that follow patients with *RPE65* related IRDs see their patients annually, 27% twice a year or 18% biannually (Tables 5, 6, 9, 11 and online suppl. Table 2). Usually, all tests used for phenotyping are repeated at each visit. Given the validity of the tests, highly significant data on the natural course of the disease are available in all 22 centers that follow *RPE65* patients. Depending on the number of patients eligible to therapy, for example, according to the criteria published by the professional ophthalmological associations in Germany [21], we can expect a significant number of patients treated with VN in the future, and followed adequately.

Annual follow-up appears a reasonable compromise to monitor the natural course. Following subretinal gene therapy, more frequent follow-up examinations, for example, 1, 3, 6 months, and 1 year appear appropriate during the 1st year post therapy to monitor any changes related to the therapy. Of note, in order to develop recommendations as to the management of *RPE65* mutation-associated IRDs, and IRDs in general, it is also important to take into consideration age of onset, duration of the disease, and severity of the mutations.

#### *Weaknesses of the Survey*

To estimate the overall coverage of eye departments caring for patients with IRDs, and in particular with *RPE65* mutation-associated IRDs, we have to acknowledge that the number of EVICR.net centers responding to the survey is significantly smaller than the overall number of eye departments and in addition varies among countries. For example, in Belgium there are at present 3

EVICR.net centers but 5 university hospitals. In Germany, 15/38 university departments and 2/62 non-university eye departments are EVICR.net members. Only 5 German EVICR.net centers of the 10 repliers in Germany have IRD patients with confirmed biallelic mutations in *RPE65*. In the Netherlands, there are 8 University Eye Departments and 1 non-university Eye Hospital; 5/9 are EVICR-net centers, and 3/5 replied to the survey. In addition, patients are also seen outside eye departments (in private practice) and not necessarily referred back to eye departments for more precise classification once they have the diagnosis of RP or central visual impairment. For example, in Germany, the overall number of practicing ophthalmologists is about 6,500, but about two-thirds work outside eye departments. Therefore, it is difficult to give a precise estimation of the overall number of patients with *RPE65* mutation-associated IRDs in Europe. Another way to estimate the number of patients with *RPE65* mutation-associated IRDs covered by our survey is to compare the number of patients estimated in the EVICR.net centers in each country to the estimated overall prevalence. In Germany, 45 to at least 57 *RPE65* mutation-associated IRD patients are followed in 5 German EVICR.net centers. With a population of about 83 million and given the estimated prevalence of IRD cases of 1:3,000 and an estimated prevalence of *RPE65* mutation-associated IRD patients of 1–2% [18], the overall number of patients with *RPE65* mutations in Germany would be 277–553. This would mean 8–20% of all *RPE65* mutation-associated IRD patients in Germany are followed in the 5 German EVICR.net centers. In the Netherlands, due to collaboration within the RD5000 study group, precise numbers are available in Rotterdam where currently 46 patients with *RPE65* mutation-associated IRDs are seen. Fifty percent are from a genetic isolate [12]. Some more patients are known outside the patient cohort seen in Rotterdam, so the overall estimated prevalence is in the order of 65–75 patients for a population of 17.3 million. In Portugal, for a population of ~10 million, estimates anticipate an overall number of *RPE65* mutation-associated IRD patients between 33 and 67. The numbers that resulted from this survey indicate a considerably smaller number. Two possible reasons are (1) patients being followed at other centers that are currently not EVICR.net members and/or (2) patients that remain unidentified because genetic testing is not routinely performed (nor available) in all centers.

Taking the numbers from Germany, the Netherlands, and Portugal together, the estimated overall prevalence is quite similar, but differences are evident with regard to

the percentage of already identified patients. The Netherlands has the highest number of already identified patients with biallelic mutations in *RPE65*.

Although done on purpose, the fact that we only asked for estimated numbers of patients followed in the EVICR.net centers, can further influence the real number of patients with *RPE65* mutation-associated IRDs. In addition, we do not know how many patients are seen in several centers in parallel. Of note, only 14/47 European countries (including Russia and Turkey) participated in the survey. Altogether, we cannot conclude with sufficient precision on the number of patients with *RPE65* mutation-associated IRDs in Europe.

In the survey, we asked about the estimated number of patients with class 4 and 5 mutations (online suppl. material – online questionnaire). In the instruction part, we did not elaborate on what class 4 and 5 mutations mean. Although the classification system has been published [20], some responders may not have been familiar with this classification system. As at present only class 4 and class 5 mutations are considered to be clearly disease-causing and hence suited for VN therapy, at least according to the recommendations of the German Ophthalmology Societies [21], it is important to identify such patients.

#### *Strengths of the Survey*

This survey for the first time provides estimates on the number of patients with *RPE65* mutation-associated IRDs, followed in 22 EVICR.net centers. As all EVICR.net centers are certified and follow the same standard operating procedures, it can be expected that the data available have been collected and archived in a comparable way. The survey has yielded precise data on the test methods and devices used. Of note, the number of centers that use more sophisticated tests such as the FST, pupillometry, fundus-controlled perimetry, and mobility course is still limited. The PERCEIVE Registry, sponsored by Novartis, aims to observe and understand the clinical impact of VN in a real-world setting. Through systematic collection of data on adverse events (AE and SAE), the study will characterize the long-term safety profile of VN over a period of 5 years (ENCePP CLTW888A12401, <http://www.encepp.eu/encepp/viewResource.htm?id=37005>, overall duration 10 years). In addition, basic data such as VA, VF, and OCT are collected by the centers on a voluntary basis to monitor long-term functional and morphological outcome. When available, more sophisticated data such as FST and eventually MLMT will also be entered, but as they are not part of the standard of care, they may not be conducted on the majority of patients. Given the

significant socioeconomic burden to the society, it would be of great interest to collect such additional data. They can quantitatively document objective treatment effects relevant to patient's quality of life and in more detail than the patient-reported outcomes questionnaires that are currently part of the PERCEIVE Registry. Efforts should be made in this direction.

#### **Conclusion**

This survey on diagnosis and management of *RPE65* mutation-associated IRDs has provided important information on the actual situation in the 22 EVICR.net centers that have answered and followed such patients. The EVICR.net was a unique platform for collecting the data. These baseline data, previously not explored on such a scale, are of great importance to policy makers, clinicians, patient advocate groups, researchers, and others to inform and improve bottlenecks in the provision of optimal care for patients with *RPE65* mutation-associated IRDs. Recommendations as to future steps include suggestions as to the timely detection of as many patients as possible who might benefit from VN therapy and for follow-up studies. The latter is important in view of cost-effectiveness and patient satisfaction of VN therapy. Guidelines on the diagnosis and management of *RPE65* mutation-associated IRDs in particular and on IRDs in general can be developed based on the results of this unique data set.

#### **Acknowledgements**

We thank Dr. Sue Lacey, PhD (former Novartis employee), for providing valuable comments in the design and content of the IRD questionnaire, as well as to the results report. We thank Dr. Isabelle Audo, MD PhD (CHNO of Quinze-Vingts, Paris, France), for reviewing the first draft of the survey. We also thank Markus Preisgen, PhD (Dept. of Ophthalmology, Justus-Liebig-University Gießen, Germany), who helped with the format and contents of the first draft of the survey. We thank the Novartis team for the final review of this manuscript and for providing valuable scientific and editorial comments.

#### **Statement of Ethics**

This survey was reviewed and approved by the AIBILI Ethics Committee – Comissão de Ética para a Saúde, prior to its dissemination to the 101 EVICR.net clinical centers members and was in accordance with the World Medical Association Declaration of Helsinki. As no personal data were collected, the use of a written and informed consent form was not applicable.

## Conflict of Interest Statement

The authors have no conflicts of interest to declare.

## Funding Sources

Novartis Pharma AG through a Scientific Collaboration Agreement between Novartis and AIBILL, the Coordinating Center of EVICR.net funded this study. Novartis provided nonbinding comment/input to the IRD Survey Expert Committee into all elements of the scientific collaboration agreement.

## Author Contributions

The IRD questionnaire was designed by B.L., J.T., L.I.B., J.P.M., and H.P.N.S.; J.T. and B.L. analyzed data. B.L. and J.T. wrote the manuscript. L.I.B., J.P.M., and H.P.N.S. reviewed and complemented the manuscript. B.L., J.T., L.I.B., J.P.M., and H.P.N.S. approved the final manuscript.

## References

- Galvin O, Chi G, Brady L, Hippert C, Del Valle Rubido M, Daly A, et al. The Impact of Inherited Retinal Diseases in the Republic of Ireland (ROI) and the United Kingdom (UK) from a cost-of-illness perspective. *Clin Ophthalmol*. 2020 Mar;14:707–19.
- Johnson S, Buessing M, O'Connell T, Pitluck S, Ciulla TA. Cost-effectiveness of voretigene neparvovec-rzyl vs standard care for RPE65-mediated inherited retinal disease. *JAMA Ophthalmol*. 2019 Oct;137(10):1115.
- Uhrmann MF, Lorenz B, Gissel C. Cost effectiveness of voretigene neparvovec for RPE65-mediated inherited retinal degeneration in Germany. *Transl Vis Sci Technol*. 2020 Aug;9(9):17.
- Viriato D, Bennett N, Sidhu R, Hancock E, Lomax H, Trueman D, et al. An economic evaluation of voretigene neparvovec for the treatment of biallelic RPE65-mediated inherited retinal dystrophies in the UK. *Adv Ther*. 2020 Mar;37(3):1233–47.
- Zimmermann M, Lubinga SJ, Banken R, Rind D, Cramer G, Synnott PG, et al. Cost utility of voretigene neparvovec for biallelic RPE65-mediated inherited retinal disease. *Value Health*. 2019 Feb;22(2):161–7.
- Marlhens F, Bareil C, Griffoin JM, Zrenner E, Amalric P, Eliaou C, et al. Mutations in RPE65 cause Leber's congenital amaurosis. *Nat Genet*. 1997 Oct;17(2):139–41.
- Gu SM, Thompson DA, Srikumari CR, Lorenz B, Finckh U, Nicoletti A, et al. Mutations in RPE65 cause autosomal recessive childhood-onset severe retinal dystrophy. *Nat Genet*. 1997 Oct;17(2):194–7.
- Chung DC, Bertelsen M, Lorenz B, Pennesi ME, Leroy BP, Hamel CP, et al. The natural history of inherited retinal dystrophy due to biallelic mutations in the RPE65 gene. *Am J Ophthalmol*. 2019 Mar;199:58–70.
- Lorenz B, Poliakov E, Schambeck M, Friedburg C, Preising MN, Redmond TM. A comprehensive clinical and biochemical functional study of a novel RPE65 hypomorphic mutation. *Invest Ophthalmol Vis Sci*. 2008 Dec;49(12):5235–42.
- Hull S, Holder GE, Robson AG, Mukherjee R, Michaelides M, Webster AR, et al. Preserved visual function in retinal dystrophy due to hypomorphic RPE65 mutations. *Br J Ophthalmol*. 2016 Nov;100(11):1499–505.
- Kumaran N, Rubin GS, Kalitzeos A, Fujinami K, Bainbridge JWB, Weleber RG, et al. A cross-sectional and longitudinal study of retinal sensitivity in RPE65-associated Leber congenital amaurosis. *Invest Ophthalmol Vis Sci*. 2018 Jul;59(8):3330.
- Pierrache LHM, Ghafaryasl B, Khan MI, Yzer S, van Genderen MM, Schuil J, et al. Longitudinal study of RPE65-associated inherited retinal degenerations. *Retina*. 2020 Sep;40(9):1812–28.
- Russell S, Bennett J, Wellman JA, Chung DC, Yu Z-F, Tillman A, et al. Efficacy and safety of voretigene neparvovec (AAV2-hRPE65v2) in patients with RPE65-mediated inherited retinal dystrophy: a randomised, controlled, open-label, phase 3 trial. *Lancet*. 2017 Aug;390(10097):849–60.
- Bennett J, Wellman J, Marshall KA, McCague S, Ashtari M, DiStefano-Pappas J, et al. Safety and durability of effect of contralateral-eye administration of AAV2 gene therapy in patients with childhood-onset blindness caused by RPE65 mutations: a follow-on phase 1 trial. *Lancet*. 2016 Aug;388(10045):661–72.
- Lorenz B, Tavares J, van den Born LI, Marques JP, Scholl HPN. Current management of Inherited Retinal Degenerations (IRD) patients in Europe. Results of a multinational survey by the European Vision Institute Clinical Research Network EVICR.net. *Ophthalmic Res*. 2021 Jan. Epub ahead of print.
- Cideciyan AV, Jacobson SG, Beltran WA, Sumaroka A, Swider M, Iwabe S, et al. Human retinal gene therapy for Leber congenital amaurosis shows advancing retinal degeneration despite enduring visual improvement. *Proc Natl Acad Sci U S A*. 2013 Feb;110(6):E517–25.
- Gardiner KL, Cideciyan AV, Swider M, Dufour VL, Sumaroka A, Komáromy AM, et al. Long-term structural outcomes of late-stage RPE65 gene therapy. *Mol Ther*. 2020 Jan;28(1):266–78.
- Pontikos N, Arno G, Jurkute N, Schiff E, Bababbar R, Malka S, et al. Genetic basis of inherited retinal disease in a molecularly characterized cohort of more than 3,000 families from the United Kingdom. *Ophthalmology*. 2020 Oct;127(10):1384–94.
- Roman AJ, Schwartz SB, Aleman TS, Cideciyan AV, Chico JD, Windsor EA, et al. Quantifying rod photoreceptor-mediated vision in retinal degenerations: dark-adapted thresholds as outcome measures. *Exp Eye Res*. 2005 Feb;80(2):259–72.
- Richards S, Aziz N, Bale S, Bick D, Das S, Gastier-Foster J, et al. Standards and guidelines for the interpretation of sequence variants: a joint consensus recommendation of the American College of Medical Genetics and Genomics and the Association for Molecular Pathology. *Genet Med*. 2015 May;17(5):405–24.
- German Society of Ophthalmology (Deutsche Ophthalmologische Gesellschaft, DOG); German Retina Society e. V. (Retinologische Gesellschaft e. V., RG); Professional Association of German Ophthalmologists (Berufsverband der Augenärzte Deutschlands e. V., BVA). Statement of the DOG, the RG, and the BVA on the therapeutic use of voretigene neparvovec (Luxturna™) in ophthalmology. English version. *Der Ophthalmol*. 2020 Jan;117(Suppl 1):16–24.
- Motta F, Martin R, Porto F, Wohler E, Resende R, Gomes C, et al. Pathogenicity reclassification of RPE65 missense variants related to leber congenital amaurosis and early-onset retinal dystrophy. *Genes*. 2019 Dec;11(1):24.
- Yang U, Gentleman S, Gai X, Gorin MB, Borchert MS, Lee TC, et al. Utility of in vitro mutagenesis of RPE65 protein for verification of mutational pathogenicity before gene therapy. *JAMA Ophthalmol*. 2019 Dec;137(12):1381.

- 24 Kardon R, Anderson SC, Damarjian TG, Grace EM, Stone E, Kawasaki A. Chromatic pupillometry in patients with retinitis pigmentosa. *Ophthalmology*. 2011 Feb;118(2):376–81.
- 25 Park JC, Moura AL, Raza AS, Rhee DW, Kardon RH, Hood DC. Toward a clinical protocol for assessing rod, cone, and melanopsin contributions to the human pupil response. *Invest Ophthalmol Vis Sci*. 2011 Aug;52(9):6624–35.
- 26 Lorenz B, Strohmayer E, Zahn S, Friedburg C, Kramer M, Preising M, et al. Chromatic pupillometry dissects function of the three different light-sensitive retinal cell populations in RPE65 deficiency. *Invest Ophthalmol Vis Sci*. 2012 Aug;53(9):5641–52.
- 27 Georgiadis A, Duran Y, Ribeiro J, Abelleira-Hervas L, Robbie SJ, Sünkel-Laing B, et al. Development of an optimized AAV2/5 gene therapy vector for Leber congenital amaurosis owing to defects in RPE65. *Gene Ther*. 2016 Dec;23(12):857–62.
- 28 Georgiadis A, Duran Y, Ribeiro J, Abelleira-Hervas L, Robbie SJ, Sünkel-Laing B, et al. Correction: development of an optimized AAV2/5 gene therapy vector for Leber congenital amaurosis owing to defects in RPE65. *Gene Ther*. 2018 Sep;25(6):450.
- 29 Jo DH, Song DW, Cho CS, Kim UG, Lee KJ, Lee K, et al. CRISPR-Cas9-mediated therapeutic editing of Rpe65 ameliorates the disease phenotypes in a mouse model of Leber congenital amaurosis. *Sci Adv*. 2019 Oct;5(10):eaax1210.
- 30 Dong LM, Marsh MJ, Hawkins BS. Measurement and analysis of visual acuity in multicenter randomized clinical trials in the United States: findings from a survey. *Ophthalmic Epidemiol*. 2003 Jan;10(3):149–65.
- 31 Kaiser PK. Prospective evaluation of visual acuity assessment: a comparison of snellen versus ETDRS charts in clinical practice (An AOS Thesis). *Trans Am Ophthalmol Soc*. 2009 Dec;107:311–24.
- 32 Manny RE, Hussein M, Gwiazda J, Marsh-Tootle W. Repeatability of ETDRS visual acuity in children. *Invest Ophthalmol Vis Sci*. 2003 Aug;44(8):3294.
- 33 Chaikitmongkol V, Nanegrungsunk O, Patikulasila D, Ruamviboonsuk P, Bressler NM. Repeatability and agreement of visual acuity using the ETDRS number chart, Landolt C chart, or ETDRS alphabet chart in eyes with or without sight-threatening diseases. *JAMA Ophthalmol*. 2018 Mar;136(3):286.
- 34 Cideciyan AV, Swider M, Aleman TS, Feuer WJ, Schwartz SB, Russell RC, et al. Macular function in macular degenerations: repeatability of microperimetry as a potential outcome measure for ABCA4 -associated retinopathy trials. *Invest Ophthalmol Vis Sci*. 2012 Feb;53(2):841.
- 35 Vonthein R, Rauscher S, Paetzold J, Nowomiejska K, Krapp E, Hermann A, et al. The normal age-corrected and reaction time-corrected isopter derived by semi-automated kinetic perimetry. *Ophthalmology*. 2007 Jun;114(6):1065–72.e2.
- 36 Nowomiejska K, Brzozowska A, Zarnowski T, Rejdak R, Weleber RG, Schiefer U. Variability in isopter position and fatigue during semi-automated kinetic perimetry. *Ophthalmologica*. 2012;227(3):166–72.
- 37 Rowe FJ, Czanner G, Somerville T, Sood I, Sood D. Octopus 900 automated kinetic perimetry versus standard automated static perimetry in glaucoma practice. *Curr Eye Res*. 2021 Jan;46(1):83–95.
- 38 Zrenner E, Holder GE, Schiefer U, Wild JM. Quality control procedures and baseline values for electroretinography, perimetry, color vision, and visual acuity in an international multicenter study: observations from a safety trial in chronic stable angina pectoris. *Transl Vis Sci Technol*. 2020 Jul;9(8):38.
- 39 Paunescu K, Wabbers B, Preising MN, Lorenz B. Longitudinal and cross-sectional study of patients with early-onset severe retinal dystrophy associated with RPE65 mutations. *Graefes Arch Clin Exp Ophthalmol*. 2005 May;243(5):417–26.
- 40 Maguire AM, Russell S, Wellman JA, Chung DC, Yu ZF, Tillman A, et al. Efficacy, safety, and durability of voretigene neparvec-rzyl in RPE65 mutation-associated inherited retinal dystrophy: results of phase 1 and 3 trials. *Ophthalmology*. 2019 Sep;126(9):1273–85.
- 41 Jacobson SG, Aleman TS, Cideciyan AV, Roman AJ, Sumaroka A, Windsor EA, et al. Defining the residual vision in Leber congenital amaurosis caused by RPE65 mutations. *Invest Ophthalmol Vis Sci*. 2009 May;50(5):2368.
- 42 Chung DC, McCague S, Yu ZF, Thill S, DiStefano-Pappas J, Bennett J, et al. Novel mobility test to assess functional vision in patients with inherited retinal dystrophies. *Clin Exp Ophthalmol*. 2018 Apr;46(3):247–59.
- 43 Levi SR, Oh JK, de Carvalho JRL, Mahajan VB, Tsang SH, Sparrow JR. Quantitative autofluorescence following gene therapy with voretigene neparvec. *JAMA Ophthalmol*. 2020 Aug;138(8):919.
- 44 Kumaran N, Georgiou M, Bainbridge JWB, Bertelsen M, Larsen M, Blanco-Kelly F, et al. Retinal structure in RPE65-associated retinal dystrophy. *Invest Ophthalmol Vis Sci*. 2020 Apr;61(4):47.





ANNEX III

**9.3. Response to "Comment on the Article: Subretinal bleb of Voretigene Neparvovec"**

Marques JP, Alfaiate M, Figueira J

Asia Pac J Ophthalmol (Phila). 2022 Mar 25. Online ahead of print.



## OPEN

## Response to “Comment on the Article: Subretinal Bleb of Voretigene Neparvovec”

### To the Editor:

We appreciate the authors' comment to our manuscript<sup>1</sup> and share the authors' concern about the development of chorioretinal atrophy following the administration of voretigene neparvovec (VN), as described by Gange et al.<sup>2</sup> In our article, the procedure of subretinal administration of VN was described according to the protocol used in the phase 3 trial that led to the approval of VN<sup>3</sup> by the Food and Drug Administration in the US and European Medicines Agency in Europe. In our limited experience (12 eyes, 6 patients) with VN, the fovea was detached in all cases and the full amount of VN was manually injected subretinally via a single bleb. We did not observe any cases of chorioretinal atrophy so far but we have a limited follow-up ( $4.00 \pm 2.28$  months) and an older cohort ( $27.5 \pm 7.82$ ; min 16 – max 39 years old) than Gange et al.<sup>2</sup> Although we can understand the rationale for distributing the drug volume to more than a single bleb, we must keep in mind that this is associated with increased surgi-

cal risks due to the need of more than one retinotomy. Furthermore, there is no concluding evidence that detaching the fovea during subretinal injection has a negative impact on the visual function outcomes. In fact, real-world evidence with VN recently published by Sengillo et al<sup>4</sup> showed that no significant difference in best-corrected visual acuity change or in central foveal thickness change was found between eyes with and without foveal detachment at any follow-up visit. The phase 3 results at 3 and 4 years<sup>5</sup> showed a similar safety profile as previously described<sup>3</sup> and no cases of chorioretinal atrophy in the study participants. We agree that surgical techniques should be perfected to benefit our patients but significant protocol deviations that are not adequately validated may put the drug efficacy and ultimately our patients' vision at stake. As the number of VN treatments increase worldwide, we will be able to evaluate long-term post-market real world outcomes data and hopefully identify the reasons behind the progressive chorioretinal atrophy described by Gange et al.<sup>2</sup>

João Pedro Marques, MD, MSc\*†‡

Mário Alfaiate, MD\*

João Pereira Figueira, MD, PhD\*†‡

\*Ophthalmology Unit, Centro Hospitalar e Universitário de Coimbra, (CHUC), Coimbra, Portugal

†University Clinic of Ophthalmology, Faculty of Medicine, University of Coimbra (FMUC), Coimbra, Portugal

‡Clinical Academic Center of Coimbra (CACC), Coimbra, Portugal

### REFERENCES

1. Marques JP, Alfaiate M, Figueira JP. Subretinal bleb of voretigene neparvovec. *Asia Pac J Ophthalmol (Phila)*. 2021. doi:10.1097/APO.0000000000000431. Online ahead of print.
2. Gange WS, Sisk RA, Besirli CG, et al. Perifoveal chorioretinal atrophy after subretinal voretigene neparvovec-rzyl for RPE65-mediated leber congenital amaurosis. *Ophthalmol Retina*. 2022;6:58–64.
3. Russell S, Bennett J, Wellman JA, et al. Efficacy and safety of voretigene neparvovec (AAV2-hRPE65v2) in patients with RPE65-mediated inherited retinal dystrophy: a randomised, controlled, open-label, phase 3 trial. *Lancet*. 2017;390:849–860.
4. Sengillo JD, Gregori NZ, Sisk RA, et al. Visual acuity, retinal morphology, and patients' perceptions after voretigene neparvovec-rzyl for RPE65-associated retinal disease. *Ophthalmol Retina*. 2021. S2468-6530(21)00378-X. Publish ahead of print. doi:10.1016/j.oret.2021.11.005.
5. Maguire AM, Russell S, Chung DC, et al. Durability of voretigene neparvovec for biallelic RPE65-mediated inherited retinal disease: phase 3 results at 3 and 4 years. *Ophthalmology*. 2021;128:1460–1468.

The authors have no conflicts of interest to declare.

Address correspondence and reprint requests to: João Pedro Marques, Centro de Responsabilidade Integrado em Oftalmologia (CRIO), Centro Hospitalar e Universitário de Coimbra (CHUC), Praceta Prof. Mota Pinto, 3000-075 Coimbra, Portugal. E-mail: marquesjoaopedro@gmail.com

Copyright © 2022 Asia-Pacific Academy of Ophthalmology. Published by Wolters Kluwer Health, Inc. on behalf of the Asia-Pacific Academy of Ophthalmology. This is an open access article distributed under the terms of the Creative Commons Attribution-Non Commercial-No Derivatives License 4.0 (CCBY-NC-ND), where it is permissible to download and share the work provided it is properly cited. The work cannot be changed in any way or used commercially without permission from the journal.

ISSN: 2162-0989

DOI: 10.1097/APO.0000000000000517



ANNEX IV

**9.4. Molecular and Multimodal Retinal Imaging Findings in a Multicentric Portuguese Cohort of Stargardt Disease**

Geada S, Santos C, Vaz-Pereira S, Marta A, Correia M, Sousa K, Soares M, Carvalho AL, Saraiva J, Murta J, Silva R, Coutinho-Santos L, Marques JP

Revista Sociedade Portuguesa de Oftalmologia 2022;46(1):15-24.



# Molecular and Multimodal Retinal Imaging Findings in a Multicentric Portuguese Cohort of Stargardt Disease

## Achados Moleculares e de Imagiologia Multimodal numa Amostra Multicêntrica de Doentes Portugueses com Doença de Stargardt

 Sara Geada<sup>1</sup>,  Cristina Santos<sup>2</sup>,  Sara Vaz-Pereira<sup>3,4</sup>,  Ana Marta<sup>5,6</sup>,  Marta Correia<sup>7</sup>,  Keissy Sousa<sup>8</sup>,  
 Mário Soares<sup>1</sup>,  Ana Luísa Carvalho<sup>9,10,12</sup>,  Jorge Saraiva<sup>9,11,12</sup>,  Joaquim Murta<sup>1,12,13</sup>,  Rufino Silva<sup>1,12,13</sup>,  
 Luísa Coutinho Santos<sup>2</sup>,  João Pedro Marques<sup>1,12,13</sup>

<sup>1</sup> Department of Ophthalmology, Centro Hospitalar e Universitário de Coimbra, EPE, Coimbra, Portugal

<sup>2</sup> Instituto de Oftalmologia Dr. Gama Pinto, Lisbon, Portugal

<sup>3</sup> Department of Ophthalmology, Centro Hospitalar Universitário de Lisboa Norte, EPE - Hospital de Santa Maria, Lisbon, Portugal

<sup>4</sup> Department of Ophthalmology, Faculdade de Medicina, Universidade de Lisboa, Lisbon, Portugal

<sup>5</sup> Department of Ophthalmology, Centro Hospitalar e Universitário do Porto, EPE, Porto, Portugal

<sup>6</sup> Instituto Ciências Biomédicas Abel Salazar (ICBAS), Porto, Portugal

<sup>7</sup> Department of Ophthalmology, Centro Hospitalar de Lisboa Ocidental, EPE, Lisbon, Portugal

<sup>8</sup> Department of Ophthalmology, Hospital de Braga, Braga, Portugal

<sup>9</sup> Medical Genetics Unit, Hospital Pediátrico, Centro Hospitalar e Universitário de Coimbra, EPE, Coimbra, Portugal

<sup>10</sup> University Clinic of Genetics, Faculty of Medicine, University of Coimbra, Coimbra, Portugal

<sup>11</sup> University Clinic of Pediatrics, Faculty of Medicine, University of Coimbra, Coimbra, Portugal

<sup>12</sup> Clinical Academic Center of Coimbra, Coimbra, Portugal

<sup>13</sup> University Clinic of Ophthalmology, Faculty of Medicine, University of Coimbra (FMUC), Coimbra, Portugal

**Recebido/Received:** 2021-10-15 | **Aceite/Accepted:** 2021-12-12 | **Publicado/Published:** 2022-03-31

© Author(s) (or their employer(s)) and *Oftalmologia* 2022. Re-use permitted under CC BY-NC. No commercial re-use.

© Autor (es) (ou seu (s) empregador (es)) e *Oftalmologia* 2022. Reutilização permitida de acordo com CC BY-NC. Nenhuma reutilização comercial.

DOI: <https://doi.org/10.48560/rspo.25968>

## ABSTRACT

**INTRODUCTION:** Our purpose was to describe the molecular and multimodal retinal imaging findings in a cohort of Portuguese patients with a clinical diagnosis of Stargardt Disease (STGD1).

**METHODS:** Multicenter, cross sectional cohort study of consecutive patients with a clinical diagnosis of STGD1, referred from six Portuguese centers. All patients underwent a complete ophthalmological examination complemented by color fundus photography (CFP), fundus autofluorescence (FAF), optical coherence tomography (SD-OCT) and, when available, OCT-angiography (OCTA). Proband with confirmed molecular diagnosis, defined as presenting biallelic mutations classified as pathogenic or likely pathogenic in accordance with the guidelines of the American College of Medical Genetics and Genomics, were divided into three groups according their genotype's severity.

**RESULTS:** The study included 122 eyes from 61 patients, 54 of which unrelated. Mean age of onset (AO) and mean disease duration were 16.64±12.87 and 20.04±15.21 years, respectively. Confirmed molecular diagnosis was obtained for 26/38 families with available genetic results (diagnostic yield of 68.42%), with the c.1804C>T (p.Arg602Trp) missense variant being the most prevalent (8/26). The less severe genotype group (Group C) was the most frequent (14/26), with



a mean AO slightly superior, not statistically significant, to the other groups (B and A). The most frequent CFP pattern was central atrophy with macular and/or peripheral flecks (56 eyes), followed by multiple extensive atrophic changes (n=40). On FAF, 21.05% of the eyes showed a homogeneous background with localized central hypoAF (pattern 1), with the remaining distributing equally through patterns 2 (heterogeneous background of hypo/hyperAF foci and localized central hypoAF) and 3 (multiple areas of hypoAF in a heterogeneous background). Worse visual acuity significantly correlated with advanced CFP and FAF patterns (both  $p<0.001$ ), reduced central macular thickness ( $p=0.017$ ), larger foveal avascular zone ( $p<0.001$ ), reduced density of the superficial ( $p<0.001$ ) and deep capillary plexuses ( $p=0.017$ ), and increased area of choriocapillaris atrophy ( $p=0.007$ ).

**CONCLUSION:** This study describes the phenotypic and genotypic spectrum of STGD1 in a multicenter Portuguese cohort, revealing a satisfactory detection rate of disease-causing genotypes. The qualitative and quantitative imaging features presented a strong correlation with visual acuity and disease progression and may represent important outcome measures in the evaluation of new therapeutic targets.

**KEYWORDS:** Genetic Testing; Genotype; Phenotype; Retinal Dystrophies; Stargardt Disease.

## RESUMO

**INTRODUÇÃO:** O nosso objetivo foi caracterizar os achados moleculares e de imagiologia multimodal numa população portuguesa com doença de Stargardt (STGD1).

**MÉTODOS:** Estudo transversal, multicêntrico que incluiu doentes consecutivos com diagnóstico clínico de STGD1, provenientes de seis centros nacionais. Todos os doentes foram submetidos a um exame oftalmológico completo complementado por imagiologia multimodal - retinografia, autofluorescência do fundo (FAF), tomografia de coerência ótica (SD-OCT) e, quando disponível, angiografia por OCT (OCTA). Indivíduos com confirmação molecular, definida pela presença de mutações bialélicas classe IV ou V, foram divididos em 3 grupos de acordo com a gravidade do respetivo genótipo.

**RESULTADOS:** Foram incluídos 122 olhos de 61 doentes, 54 dos quais sem relação de parentesco. A idade média de início (AO) e a duração média da doença foram  $16,64\pm 12,87$  e  $20,04\pm 15,21$  anos, respetivamente. O diagnóstico molecular foi obtido para 26/38 famílias com estudo genético disponível (rendimento diagnóstico 68,42%), sendo a variante *missense* c.1804C>T (p.Arg602Trp) a mais prevalente (8/26). O grupo de genótipo menos grave (Grupo C) foi o mais frequente (14/26), com uma média de AO ligeiramente superior aos grupos A e B, embora não estatisticamente significativa. Na retinografia, o padrão mais frequente foi o de atrofia central com manchas amareladas maculares e/ou periféricas (56 olhos). Na FAF, 21,05% dos olhos apresentaram hypoAF central num fundo homogéneo (padrão 1), com os restantes distribuindo-se equitativamente pelos padrões 2 (focos de hypo/hiperAF e hypoAF central distribuídos por um fundo heterogéneo) e 3 (áreas múltiplas de hypoAF num fundo heterogéneo). Uma pior acuidade visual correlacionou-se com padrões avançados na retinografia e FAF ( $p<0,001$  para ambos), espessura macular central reduzida ( $p=0,017$ ), maior zona avascular da fóvea ( $p<0,001$ ), menor densidade vascular do plexos capilares superficial ( $p<0,001$ ) e profundo ( $p=0,017$ ) e maior área de atrofia coriocalilar ( $p=0,007$ ).

**CONCLUSÃO:** Este estudo descreve o espectro fenotípico e genotípico de uma coorte portuguesa multicêntrica com STGD1. As características qualitativas e quantitativas dos exames de imagem analisados apresentaram forte correlação com a acuidade visual e progressão da doença, podendo representar importantes meios de análise de resultados na avaliação de novos alvos terapêuticos.

**PALAVRAS-CHAVE:** Distrofias da Retina; Doença de Stargardt; Estudo Genético; Genótipo; Fenótipo.

## INTRODUCTION

Stargardt disease (STGD1, OMIM: 248200) is the most frequent macular juvenile dystrophy, with an estimated prevalence of 1:8 000 to 1:10 000.<sup>1,5</sup> It is caused by biallelic mutations in the adenosine triphosphate (ATP)-binding cassette A4 gene (*ABCA4*), which encodes a transmembrane protein involved in active transport of retinoids from photoreceptors to retinal pigment epithelium (RPE). Failure of this transport results in accumulation of cytotoxic lipofuscin fluorophores, namely A2E, in the RPE cells, leading to their dysfunction and death, with subsequent photoreceptor (PR) cell loss.<sup>6,7</sup> This explains two of the three hallmarks of the disease on fundoscopic examination: macular atrophy due to RPE and PR loss, which can expand beyond the posterior pole at late disease stage, and the yellowish white flecks that result from localized accumulation of RPE lipofuscin. The third fundoscopic finding that completes the diagnostic triad of STGD1 corresponds to peripapillary sparing of the above-mentioned retinal changes.<sup>1,6,7</sup>

Classically, patients present with bilateral central vision loss, secondary to macular atrophy, usually becoming apparent at early adolescence/young adulthood and evolving with gradual vision loss over disease progression.<sup>1,2,5,7</sup> However, both age of onset and the disease course vary extensively, and genotype-phenotype correlations have been established, with worse genotypes resulting in earlier onset and more rapid progression.<sup>1,3,5,7,8</sup>

STGD1 is inherited following an autosomal recessive pattern,<sup>1,7</sup> with a carrier frequency for potentially pathogenic *ABCA4* alleles of 1:20.<sup>3,7</sup> To date, > 1200 disease-causing variants have been reported,<sup>5,6</sup> with the majority consisting of missense mutations.<sup>5</sup> Grouping of these variants in severity categories according to their presumed functional effect has been proposed, varying from deleterious (stop-gained or frameshift insertion/deletion (indel)) to mild effect (missense or in-frame indel) in *ABCA4* activity.<sup>1-3,7</sup>

Visual function and disease progression have not only been correlated with genotype, but also with structural features, through extensive evaluation using multimodal retinal imaging comprising fundus autofluorescence (FAF), optical coherence tomography (OCT) and OCT-angiography (OCTA).<sup>1,2,4,6,8-13</sup> Typical findings on FAF include hyperautofluorescent (hyperAF) foci corresponding to the yellowish-white flecks, and hypoautofluorescent (hypoAF) areas at the level of RPE atrophy.<sup>1,4,6,9-12</sup> The hallmark on OCT is the general thinning in the central retina.<sup>4,10</sup> Regarding OCTA, central choriocapillaris atrophy, larger foveal avascular zone and reduced density of retinal capillary plexus have been reported in association with later stages in the disease course.<sup>4,10,13</sup>

The aim of this study was to characterize the molecular and multimodal retinal imaging findings in a large cohort of clinically diagnosed STGD1 Portuguese patients from six centers. Additionally, genotype-phenotype and structural-functional correlations were evaluated.

## MATERIAL AND METHODS

### STUDY DESIGN AND PATIENT SELECTION

We conducted a multicenter, cross sectional cohort study including 122 eyes from 61 consecutive patients diagnosed with STGD1 in the following Portuguese centers: Centro Hospitalar e Universitário de Coimbra (CHUC), Instituto de Oftalmologia Dr. Gama Pinto (IOGP), Centro Hospitalar e Universitário de Lisboa Norte (CHULN), Centro Hospitalar e Universitário do Porto (CHUP), Centro Hospitalar de Lisboa Ocidental (CHLO) and Hospital de Braga (HB). Sample distribution across these centers is shown in Fig. 1.

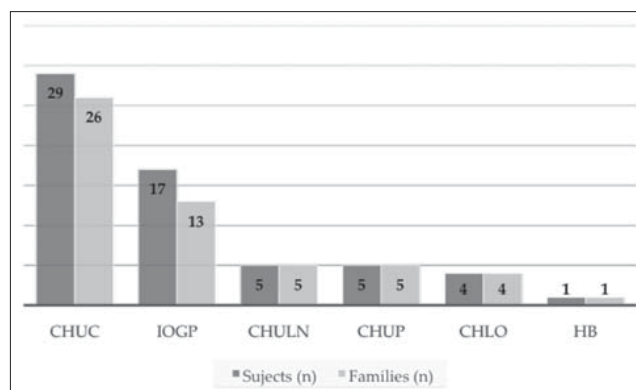


Figure 1. Sample distribution across the six Portuguese centers which contributed to the study.

CHUC – Centro Hospitalar e Universitário de Coimbra; IOGP – Instituto de Oftalmologia Dr. Gama Pinto; CHULN – Centro Hospitalar e Universitário de Lisboa Norte; CHUP – Centro Hospitalar e Universitário do Porto; CHLO – Centro Hospitalar de Lisboa Ocidental; HB – Hospital de Braga

The study was approved by the local Ethics Committees and followed the tenets of the Declaration of Helsinki for biomedical research. Written informed consent was obtained for every included subject.

Inclusion criteria consisted in a clinical diagnosis of STGD1 ± genetic testing. The clinical diagnosis was based on patient history of central vision loss as the main symptom, along with family history compatible with autosomal recessive inheritance, and typical changes on dilated fundus examination (macular RPE atrophy, yellowish-white flecks and peripapillary sparing). Patients with significant media opacities, unstable fixation, or those with any possibly confounding vitreoretinal disease were excluded.

### GENETIC TESTING

For probands with available molecular results at the time of data collection (n=47), the genetic testing consisted in either eye-gene enriched panel-based next-generation sequencing (NGS) or whole exome sequencing (WES), complemented by multiplex ligation-dependent probe amplification (MLPA) when deemed necessary. Peripheral blood samples were collected according to the manufacturer's specifications for whole-blood

DNA extraction. Whenever possible, segregation analysis was performed in family members, whose samples were analyzed by Sanger sequencing to search for the variants detected in their respecting probands. Genetic counselling provided by a medical geneticist was granted to all subjects.

The diagnostic yield was calculated from the number of families with confirmed disease causing genotypes, consisting in the presence of two mutating alleles whose variants were classified as pathogenic (class V) or likely pathogenic (class IV) in accordance with the guidelines of the American College of Medical Genetics and Genomics.<sup>14,15</sup>

Patients with confirmed molecular diagnosis were further divided into 3 groups according the genotype classification proposed by Fujinami *et al*<sup>1</sup>: Group A included patients harboring 2 predictive deleterious (nonsense, splice-site or frameshift) variants; Group B included subjects presenting one deleterious and one missense or in-frame indel variant; Group C included patients presenting biallelic missense/in-frame indels variants.

## CLINICAL/DEMOGRAPHIC FEATURES

A detailed medical history was obtained for every patient and included natural history, age at diagnosis, age of onset of symptoms, disease duration, family history and the presence of consanguinity in the family.

The age of onset was defined as the age at which the visual loss was noted by the patient or his carriers, in case of childhood onset.

The disease duration was calculated as the difference between the subject's age at the date this study was conducted and the age of onset.

## OPHTHALMIC EXAMINATION, MULTIMODAL IMAGING AND GRADING

All patients underwent a comprehensive ophthalmologic examination including: (1) best-corrected visual acuity (BCVA), converted to equivalent ETDRS letters (for counting finger (CF) and hand movement (HM) was attributed the value 0 ETDRS); (2) dilated slit-lamp anterior segment and fundus biomicroscopy; (3) multimodal imaging comprising color fundus photography (CFP), blue-light FAF imaging, spectral-domain OCT (SD-OCT), and OCTA when available.

CFP and FAF aspects were divided into four and three groups, respectively, according the classification proposed by Fujinami *et al*<sup>1</sup>: CFP grade 1: normal fundus; CFP grade 2: macular and/or peripheral flecks without central atrophy; CFP grade 3a: central atrophy without flecks; CFP grade 3b: central atrophy with macular and/or peripheral flecks; CFP grade 3c: paracentral atrophy with macular and/or peripheral flecks, without central atrophy; CFP grade 4: multiple extensive atrophic changes of the RPE, extending beyond the vascular arcades. Regarding AF: grade 1: localized low AF signal at the fovea surrounded by a homogeneous background, with/without perifoveal foci of high or low AF signal; grade 2: localized low AF signal at the macula surrounded by a heterogeneous background, and widespread foci

of high or low AF signal extending anterior to the vascular arcades; grade 3: multiple areas of low AF signal at the posterior pole with a heterogeneous background, with/without foci of high or low AF signal. The presence of peripapillary sparing on FAF examination was also noted.

On SD-OCT, photoreceptor ellipsoid zone (EZ) preservation in central retina was evaluated and divided into the three categories described by Liu, Fujinami and associates<sup>16</sup>: Category 1: preserved EZ in the fovea; Category 2: loss of EZ in the fovea; Category 3: extensive loss of EZ. The central macular thickness (CMT), corresponding to the distance (expressed in micrometer,  $\mu\text{m}$ ) between the inner limiting membrane to the inner border of the RPE, was also measured using SD-OCT.<sup>1</sup>

On OCTA, 6x6-mm high-definition (400x400) scans were obtained for measuring the following parameters: (1) macular vascular density of superficial (SMVD) and deep capillary plexus (DMVD); (2) central choriocapillaris atrophy (CCA); (3) foveal avascular zone (FAZ). The parameters (2) and (3) were manually outlined through the free-hand selection tool on the OCTA equipment, and their dimension was expressed as squared millimeters ( $\text{mm}^2$ ).<sup>4,17</sup>

## STATISTICAL ANALYSIS

Statistical analysis was performed using the SPSS program (SPSS Statistics, version 15 for Windows, SPSS Inc., IBM, Somers, NY). Descriptive analysis was performed for all study variables. Continuous variables were recorded as mean and standard deviation (SD) values with minimum and maximum when appropriate, whereas categorical variables were recorded as absolute and relative frequencies. Normality was evaluated through the Kolmogorov-Smirnov test for each variable. Comparison between continuous variables was performed using the T-Student test, when parametric, and Mann-Whitney U test, when non-parametric distribution was obtained. Categorical variables were tested for association using chi-square test. Pearson's and Spearman's bivariate correlation tests were used to studying correlations. Regression analysis was performed using genotype grouping and adjusting for disease duration to predict BCVA (using ETDRS letters). *P* values less than 0.05 were considered statistically significant.

## RESULTS

### DEMOGRAPHIC AND CLINICAL DATA

A total of 61 patients (122 eyes), 54 of which unrelated, were enrolled in the study, coming from 12 of the 18 Portuguese Continental Districts. Demographic and clinical data of the study population are summarized in Table 1. Almost half (25/61) presented a positive family history, and 9 were from consanguineous families. The mean age of onset (AO) was  $16.64 \pm 12.87$  years, range 3-52, with more than half (33/61) reporting an AO before 18 years, while only 12 initiated symptoms after 30 years. The mean age at diagnosis (AD) was  $27.21 \pm 16.01$ , with a maximum time between AO and AD of 38 years in one patient.

The disease duration ranged from 1 to 52 years, with an average of  $20.04 \pm 15.21$  years.

**Table 1. Demographic and clinical data of the study population.**

Eyes/Patients (n)	122/61
Female patients (n; %)	33; 54.10
<b>Age</b>	
Mean (years)	41.28±17.29
Range (years)	9-78
Pediatric patients (age <18 years) (n)	4
<b>Families (n)</b>	
Mean age at diagnosis (years)	27.21±16.01
<b>Age of onset</b>	
Mean age of onset (years)	16.64±12.87
Onset before 18 years (n; %)	33; 54.10
Onset after 30 years (n; %)	12; 19.67
<b>Disease Duration</b>	
Mean disease duration (years)	20.04±15.21
Disease duration < 10 years (n;%)	18; 11.00
Disease duration > 20 years (n;%)	28; 45.90
<b>Mean visual acuity (ETDRS letters)</b>	
Right eye	30.00
Left eye	30.95

AF – autofluorescence; OCT – optical coherence tomography; EZ – photoreceptor ellipsoid zone.

The mean visual acuity was 30.00 and 30.95 ETDRS letters in the right and left eye, respectively (ranging from 0 to 75 letters in both eyes). Worse visual acuity significantly correlated with a longer disease duration ( $p<0.001$ ).

## MULTIMODAL RETINAL IMAGING

Frequency of CFP, FAF and OCT patterns across the study population is represented in Table 2, as well as the summarized data collected for continuous variables evaluated on SD-OCT (CMT) and OCT-A (macular vascular density of superficial and deep capillary plexus, central choriocapillaris atrophy and foveal avascular zone).

Fifty-six eyes were classified into grade 3b on CFP, the most frequently observed pattern (45.90%), followed by grade 4 which was attributed to 31.15% (40/122) of the eyes. Thirteen eyes (7 patients) presented typical flecks but no central atrophy (grade 2). None of the eyes showed normal fundus appearance (pattern 1), and only two corresponded to grade 3c.

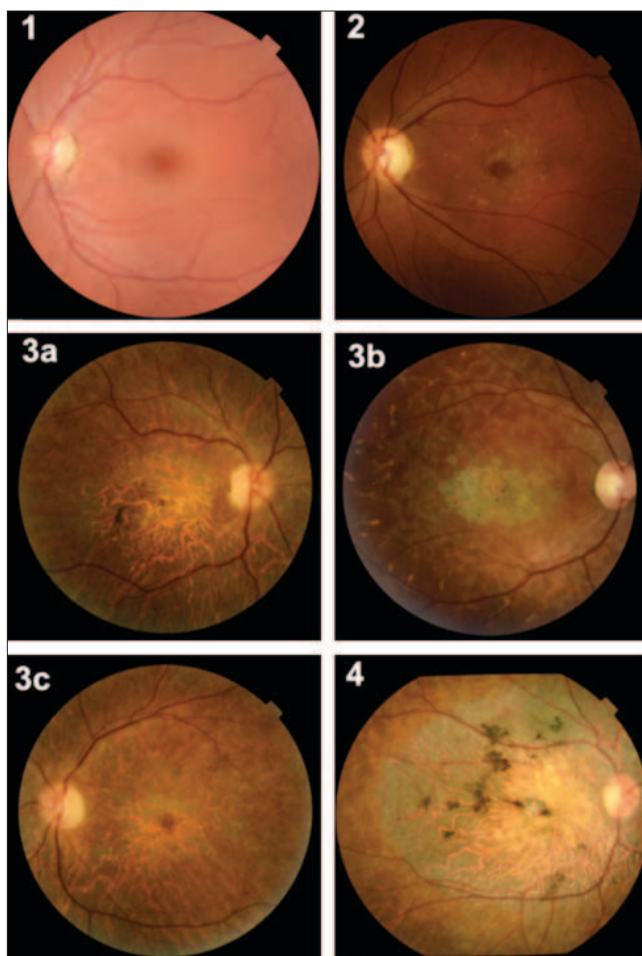
In eyes with available FAF imaging (n=114), grade 1 was the least common (24 eyes), while grades 2 and 3 were equally observed in the remaining eyes. Peripapillary sparing on AF was present in 75.44% (86/114) of the eyes.

Examples of different CFP and FAF grades, observed in some of our probands, are represented in Figs 2 and 3, respectively.

**Table 2. Retinal imaging findings and their statistical analysis in the study population.**

Retinal imaging	
Color Fundus Photography	n (%)
Grade 1: Normal	0 (0)
Grade 2: Macular and/or peripheral flecks without central atrophy	13 (10.66)
Grade 3	69 (56.56)
Grade 3a: Central atrophy without flecks	11 (9.02)
Grade 3b: Central atrophy with macular and/or peripheral flecks	56 (45.90)
Grade 3c: Paracentral atrophy with macular and/or peripheral flecks without central atrophy	2 (1.64)
Grade 4: Multiple extensive atrophic changes of the RPE, extending beyond vascular arcades	40 (32.79)
Fundus Autofluorescence	n (%)
Grade 1: Localized low AF signal at the fovea surrounded by a homogeneous background with/without perifoveal foci of high or low signal	24 (21.05)
Grade 2: Localized low AF signal at the macula surrounded by a heterogeneous background and widespread foci of high or low AF signal extending anterior to the vascular arcade	45 (39.47)
Grade 3: Multiple areas of low AF signal at posterior pole with a heterogeneous background and/or foci of high or low signal	45 (39.47)
Optical coherence tomography	n (%)
Category 1: Preserved EZ in the fovea	7(6.14)
Category 2: Loss of EZ in the fovea	35 (30.70)
Category 3: Extensive loss of EZ	72 (63.16)
OCT/OCTA quantitative features	Mean±SD
Central macular thickness (µm)	120.24±48.60
Macular vascular density of superficial capillary plexus (%)	45.16±5.38
Macular vascular density of deep capillary plexus (%)	42.82±4.38
Central choriocapillaris atrophy (mm <sup>2</sup> )	12.86±12.54
Foveal avascular zone (mm <sup>2</sup> )	1.10±0.82

AF – autofluorescence; EZ – photoreceptor ellipsoid zone; OCT – optical coherence tomography; OCTA – OCT – angiography; SD – standard deviation;



**Figure 2.** Examples of the color fundus photography grades. (1) normal fundus; (2) macular and/or peripheral flecks without central atrophy; (3a) central atrophy without flecks; (3b) central atrophy with macular and/or peripheral flecks; (3c) paracentral atrophy with macular and/or peripheral flecks, without central atrophy; (4) multiple extensive atrophic changes of the RPE, extending beyond the vascular arcades

Regarding SD-OCT (n=114), extensive loss of the EZ (category 3) was the most frequent finding (63.16%; 72 eyes). Only 7 eyes (4 patients) showed foveal EZ preservation (category 1). In this subgroup, the AO was  $26.00 \pm 12.69$  (range 5-37) and the disease duration was >10 years except for one

proband (6 years). All patients excluding one had genetically solved disease (Genotype 3); in the molecular unsolved subject, for whom no clinically significant variants were found, an asymmetry between eyes was noted (only one eye showed foveal EZ sparing), and the age of onset was 5 years (against the remaining patients in that group, who all reported first symptoms around age of 30 years).

Intereye symmetry was present in all patients on blue-light FAF. On the other hand, 3 patients showed different sub-patterns inside grade 3 between OD and OS on CFP and 2 patients had intereye asymmetry on SD-OCT.

There were significant differences regarding multimodal imaging findings and disease duration, with more advanced grades on CFP, FAF and OCT correlating with longer disease duration ( $p < 0.001$  for all three imaging methods). The same was true for BCVA, with more severe vision loss significantly associated to worse CFP ( $p < 0.001$ ), FAF ( $p < 0.001$ ), and OCT ( $p < 0.001$ ) grades.

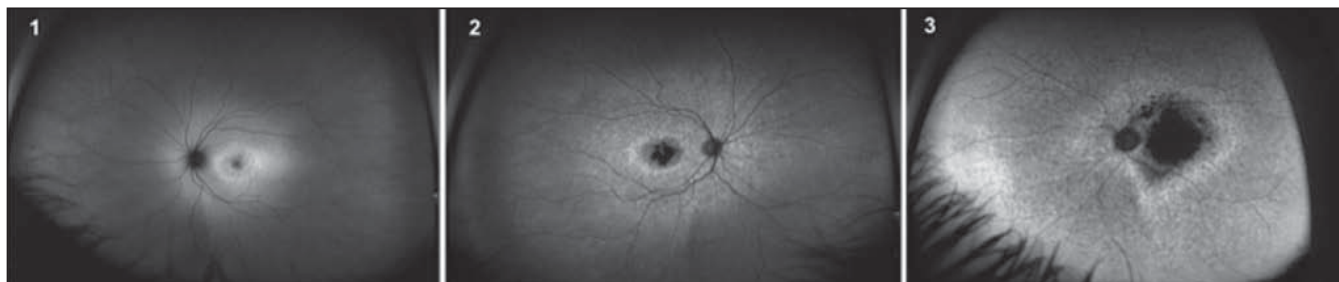
Mean CMT was  $120.24 \pm 48.60 \mu\text{m}$ . Thinner measurements were significantly associated with worse BCVA ( $p = 0.017$ ) but did not show correlation with disease progression ( $p = 0.210$ ).

For the subset of eyes with OCTA data (n=34), all the evaluated parameters (SMVD, DMVD, FAZ and CCA) showed a significant correlation with BCVA, with less ETDRS letters corresponding to reduced SMVD ( $p < 0.001$ ) and DMVD ( $p = 0.017$ ), larger FAZ ( $p < 0.001$ ), and increased CCA ( $p = 0.007$ ). However, only CCA proved to significantly correlate with disease duration ( $p = 0.026$ ).

### ABCA4 VARIANTS

Confirmed molecular diagnosis was obtained for 26/38 families with available genetic results, for a diagnostic yield of 68.42%. In other 4 families, the probands had a disease-causing variant with one variant of uncertain significance in trans, and, hence, it was not possible to genetically confirm the diagnosis. For the remaining 8 families, no clinically significant variants were found in the probands with available genetic results.

In total, 25 pathogenic/likely pathogenic variants were identified, distributed across 56 alleles (26 families with pathogenic/likely pathogenic variants in the two alleles, and 4 families with confirmed disease causing variant in only one allele). The characterization of these variants is presented in Table 3. The majority of mutations were classi-



**Figure 3.** Examples of the fundus autofluorescence grades observed in patients of our cohort. (1) localized low AF signal at the fovea surrounded by a homogeneous background, with/without perifoveal foci of high or low AF signal; (2) localized low AF signal at the macula surrounded by a heterogeneous background, and widespread foci of high or low AF signal extending anterior to the vascular arcades; (3) multiple areas of low AF signal at the posterior pole with a heterogeneous background, with/without foci of high or low AF signal.

**Table 3.** ABCA4 variants found in the 38 Portuguese families with available genetic results.

Nucleotide	Protein	Functional effect	Clinical significance	Families (n)	Alleles (n)	Zygoty
c.1804C>T	p.Arg602Trp	Missense	Pathogenic	8	9	hz, CHz
c.3210_3211dup	p.Ser1071Cysfs*14	Frameshift	Pathogenic	4	5	hz, CHz
c.5882 G>A	p.Gly1961Glu	Missense	Pathogenic	4	4	CHz
c.4720G>T	p.Glu1574*	Stopgain	Pathogenic	4	4	CHz
c.32T>C	p.Leu11Pro	Missense	Likely pathogenic	3	4	hz, CHz
c.4139C>T	p.Pro1380Leu	Missense	Likely pathogenic	3	3	CHz
c.286A>G	p.Asn96Asp	Missense	Likely pathogenic	2	3	hz, CHz
c3113C>T	p.Ala1038Val	Missense	Likely pathogenic	2	2	CHz
c.5327C>T	p.Pro1776Leu	Missense	Pathogenic	2	2	CHz
c.5044_5058del	p.Val1682_Val1686del	In-frame deletion	Pathogenic	2*	2*	CHz*
c.464C>T	p.?	Splice site	Pathogenic	1	6	hz
c.634C>T	p.Arg212Cys	Missense	Likely pathogenic	1	2	hz
c.5461-10T>C	p.?	Splice site	Pathogenic	1	2	CHz
c.4926C>G	p.Ser1642Arg	Missense	Likely pathogenic	1*	1*	CHz*
c.6089G>A	p.Arg2030Gln	Missense	Likely pathogenic	1	1	CHz
c.6079C>T	p.Leu2027Phe	Missense	Likely pathogenic	1	1	CHz
c.6104T>C	p.Leu2035Pro	Missense	Likely pathogenic	1	1	CHz
c.6088C>T	p.Arg2030Ter	Stopgain	Pathogenic	1	1	CHz
c.4328G>A	p.Arg1443His	Missense	Pathogenic	1	1	CHz
c.2588G>C	p.Gly863Ala	Missense	Likely pathogenic	1	1	CHz
c.3386G>T	p.Arg1129Leu	Missense	Likely pathogenic	1	1	CHz
c.6320G>A	p.(Arg2107His)	Missense	Likely pathogenic	1	1	CHz
c.834del	p.Asp279Ilefs*21	Frameshift deletion	Likely pathogenic	1	1	CHz
c.(658_766) (768+199_769-1)del	p.?	Deletion	Likely pathogenic	1	1	CHz
c.5196+1137G>A	p.?	Intronic	Likely pathogenic	1	1	CHz

hz – homozygosity; CHz – compound heterozygosity

\*Variants found in complex alleles

fied as missense, representing 76.00% (19/25) of all the variants. The most frequent mutations found in our cohort were c.1804C>T (p.Arg602Trp) (9/56 alleles), c.464C>T (p.?) (6/56 alleles), c.3210\_3211dup (p.Ser1071Cysfs\*14) (5/56), c.5882 G>A (p.Gly1961Glu) (4/56), c.4720G>T (p.Glu1574\*) (4/56) and c.32T>C (p.Leu11Pro) (4/56). One proband presented a complex allele, with the variant c.5044\_5058del (p.Val1682\_Val1686del) and c.4926C>G (p.Ser1642Arg) in cis and the c.1804C>T(p.Arg602Trp) in trans.

## GENOTYPE GROUPS

For probands with genetically solved SGDT1 (32 subjects, 26 families), the genotype group C (biallelic missense/in-frame variants) was the most frequent, with 16/30 patients (14/26 families, 53.84%). Only 5 patients (3 families, 11.53%) presented biallelic deleterious variants (Group A). The remaining 11 subjects (9 families, 34.62%) were included in group B, harboring one deleterious and one missense/in-frame variant.

Group A presented a mean age of onset of 8.8±1.33 years, inferior to that calculated for group B (13.45±7.82 years), which in turn was inferior to Group C (15.94±12.13 years). However, these differences were not statistically significant ( $p=0.270$ ).

A multiple linear regression was conducted to predict BCVA based on genotype and disease duration. A significant model was found ( $F(2,53)=13.25$ ,  $p<0.001$ ), with an  $R^2$  of 0.333. Even though disease duration was a significant predictor of lower BCVA ( $p<0.001$ ), genotype was not ( $p=0.303$ ).

## DISCUSSION

By combining data from 6 national Ophthalmology Departments, this study reports molecular and multimodal imaging findings from a large Portuguese cohort with STGD1.

Deep phenotyping by means of multimodal retinal imaging has shown to be of crucial value, since it provides information regarding disease natural history and prognosis.<sup>1,8,9,11,12,16,18</sup> In our study, almost 80% of the eyes presented

macular atrophy associated with macular/peripheral flecks (grade 3b), or multiple extensive atrophic changes of the RPE extending beyond vascular arcades (grade 4). CFP patterns significantly correlated with disease duration. This is in accordance with other studies that evaluated adult populations with STGD1.<sup>2,1</sup> Absence of central macular atrophy was present in only about 10% of the eyes.<sup>6</sup> Foveal sparing is a rare finding especially in cohorts with an earlier age of onset,<sup>1,8,16</sup> which generally is related with a worse phenotype.<sup>1,7,8,16</sup> It has been associated with less severe disease and later disease onset.<sup>1,6</sup> The mean AO in our cohort (16.64 years) was inferior to that reported by other authors (approximately 19 years),<sup>2,6,19</sup> and more than a half of the study population reported onset of symptoms before 18 years old. The earlier AO in our study could probably explain the small percentage of eyes presenting foveal sparing, which may also be supported by the later mean AO in the subgroup of patients with foveal EZ preservation on SD-OCT. Regarding FAF patterns, patterns 2 and 3 were observed with the same frequency in our cohort, while pattern 1 was the least frequent (~25% eyes). Progression across FAF grades over time has been reported,<sup>1,6,12</sup> which explains the positive correlation between FAF patterns and disease duration that we describe. Disease duration also demonstrated a positive correlation with the extension of EZ loss on SD-OCT. Interestingly, this was not the case for CMT. Finally, OCTA has been increasingly used to analyze the retinal and choroidal vasculatures in all types of retinal diseases, including IRDs.<sup>4,13</sup> Our findings suggest a complex vascular impairment and confirms that important changes occur in the different retinal vascular plexuses and in the choriocapillaris. We have shown that reduced SMVD and DMVD, increased FAZ and larger CCA atrophy in these patients are significantly associated with worse BCVA. Additionally, a larger CCA area significantly correlated with longer disease duration.

It is important to note that FAF and SD-OCT imaging was not possible to classify in 4 patients (8 eyes) due to insufficient image quality and/or lack of collaboration. Only one center provided OCTA, explaining the small percentage of patients with available results. These aspects constitute an important limitation of our study regarding deep phenotype characterization.

By using clinically-oriented genetic testing based on targeted NGS, this study revealed a total of 26 pathogenic/likely pathogenic variants in the *ABCA4* gene in a group of 26 Portuguese families, with the great majority (76.00%) being functionally classified as missense variants. This is in accordance with previous reports.<sup>2,3,7,20</sup>

The variant c.1804C>T (p.Arg602Trp) was the most prevalent in our cohort, observed in 8/26 families (30.77%). It was reported as the fourth more common mutation in a large Spanish cohort,<sup>3</sup> responding for 5% of the families studied, and has been described as a frequent mutation in Caucasians,<sup>3,21</sup> as well as in the South African population.<sup>22</sup> Interestingly, this variant was also the most prevalent variant observed in a Taiwan cohort.<sup>18</sup> It is reported to be a severe missense variant associated with rapid progression.<sup>18</sup> However, due to the small number of probands with available genetic results and to the cross-sectional design of our study,

it was not possible to ascertain these genotype-phenotype correlations.

On the other hand, the most prevalent mutation in the above mentioned Spanish study, that englobed 506 families with biallelic *ABCA4* pathogenic variants, was the p.(Arg1129Leu),<sup>3</sup> which seems to have a high prevalence in Hispanic populations, since it was also one of the most frequent mutations verified in a Argentinean cohort.<sup>2</sup> In our study, however, it was identified in only one family.

The mutation c.5882 G>A (p.Gly1961Glu) is the most common among STGD1 patients from different ethnic backgrounds, with an allele frequency in European population of ~0.4%<sup>7</sup> and with a variable frequency of 6.5%-21% in diverse STGD cohorts.<sup>2</sup> In a large international cohort, the ProgStar study report 8, conducted by Fujinami *et al*,<sup>19</sup> p.(Gly1961Glu) was the most prevalent mutation, with a frequency of 15%. In the present study, it was observed in 4/26 families (15.38%).

In one proband, the most frequently reported intronic variant in *ABCA4*, the c.5196+1137G>A, was found in association with one deleterious variant in trans. However, this patient presented a relatively mild phenotype, with a later age of onset (27 years) and relatively preserved BCVA (50 ETDRS letters OU). This is in keeping with previous reports, that consider that intronic variant of intermediate effect, producing a significant milder phenotype when in trans with null mutation (when compared with two null alleles).<sup>23</sup>

Regarding genotype groups, we included 11.53% of families in Group A, 34.62% in Group B and 53.84% in Group C. These results are in accordance with the findings presented by Fujinami *et al* in the ProgStar study report 8, with approximately half of probands belonging to Group C (49.8%).<sup>19</sup> In a Chinese adult cohort,<sup>16</sup> with an earlier mean AO (10.0 years) and in a pediatric cohort<sup>1</sup> a higher proportion of families was included in Group A (around 20%) and the Genotype B was the most frequent (approximately 45%). These findings support the hypothesis that the distribution of deleterious variants in a STGD1 cohort depends on the age of onset, with worse genotypes resulting in an earlier AO and worse phenotypes.<sup>1,3,7,16</sup>

In previous studies, a statically significant difference was noted between genotype groups and mean age of onset.<sup>1,3</sup> Also, differences in BCVA have been shown to exist between genotype groups, with group A showing the worse BCVA for the same disease duration and age.<sup>16</sup> Although an increase in mean AO from group A to group C was observed in our cohort, this was not statistically significant. Additionally, when considering disease duration, BCVA did not differ across genotype groups. This may be explained by three possible bias, which represent important limitations of our study: (1) the small number of families with available genetic testing results may not be representative of the population, thus limiting the statistical power to establish those correlations; (2) assigning functional effect to a mutation was not always straightforward, especially for missense alleles and some variants in splice sites – this has been appointed in other studies as a general limitation of the segregation trough genotype groups, since the functional consequences not always correlate exactly with resulting disease phenotypes and progression<sup>7</sup>; and (3) the exact AO cannot be easily

determined, as many patients (particularly children) may be unaware of their visual impairment, and this turns especially difficult when trying to provide it in retrospective recall.

Besides the above mentioned, other significant limitations should be noted. First, a significant part of our cohort has not been genetically tested (14/52 families), which does not allow us to exclude potential phenocopies. These account for 10%-15% of all cases of *ABCA4*-associated phenotypes.<sup>7</sup> Second, 4 patients harbored a variant of uncertain significance for whom family segregation analysis was not enough to reclassify the variant's pathogenicity. Accordingly, these patients could not be included in a genotype group. Third, the cross-sectional design does not provide information regarding disease natural history and progression.

## CONCLUSION

To the best of our knowledge, this is the largest study to describe the phenotypic and genotypic spectrum of STGD1 in a multicentric Portuguese cohort, revealing a satisfactory detection rate of disease-causing genotypes. Deep phenotyping using multimodal retinal imaging (CFP, FAF, OCT and OCTA) was shown to be of clinical utility in the evaluation of these patients. Imaging biomarkers evaluated here presented a strong correlation with BCVA and disease progression. These qualitative and quantitative imaging features may represent important outcome measures in the efficacy evaluation of new therapeutic targets. Due to the reduced number of probands with available genetic results, our study was not powerful enough to establish genotype-phenotype correlations. Longitudinal studies englobing larger samples with genetically confirmed diagnosis are warranted to assess genotype-phenotype correlations and predict disease progression, based not only on molecular aspects but also on deep phenotyping by means of multimodal retinal imaging.

## PRESENTATIONS AND AWARDS

This study was awarded "Best Scientific Poster Presentation" at "Reunião do Grupo Português de Retina e Vítreo", October 15-16th 2021, Coimbra, Portugal.

## CONTRIBUTORSHIP STATEMENT / DECLARAÇÃO DE CONTRIBUIÇÃO:

SG: Colheita e análise de dados; elaboração do manuscrito (escrita e formatação).

CS, SV-P, AM, MC, KS e ALS: Colheita de dados; revisão do manuscrito.

MS: Colheita de dados.

JS, JM, RS e LC-S: Seleção da amostra; revisão do manuscrito.

JPM: Seleção da amostra; , elaboração e revisão do manuscrito.

## RESPONSABILIDADES ÉTICAS

**Conflitos de Interesse:** Os autores declaram a inexistência de conflitos de interesse na realização do presente trabalho.

**Fontes de Financiamento:** Não existiram fontes externas de financiamento para a realização deste artigo.

**Confidencialidade dos Dados:** Os autores declaram ter seguido os protocolos da sua instituição acerca da publicação dos dados de doentes.

**Proteção de Pessoas e Animais:** Os autores declaram que os procedimentos seguidos estavam de acordo com os regulamentos estabelecidos pelos responsáveis da Comissão de Investigação Clínica e Ética e de acordo com a Declaração de Helsínquia revista em 2013 e da Associação Médica Mundial.

**Proveniência e Revisão por Pares:** Não comissionado; revisão externa por pares.

## ETHICAL DISCLOSURES

**Conflicts of Interest:** The authors have no conflicts of interest to declare.

**Financing Support:** This work has not received any contribution, grant or scholarship

**Confidentiality of Data:** The authors declare that they have followed the protocols of their work center on the publication of data from patients.

**Protection of Human and Animal Subjects:** The authors declare that the procedures followed were in accordance with the regulations of the relevant clinical research ethics committee and with those of the Code of Ethics of the World Medical Association (Declaration of Helsinki as revised in 2013).

**Provenance and Peer Review:** Not commissioned; externally peer reviewed.

## REFERENCES

1. Fujinami K, Zernant J, Chana RK, Wright GA, Tsunoda K, Ozawa Y, et al. Clinical and molecular characteristics of childhood-onset Stargardt disease. *Ophthalmology*. 2015;122:326-34. doi: 10.1016/j.ophtha.2014.08.012.
2. Mena MD, Moresco AA, Vidal SH, Aguilar-Cortes D, Obregon MG, Fandiño AC, et al. Clinical and Genetic Spectrum of Stargardt Disease in Argentinean Patients. *Front. Genet.* 2021;12:646058. doi: 10.3389/fgene.2021.646058
3. Del Pozo-Valero M, Riveiro-Alvarez R, Blanco-Kelly F, Aguirre-Lamban J, Martin-Merida I, Iancu IF, et al. Genotype-Phenotype Correlations in a Spanish Cohort of 506 Families With Biallelic *ABCA4* Pathogenic Variants. *Am J Ophthalmol.* 2020;219:195-204. doi: 10.1016/j.ajo.2020.06.027..
4. Battaglia Parodi M, Cicinelli MV, Rabiolo A, Pierro L, Bolognesi G, Bandello F. Vascular abnormalities in patients with Stargardt disease assessed with optical coherence tomography angiography. *Br J Ophthalmol.* 2017;101:780-5. doi: 10.1136/bjophthalmol-2016-308869.
5. Rahman N, Georgiou M, Khan KN, Michaelides M. Macular dystrophies: clinical and imaging features, molecular genetics



- and therapeutic options. *Br J Ophthalmol.* 2020;104:451–460.
6. Fujinami K, Lois N, Mukherjee R, McBain VA, Tsunoda K, Tsubota K, et al. A longitudinal study of Stargardt disease: quantitative assessment of fundus autofluorescence, progression, and genotype correlations. *Invest Ophthalmol Vis Sci.* 2013;54:8181–90. doi: 10.1167/iovs.13-12104.
  7. Cremers FPM, Lee W, Collin RWJ, Allikmets R. Clinical spectrum, genetic complexity and therapeutic approaches for retinal disease caused by ABCA4 mutations. *Prog Retin Eye Res.* 2020;79:100861. doi: 10.1016/j.preteyeres.2020.100861.
  8. Holtan JP, Aukrust I, Jansson RW, Berland S, Bruland O, Gjerde BL, et al. Clinical features and molecular genetics of patients with ABCA4-retinal dystrophies. *Acta Ophthalmol.* 2021;99:e733–e746. doi: 10.1111/aos.14679
  9. Klufas MA, Tsui I, Sadda SR, Hosseini H, Schwartz SD. Ultrawidefield autofluorescence in ABCA4 Stargardt disease. *Retina.* 2018;38:403–15. doi: 10.1097/IAE.0000000000001567.
  10. Arrigo A, Grazioli A, Romano F, Aragona E, Marchese A, Bordato A, et al. Multimodal evaluation of central and peripheral alterations in Stargardt disease: a pilot study. *Br J Ophthalmol.* 2020;104:1234–8. doi:10.1136/bjophthalmol-2019-315148
  11. Müller PL, Gliem M, McGuinness M, Birtel J, Holz FG, Issa PC. Quantitative Fundus Autofluorescence in ABCA4 -related retinopathy – Functional Relevance and Genotype- Phenotype Correlation. *Am J Ophthalmol.* 2021;222:340–50. doi:10.1016/j.ajo.2020.08.042 .
  12. Georgiou M, Kane T, Tanna P, Bouzia Z, Singh N, Kalitzeos A, et al. Prospective Cohort Study of Childhood-Onset Stargardt Disease: Fundus Autofluorescence Imaging, Progression, Comparison with Adult-Onset Disease, and Disease Symmetry. *Am J Ophthalmol.* 2020;211:159–75. doi: 10.1016/j.ajo.2019.11.008.
  13. Jauregui R, Cho A, Lee W, Zernant J, Allikmets R, Sparrow JR, et al. Progressive choriocapillaris impairment in ABCA4 maculopathy is secondary to retinal pigment epithelium atrophy. *Invest Ophthalmol Vis Sci.* 2020;61:13. doi:10.1167/iovs.61.4.13
  14. Richards S, Aziz N, Bale S, Bick D, Das S, Gastier-Foster J, et al. Standards and guidelines for the interpretation of sequence variants: a joint consensus recommendation of the American College of Medical Genetics and Genomics and the Association for Molecular Pathology. *Genet Med.* 2015;17:405–24.
  15. Cornelis SS, Bax NM, Zernant J, Allikmets R, Fritsche LG, den Dunnen JT, et al. In silico functional meta-analysis of 5,962 ABCA4 variants in 3,928 retinal dystrophy cases. *Hum Mutat.* 2017;38:400–8.
  16. Liu X, Meng X, Yang L, Long Y, Fujinami-Yokokawa Y, Ren J, et al. Clinical and genetic characteristics of Stargardt disease in a large Western China cohort: Report 1. *Am J Med Genet C Semin Med Genet.* 2020;1–14. doi:10.1002/ajmg.c.31838.
  17. Samara WA, Say EA, Khoo CT, Higgins TP, Magrath G, Ferenczy S, et al. Correlation of foveal avascular zone size with foveal morphology in normal eyes using optical coherence tomography angiography. *Retina.* 2015;35:2188–95.
  18. Sung YC, Yang CH, Yang CM. Genotypes Predispose Phenotypes—Clinical Features and Genetic Spectrum of ABCA4-Associated Retinal Dystrophies. *Genes.* 2020;11:1421. doi:10.3390/genes11121421
  19. Fujinami K, Strauss RW, Chiang JPW, Audo IS, Bernstein PS, Birch DG, et al. Detailed genetic characteristics of an international large cohort of patients with Stargardt disease: ProgStar study report 8. *Br J Ophthalmol.* 2018;103:390–7. doi: 10.1136/bjophthalmol-2018-312064.
  20. Garces FA, Scortecchi JF, Molday RS. Functional Characterization of ABCA4 Missense Variants Linked to Stargardt Macular Degeneration. *Int J Mol Sci.* 2021;22:185. doi:10.3390/ijms22010185.
  21. Maia-Lopes S, Aguirre-Lamban J, Castelo-Branco M, Riveiro-Alvarez R, Ayuso C, Silva ED. ABCA4 mutations in Portuguese Stargardt patients: identification of new mutations and their phenotypic analysis. *Mol Vis.* 2009;15:584–91.
  22. Roberts L, Nossek CA, Greenberg LJ, Ramesar RS. Stargardt macular dystrophy: Common ABCA4 mutations in South Africa—Establishment of a rapid genetic test and relating risk to patients. *Molecular Vision.* 2012;18:280–9.
  23. Khan M, Arno G, Fakin A, Parfitt DA, Dhooge PPA, Albert S, et al. Detailed Phenotyping and Therapeutic Strategies for Intronic ABCA4 Variants in Stargardt Disease. *Mol Ther Nucleic Acids.* 2020;21:412–27. doi: 10.1016/j.omtn.2020.06.007.



**Corresponding Author/  
Autor Correspondente:**

**Sara Geada**  
Centro Hospitalar e Universitário de  
Coimbra (CHUC)  
Praceta Prof. Mota Pinto  
3000-075 Coimbra, Portugal  
sarageadabatista@gmail.com



ORCID: 0000-0002-6851-6201

ANNEX V

**9.5. Genomic Landscape and Natural History of Sector Retinitis Pigmentosa**

Cortinhal T, Geada S, Neves E, Carvalho AL, Saraiva J, Silva R, Murta J, Marques JP  
Revista Sociedade Portuguesa de Oftalmologia 2022;46(1):25-32.



# Genomic Landscape and Natural History of Sector Retinitis Pigmentosa

## Variabilidade Genómica e História Natural da Retinopatia Pigmentar Setorial

 Telmo Cortinhal<sup>1</sup>,  Sara Geadá<sup>1</sup>,  Emmanuel Neves<sup>1</sup>, Ana Luísa Carvalho<sup>2,3,4</sup>,  Jorge Saraiva<sup>2,4,6</sup>,  Rufino Silva<sup>1,4,5</sup>,  
 Joaquim Murta<sup>1,4,5</sup>,  João Pedro Marques<sup>1,4,5</sup>

<sup>1</sup> Ophthalmology Unit, Centro Hospitalar e Universitário de Coimbra (CHUC), Coimbra, Portugal

<sup>2</sup> Medical Genetics Unit, Centro Hospitalar e Universitário de Coimbra (CHUC), Coimbra, Portugal

<sup>3</sup> University Clinic of Medical Genetics, Faculty of Medicine, University of Coimbra (FMUC), Coimbra, Portugal

<sup>4</sup> Clinical Academic Center of Coimbra (CACC), Coimbra, Portugal

<sup>5</sup> University Clinic of Ophthalmology, Faculty of Medicine, University of Coimbra (FMUC), Coimbra, Portugal

<sup>6</sup> University Clinic of Pediatrics, Faculty of Medicine, University of Coimbra (FMUC), Coimbra, Portugal

**Recebido/Received:** 2021-10-05 | **Aceite/Accepted:** 2021-12-07 | **Publicado/Published:** 2022-03-31

© Author(s) (or their employer(s)) and *Oftalmologia* 2022. Re-use permitted under CC BY-NC. No commercial re-use.

© Autor (es) (ou seu (s) empregador (es)) e *Oftalmologia* 2022. Reutilização permitida de acordo com CC BY-NC. Nenhuma reutilização comercial.

DOI: <https://doi.org/10.48560/rspo.25958>

### ABSTRACT

**INTRODUCTION:** Sector retinitis pigmentosa (sRP) is a rare, atypical, and milder variant of rod-cone degeneration. Despite historically associated with *RHO* gene, the mutational spectrum of sRP is evolving with multiple causative genes recently implicated. This study aimed to characterize the genotypes, phenotypes, and natural history of a Portuguese cohort of sRP.

**METHODS:** Retrospective, observational study, conducted at a tertiary referral center. Patients with a clinical diagnosis of sRP and available genetic testing results were identified using a web-based registry. The clinical diagnosis was established based on ophthalmologic examination, functional testing [best corrected visual acuity (BCVA) and visual field testing] and multimodal imaging [color fundus photography (CFP), fundus autofluorescence (FAF) and optical coherence tomography (OCT)]. Genetic testing was clinically oriented in all probands, and variants were classified according to the American College of Medical Genetics and Genomics. Only likely pathogenic or pathogenic variants were considered disease-causing. Clinical progression was evaluated throughout follow-up.

**RESULTS:** Fourteen patients from twelve families were included. Disease-causing variants in RP-related genes were identified in 8 families, for a diagnostic yield of 66.7%. *EYS* was the most frequently implicated gene (4 families), followed by *RHO* (2 families), and finally *MYO7A* and *NPHP1* (1 family each). In most unsolved cases, no clinically significant variants were found. However, for one unsolved case, a *RHO*-associated variant of uncertain significance was identified. Two patients exhibited syndromic sRP. All cases were bilateral and symmetrical except for two. Inferior and/or nasal retinal involvement on FAF was noted in all cases. Visual field testing revealed superior field defects of varying extents, always in close association with observed FAF findings. Over a median follow-up of 32.5 months (range: 5-148 months), no significant differences were found on BCVA ( $p=0.056$ ). In fact, BCVA remained stable and  $\leq 0.20$  LogMAR OU in 9/14 patients. Multimodal imaging revealed no progression over the available follow-up.

**CONCLUSION:** This study highlights the genotypic heterogeneity of sRP in a Portuguese cohort. Inferior and nasal predilection was common across different genotypes, and a high pro-

portion of patients maintained good central vision. The longitudinal data provided herein will help to accurately inform patients on prognosis.

**KEYWORDS:** Disease Progression; Genetic Association Studies; Multimodal Imaging; Retinal Dystrophies; Retinitis Pigmentosa/diagnosis; Retinitis Pigmentosa/genetics.

## RESUMO

**INTRODUÇÃO:** A retinopatia pigmentar setorial (sRP) é uma forma rara, atípica e menos severa de distrofia de bastonetes-cones. Apesar de tipicamente associada ao gene *RHO*, o espectro mutacional da sRP está em evolução, com múltiplos novos genes recentemente associados. O objetivo deste estudo é caracterizar os genótipos, fenótipos e história natural da sRP numa coorte portuguesa.

**MÉTODOS:** Estudo retrospectivo, observacional. Identificámos doentes com diagnóstico clínico de sRP e com resultados genéticos disponíveis. O diagnóstico clínico foi baseado no exame oftalmológico, avaliação funcional (acuidade visual corrigida e avaliação de campos visuais) e imagiologia retiniana multimodal (retinografia, autofluorescência do fundo ocular e tomografia de coerência ótica). O estudo genético foi direcionado com base na informação clínica e as variantes genéticas encontradas foram classificadas de acordo com orientações do American College of Medical Genetics and Genomics. Variantes patogénicas ou provavelmente patogénicas foram consideradas causadoras de doença. A progressão clínica foi avaliada ao longo do *follow-up*.

**RESULTADOS:** Foram incluídos 14 doentes (12 famílias). Foram identificadas variantes genéticas causadoras de doença em 8 famílias, resultando numa taxa de diagnóstico de 66.7%. *EYS* foi o gene mais frequentemente encontrado (4 famílias), seguido de *RHO* (2 famílias) e finalmente *MYO7A* e *NPHP1* (1 família cada). Num dos casos sem confirmação genética foi identificada uma variante de significado incerto no gene *RHO*. Dois pacientes exibiam sRP síndromica. Todos os casos eram bilaterais e simétricos exceto dois. Na autofluorescência foi detetado envolvimento da retina nasal e/ou inferior em todos os doentes. Não se verificaram diferenças estatisticamente significativas ( $p=0.056$ ) na melhor acuidade visual corrigida ao longo de um *follow-up* mediano de 32.5 meses (variação: 5-148 meses). A visão manteve-se estável e  $\leq 0.20$  LogMAR OU em 9/14 doentes. Não foi detetada progressão em imagem multimodal ao longo do *follow-up* disponível.

**CONCLUSÃO:** Este estudo destaca a heterogeneidade genotípica da sRP numa coorte portuguesa. Envolvimento inferior e nasal foi comum a todos os casos e uma grande parte dos doentes manteve uma boa acuidade visual. Os dados apresentados serão úteis para aconselhar os pacientes em relação ao prognóstico desta doença.

**PALAVRAS-CHAVE:** Distrofias Retinianas; Estudos de Associação Genética; Imagem Multimodal; Progressão da Doença; Retinite Pigmentosa.

## INTRODUCTION

Retinitis pigmentosa (RP) encompasses an heterogeneous group of inherited retinal dystrophies (IRDs), primarily characterized by rod-cone degeneration.<sup>1</sup> Sector retinitis pigmentosa (sRP) is a rare, atypical, and usually milder variant of RP, which per definition involves only one or two retinal quadrants. The condition is typically bilateral and symmetrical, and predominantly affects the inferior and nasal quadrants.<sup>2,3</sup> Visual prognosis is usually better than in classic RP as clinical progression tends to be slow or nonexistent and patients often retain good visual acuity. In fact, Georgiou *et al* (2021) reported mean visual acuity

measurements as high as 0.06 LogMAR in a cohort of 20 patients with sRP over a 10 year follow-up period.<sup>4</sup> Despite historically associated with the Rhodopsin (*RHO*) gene,<sup>5</sup> the mutational spectrum of sRP is evolving with multiple other causative genes recently implicated.<sup>4,6-8</sup> These genes are associated with autosomal dominant (AD), autosomal recessive (AR) and X-linked (XL) non-syndromic sRP, but also with some forms of syndromic sRP.<sup>4,6-8</sup>

Combining state of the art genotyping with deep phenotyping allows for a better characterization of sRP. Ultimately, the generated knowledge can be used to better inform patients about the disease and to provide them with an accurate prognosis. This study aimed to characterize the

genomic landscape, clinical phenotypes, and natural history of a Portuguese cohort of sRP.

## METHODS

### STUDY DESIGN

Retrospective, observational study. Patients with a clinical diagnosis of sRP and available genetic testing results were identified using the IRD-PT registry,<sup>9</sup> a web-based national registry for IRDs in Portugal. The study was conducted at the Retinal Dystrophies Clinic and Medical Genetics Unit of Centro Hospitalar e Universitário de Coimbra (CHUC), an inherited retinal dystrophies reference center and the only Portuguese provider represented in the European Reference Network for rare eye diseases (ERN-EYE) consortium. The study was approved by the local ethics committee and followed the tenets of the Declaration of Helsinki for biomedical research. Written informed consent was obtained for every included subject.

### DIAGNOSTIC CRITERIA AND IMAGE GRADING

The clinical diagnosis of sRP was established based on a detailed ophthalmologic examination including dilated slit-lamp anterior segment and fundus biomicroscopy, functional testing [best corrected visual acuity (BCVA, ETDRS letters) and Humphrey visual field testing (Zeiss 750i, Carl Zeiss, Germany)] and multimodal imaging [color fundus photographs (CFP) taken with a Nikon Digital SLR Camera D7000 (Nikon Corporation, Japan) mounted on either a TRC-NW7SF or TRC-NW8 Mark II Retinal Camera (Topcon Corporation, Japan), ultrawidefield (UWF) fundus and fundus autofluorescence (FAF) imaging (Optos California, Optos GmbH, Germany), and spectral-domain optical coherence tomography (SD-OCT, Spectralis, Heidelberg Engineering, Heidelberg, Germany or Avanti RTVue-XR 100, Optovue Inc, Fremont, CA, USA)]. The clinical records and multimodal imaging of all identified patients were reviewed to confirm the diagnosis of sRP. Past medical history and family history were recorded from each patient file. Clinical progression was evaluated throughout follow-up, using multimodal imaging and functional testing.

In order to determine the extent of disease involvement using FAF, the retina was divided into four sectors (superior, inferior, nasal and temporal) centered at the fovea, using a vertical and a horizontal meridian, as previously described.<sup>4</sup> A sector was considered involved if >50% of its area exhibited RP related changes, namely hypo-autofluorescence compatible with patches of outer retinal atrophy and/or bone spicule hyperpigmentation. Interocular symmetry was assessed on a qualitative basis, according to multimodal imaging findings. Disease involvement was deemed asymmetrical if different retinal quadrants were affected in both eyes. All images were graded by two independent experienced medical graders (JPM and TC). Disagreement was resolved by open adjudication.

## GENETIC TESTING

Genetic testing was clinically oriented in all probands and coordinated by a medical geneticist from the Medical Genetics Unit of CHUC. Peripheral blood samples were collected from all probands and available relatives for genetic analysis. Genomic DNA was extracted using a genomic DNA extraction and purification kit based on the manufacturer's protocol. Genetic testing included next generation sequencing (NGS) panels, Sanger sequencing, multiplex-ligation dependent probe amplification (MLPA) and whole exome sequencing (WES). Genetic variants were classified according to the American College of Medical Genetics and Genomics (ACMG) standards and guidelines for the interpretation of sequence variants.<sup>10</sup> Only likely pathogenic (Class IV) or pathogenic (Class V) variants were considered disease-causing. Genetic counselling was provided by a medical geneticist to all patients.

## STATISTICAL ANALYSIS

Statistical analysis was conducted using the software IBM SPSS Statistics (Chicago, Illinois). A *p* value <0.05 was considered statistically significant. Descriptive statistics were computed for all variables. Kolmogorov-Smirnov test was used to access the normality of a distribution. Wilcoxon signed-rank test was used to compare repeated measurements (matched or paired data). ANOVA was used to test associations between continuous variables and >2 independent factors.

## RESULTS

### GENETIC DATA

Fourteen patients (12 families) with a clinical diagnosis of sRP and available genetic testing results were included in the study. Most patients (9/14 patients, 64.3%) were female. Mean age at diagnosis was  $52.5 \pm 16.5$  years old, and half of the patients were asymptomatic at this point. Nine patients (64.3%) have a family history of retinitis pigmentosa or sRP, and one (Patient 3) has consanguineous parents. Patient 7 (P7) and P8 are siblings, and P9 is their mother. The remaining patients are not related to each other. **Table 1** summarily presents the sample's genetic and demographic data.

We were able to identify disease-causing variants in syndromic or non-syndromic RP related genes for 8 of these families, resulting in a diagnostic yield of 66.7%. The most frequently implicated gene was eyes shut homologue (*EYS*, 6q12, MIM \*612424) which harbored disease-causing variants in 4 families (4 individuals), followed by rhodopsin (*RHO*, 3q22.1, MIM \*180380) in 2 families (4 individuals), and finally nephrocystin 1 (*NPHP1*, 2q13, MIM \*607100) and myosin VIIA (*MYO7A*, 11q13.5 MIM \*276903) affecting one family/individual each. The most frequently observed inheritance pattern was autosomal recessive (n=6), in association with *EYS*, *NPHP1* and *MYO7A* genes.

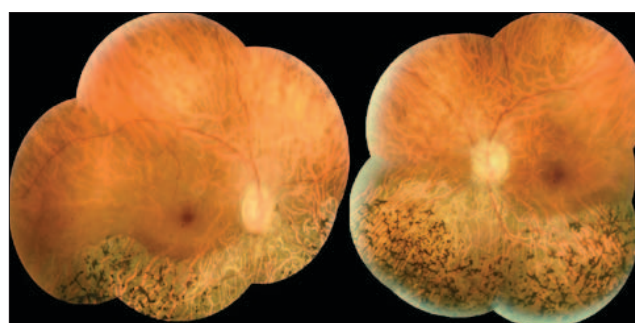
Patient	Sex	Age of Diagnosis	Family History	Genetic Test	Gene	Variant 1 (ACMG Class)	Variant 2 (ACMG Class)	Zygoty (Inheritance)
P1	F	35	Y	Sanger	<i>EYS</i>	c.2225del p.(Cys742Leufs36) (Pathogenic)	c.(2023+1_2024-1)_(2259+1_2260-1)del (Pathogenic)	C.HTZ (AR)
P2	F	56	N	NGS panel	<i>EYS</i>	c.2225del p.(Cys742Leufs*36) (Likely Pathogenic)	c.2225del p.(Cys742Leufs*36) (Likely Pathogenic)	HMZ (AR)
P3	F	59	Y	NGS panel	<i>EYS</i>	c.5928-2A>G p.? (Pathogenic)	c.5928-2A>G p.? (Pathogenic)	HMZ (AR)
P4	M	62	Y	NGS panel	<i>EYS</i>	c.9182_9185del p.(Asn3061Thrfs*3) (Likely Pathogenic)	c.(2023+1_2024-1)_(2259+1_2260-1)del (Pathogenic)	C.HTZ (AR)
P5	F	35	Y	WES	<i>NPHP1</i>	c.2065_2074del p.(Thr689Leufs*37) (Likely Pathogenic)	c.2065_2074del p.(Thr689Leufs*37) (Likely Pathogenic)	HMZ (AR)
P6	M	19	Y	NGS panel	<i>MYO7A</i>	c.1529T>C p.(Ile510Thr) (Likely Pathogenic)	c.4489G>C p.(Gly1497Arg) (Likely Pathogenic)	C.HTZ (AR)
P7	F	42	Y	Sanger	<i>RHO</i>	c.316G>A p.(Gly106Arg) (Pathogenic)		HTZ (AD)
P8	M	43	Y	Sanger	<i>RHO</i>	c.316G>A p.(Gly106Arg) (Pathogenic)		HTZ (AD)
P9	F	*	Y	NGS panel	<i>RHO</i>	c.316G>A p.(Gly106Arg) (Pathogenic)		HTZ (AD)
P10	F	69	Y	Sanger	<i>RHO</i>	c.316G>A p.(Gly106Arg) (Pathogenic)		HTZ (AD)
P11	M	80	N	WES	*	VUS		*
P12	F	70	N	Sanger	*			*
P13	M	50	N	WES	*			*
P14	F	63	N	NGS panel	*			*

P: patient; F: female; M: male; Y: yes; N: no; NGS: next generation sequencing; WES: whole exome sequencing; C.HTZ: compound heterozygous; HMZ: homozygous; HTZ: heterozygous; AR: autosomal recessive; AD: autosomal dominant; \*:unknown; VUS: variant of uncertain significance; ACMG Class: variant classification according to ACMG;

*RHO*-associated disease followed an autosomal dominant inheritance pattern. Two patients displayed a syndromic sRP phenotype: P5 is homozygous for a *NPHP1* variant and presents chronic kidney disease secondary to nephronophthisis – Senior-Loken syndrome; P6 has bilateral sensorineural hearing loss from a young age and was diagnosed with Usher syndrome type 1B in association with two *MYO7A* variants in heterozygosity. We were unable to identify disease-causing variants in 4 patients (P11-P14), which constitute the sample's unsolved cases. However, for one of them (P11), a variant of uncertain significance (VUS) was identified in *RHO* gene. Family studies could not be carried out in order to try to change the variant's classification.

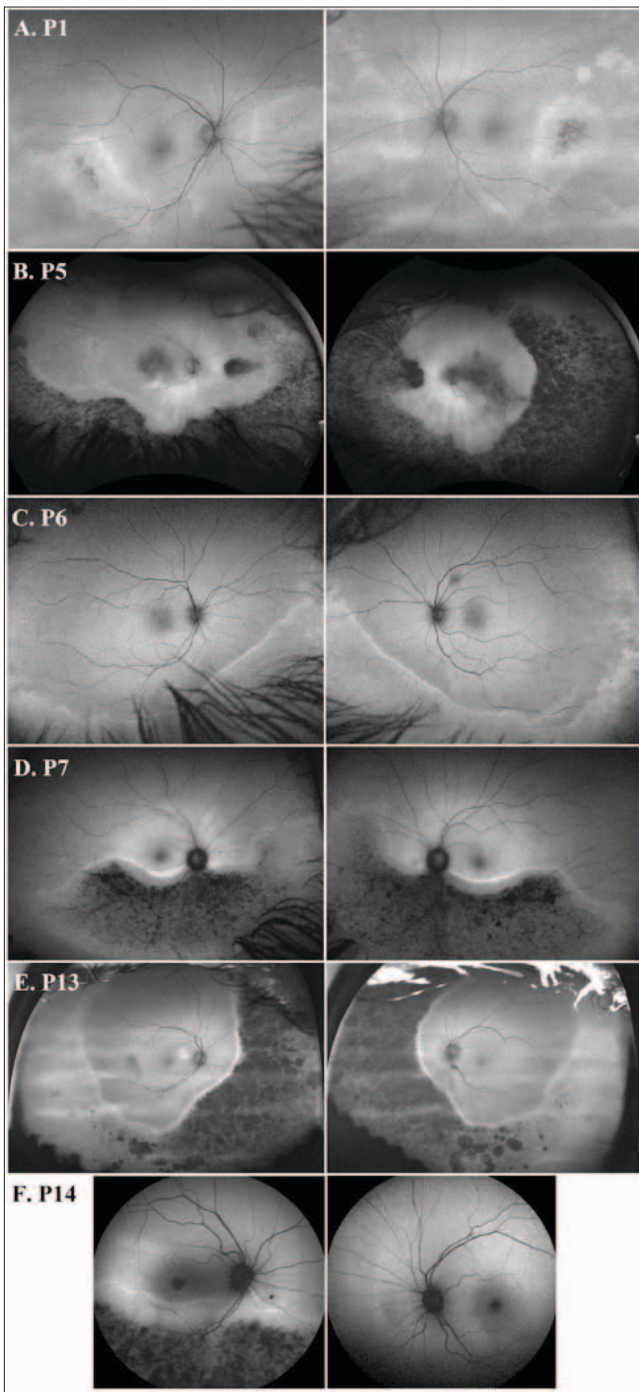
## MULTIMODAL IMAGING

Regarding multimodal imaging findings, bone spicule hyperpigmentation and attenuated blood vessels were frequently found in CFP (Fig. 1). Inferior and/or nasal involvement of the retina on FAF was found in all cases, visible as a patchy hypo-autofluorescent area, frequently associated with a crescent shaped hyper-autofluorescent band separating atrophic areas from the unaffected, iso-autofluorescent retina (Fig. 2). All cases were bilateral and symmetrical except for P5 and P14, which presented unilateral sRP. P5, who carries a homozygous *NPHP1* variant, exhibits an inferior and nasal sRP phenotype for oculus dexter (OD) and a typical RP phenotype for oculus sinister (OS), with all



**Figure 1.** Color fundus photographs of P9. Typical findings of bone spicule hyperpigmentation and attenuated blood vessels are present in the inferior and nasal quadrants.

rating atrophic areas from the unaffected, iso-autofluorescent retina (Fig. 2). All cases were bilateral and symmetrical except for P5 and P14, which presented unilateral sRP. P5, who carries a homozygous *NPHP1* variant, exhibits an inferior and nasal sRP phenotype for oculus dexter (OD) and a typical RP phenotype for oculus sinister (OS), with all

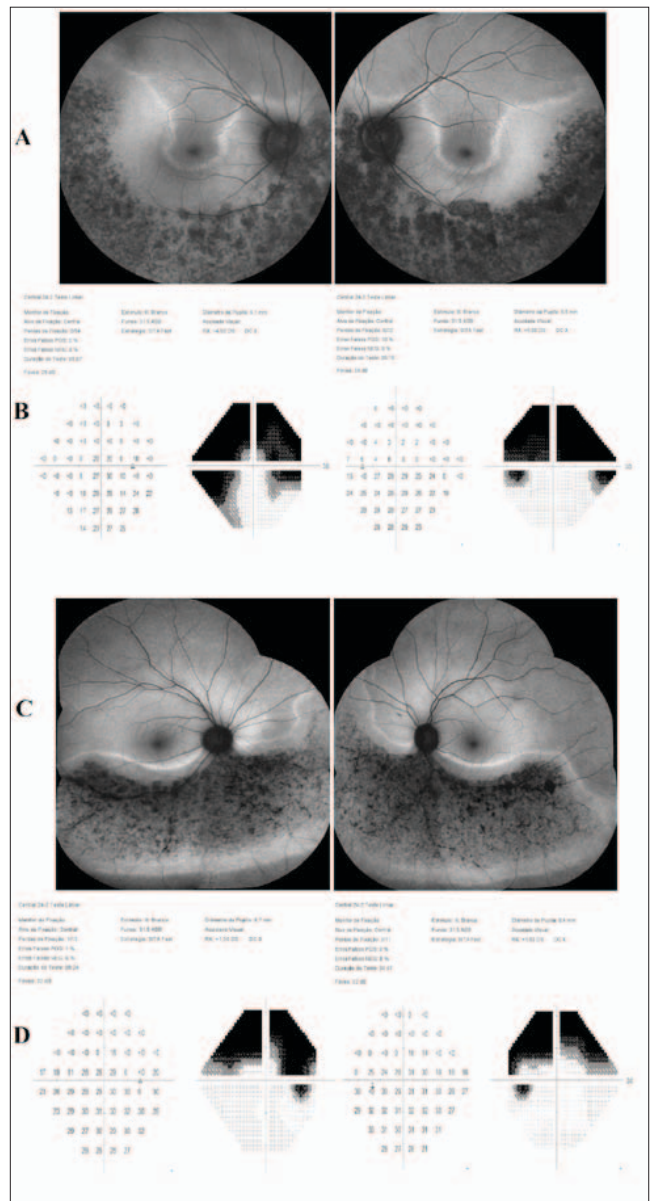


**Figure 2.** Bilateral FAF imaging of 6 patients. Retinal degeneration is seen as a patchy hypo-autofluorescent area on FAF. A hyper-autofluorescent band is frequently seen separating healthy auto-fluorescent retina from affected tissue (A, C, D, E, F). Two patients exhibit asymmetrical disease involvement (B and F). All other patients have bilateral and symmetrical FAF imaging findings.

retinal quadrants affected (Fig. 2B). P14 displays an inferior sRP phenotype for OD, and no abnormal FAF findings for OS (Fig. 2F). Disease location was most frequently inferior (n=9, 64.3%), followed by inferior and nasal (n=5, 35.7%). One patient (P10) showed disease extension to the fovea.

## FUNCTIONAL TESTING

Visual field testing mostly revealed superior visual field defects of varying extents, always in close association with the observed FAF findings (Fig. 3). BCVA measurements over time were available for all patients. In 3 patients reduced BCVA was unrelated to retinal degeneration: P4 had bilateral optic nerve atrophy secondary to anterior ischemic optic neuropathy; P11 exhibited visually significant cataract oculus uterque (OU); P14 had history of rhegmatogenous retinal detachment OD and underwent surgery. Over a median follow-up period of 32.5 months (range 5 - 148 months), BCVA remained stable and  $\leq 0.20$  LogMAR



**Figure 3.** FAF and 24-2 Humphrey visual field testing of P3 (A and B) and P7 (C and D). There are evident superior visual field defects that correlate strongly with the inferior retinal involvement seen on FAF imaging as a localized hyper-autofluorescent area.



OU in 9/14 patients (64.3%). When excluding eyes with underlying pathology unrelated to retinal degeneration (P4, P11 and P14) this number changes to 9/11 patients (81.8%). Mean BCVA (excluding P4, P11 and P14) at baseline was 0.15 LogMAR for OD and 0.15 LogMAR for OS, and final mean BCVA was 0.19 and 0.24 LogMAR for OD and OS, respectively. No statistically significant differences were observed on BCVA over the follow-up period ( $p=0.056$ ). Additionally, no statistically significant differences were found on BCVA according to inheritance pattern ( $p=0.202$ ) or gene ( $p=0.234$ ), tested for *EYS*, *RHO* and unsolved cases. Since there was only one subject with *NPHP1* and *MYO7A*-associated sRP, statistical analysis was not possible for these genes. A graphical representation of each patient's BCVA over follow-up is presented in Fig. 4.

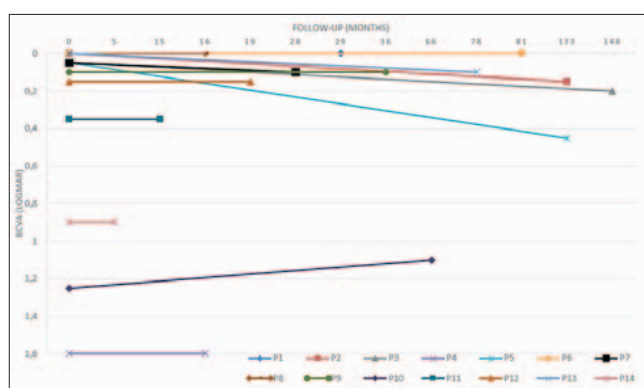


Figure 4. Graphical representation of BCVA from baseline to last available follow-up. All patients had available BCVA data and were followed for a median period of 32.5 months.

P10 exhibited foveal involvement bilaterally, with corresponding poor central visual acuity (final BCVA was 1.2 and 1.0 LogMAR for OD and OS respectively). OCT imaging revealed preservation of the normal foveal architecture and retinal inner layers OU. However, there is atrophy of the outer retinal layers and the RPE/Bruch's membrane

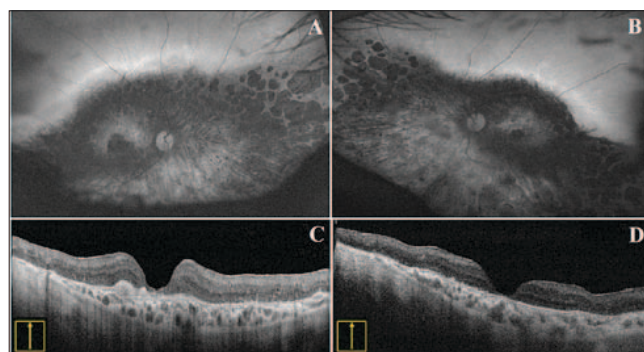


Figure 5. Bilateral FAF and SD-OCT imaging of P10. On FAF, hypo-autofluorescent patches of retinal atrophy are seen in an inferior, nasal, and macular distribution for OD (A) and OS (B). (C and D) Vertical SD-OCT scan shows atrophy of the outer retinal layers and RPE/Bruch's membrane complex OU. (D) Additionally, OD displays the presence of subretinal hyperreflective material.

complex involving the center point. Additionally, sub-retinal hyper-reflective material is observed in the right eye, compatible with subretinal fibrosis (Fig. 5).

## DISCUSSION

This study highlights the genotypic heterogeneity of sRP in a Portuguese cohort. Disease-causing variants in 4 different genes (*EYS*, *RHO*, *NPHP1* and *MYO7A*) were identified, all of which have previously been associated to sRP.<sup>4,6</sup> Contrary to other cohorts,<sup>2,4</sup> *EYS* was the most frequently encountered causative gene in our population (4 patients from 4 different families). *EYS* disease-causing variants are a common cause for autosomal-recessive RP in European populations,<sup>11,12</sup> and have also been recently linked with sRP.<sup>4,13</sup> Even though clinically significant variants in *RHO* were also present in 4 patients, 3 of these were first degree relatives (P7, P8 and P9).

Mean age at the time of diagnosis was 52.5 years old, and half the patients were asymptomatic at diagnosis, thus highlighting the milder disease course associated with the sRP phenotype. The 2 patients who exhibited syndromic sRP were diagnosed at an earlier age ( $\leq 35$  years old). However, both patients were visually asymptomatic at diagnosis and their ophthalmologic evaluation was prompted due to systemic and genetic findings and its known association with ophthalmologic involvement.

The vast majority of patients ( $n=12$ , 85.7%) exhibited bilateral and symmetrical disease involvement, a similar finding to what has been described in the literature.<sup>2,4,14</sup> Also in line with previous reports is the inferior and/or nasal retinal involvement, which was observed in all patients and across different genotypes. This pattern of involvement seen on FAF correlated well with the visual field defects detected on Humphrey visual field testing.

It has been previously reported that  $>80\%$  of sRP patients maintain a BCVA  $<0.3$  LogMAR.<sup>4</sup> This was also true for the present cohort, when excluding patients who exhibited reduced BCVA unrelated to retinal degeneration ( $n=3$ ). In fact, 9/11 patients (81.8%) were able to retain a BCVA  $<0.3$  LogMAR over a median follow-up period of 32.5 months. No statistically significant differences were observed on BCVA over the course of follow-up ( $p=0.056$ ), which supports the concept that sRP is a slowly progressing or stationary disease.

One patient (P10) exhibited foveal involvement, as noticed on OCT imaging, with corresponding poor BCVA. Although a less common finding, foveal involvement has been previously reported in sRP and was also linked with poorer visual acuity.<sup>2,4</sup> Curiously, this patient carries a *RHO* variant, which has been associated with a foveal sparing phenotype.<sup>2,4</sup> Also intriguing was the observed phenotypic variability for this specific *RHO* variant (c.316G>A p.(Gly106Arg)), which for P7, P8 and P9 resulted in inferior retinal involvement, while for P10 resulted in inferior, nasal and foveal involvement (Fig. 5). Phenotypic heterogeneity has been previously described for RP variants, and it has been hypothesized that external factors may influence clinical phenotypes.<sup>15</sup>

We were unable to find disease-causing variants for 4 patients in our cohort. Genetic testing selection and/or limitations or the presence of phenocopies may explain the unsolved cases. Given the distinctive phenotype and known association between the sRP phenotype and *RHO*, P12 underwent Sanger sequencing of the *RHO* gene in 2018 and no clinically significant variants were found. Recent advances in the characterization of sRP made us change our genetic testing approach for sRP cases. Unfortunately, the patient was lost to follow up and we were not able to perform additional testing. Current limitations of genetic testing may be responsible for other unsolved cases. Birtel *et al* (2019) argued that non-coding region contained disease-causing variants may remain undetected by genetic testing, and that disease-causing variants may exist in genes that currently have not been associated with RP.<sup>16</sup> Another reason for the unsolved cases be an incorrect clinical diagnosis. Trauma, inflammation and infection, among others, may simulate a RP phenotype, thus producing a phenocopy.<sup>17</sup>

P14 presented with unilateral sRP OD and no abnormal findings on OS. FAF revealed inferior patchy hypo-autofluorescence and a hyper-autofluorescent band separating this area from the presumably healthy, iso-autofluorescent retina (Fig. 2F). On the one hand, unilateral RP is a rare finding, but such cases have been previously reported in the literature, and some have been molecularly confirmed.<sup>18,19</sup> Regardless, it is also possible that this case is a phenocopy and the previous history of retinal detachment may explain the observed phenotype.

This study is not exempt of limitations, beginning with its retrospective nature. Furthermore, the median follow-up period is modest (32.5 months), which may be too short of a period to expect clinical progression for a slowly progressing disease. Finally, the follow-up period varied considerably between patients (minimum 5 months; maximum 148 months). Nevertheless, we were able to shed light on the genomic landscape and natural history of sRP, contributing to the ever-growing understanding of this atypical and rare phenotype.

In conclusion, we have shown that despite the diverse genomic background, an overall good prognosis is to be expected over the course of the disease. Our findings are particularly important to accurately inform patients on prognosis, especially given the current absence of treatment approaches which could alter disease course/progression.

## PRESENTATIONS AND AWARDS

This work was presented as a free paper at the EURETINA 2021 VIRTUAL congress.

## CONTRIBUTORSHIP STATEMENT / DECLARAÇÃO DE CONTRIBUIÇÃO:

TC: Desenho do estudo e elaboração do artigo. Colheita, análise estatística e interpretação dos dados. Redação do

manuscrito, revisão de versões e aprovação da versão final.

JPM: Desenho do estudo e elaboração do artigo. Colheita, análise estatística e interpretação dos dados. Redação do manuscrito, revisão crítica e aprovação da versão final.

SG e EN: Elaboração do artigo. Colheita e interpretação dos dados. Revisão de versões do manuscrito e aprovação da versão final.

ALC: Colheita e interpretação de dados. Revisão de versões do manuscrito e aprovação da versão final.

JR, RS e JM: Revisão crítica do manuscrito e aprovação da versão final.

## RESPONSABILIDADES ÉTICAS

**Conflitos de Interesse:** Os autores declaram a inexistência de conflitos de interesse na realização do presente trabalho.

**Fontes de Financiamento:** Não existiram fontes externas de financiamento para a realização deste artigo.

**Confidencialidade dos Dados:** Os autores declaram ter seguido os protocolos da sua instituição acerca da publicação dos dados de doentes.

**Proteção de Pessoas e Animais:** Os autores declaram que os procedimentos seguidos estavam de acordo com os regulamentos estabelecidos pelos responsáveis da Comissão de Investigação Clínica e Ética e de acordo com a Declaração de Helsínquia revista em 2013 e da Associação Médica Mundial.

**Proveniência e Revisão por Pares:** Não comissionado; revisão externa por pares.

## ETHICAL DISCLOSURES

**Conflicts of Interest:** The authors have no conflicts of interest to declare.

**Financing Support:** This work has not received any contribution, grant or scholarship

**Confidentiality of Data:** The authors declare that they have followed the protocols of their work center on the publication of data from patients.

**Protection of Human and Animal Subjects:** The authors declare that the procedures followed were in accordance with the regulations of the relevant clinical research ethics committee and with those of the Code of Ethics of the World Medical Association (Declaration of Helsinki as revised in 2013).

**Provenance and Peer Review:** Not commissioned; externally peer reviewed.

## REFERENCES

1. Yang YJ, Peng J, Ying D, Peng QH. A Brief Review on the Pathological Role of Decreased Blood Flow Affected in Retinitis Pigmentosa. *J Ophthalmol.* 2018;3249064. doi: 10.1155/2018/3249064.
2. Coussa RG, Basali D, Maeda A, DeBenedictis M, Traboulsi EI.

- Sector retinitis pigmentosa: Report of ten cases and a review of the literature. *Mol Vis.* 2019;25:869–89.
3. Scholl HPN, Kremers J. L- and M-cone driven large-field and multifocal electroretinograms in sector retinitis pigmentosa. *Doc Ophthalmol.* 2003;106:171–81. doi: 10.1023/a:1022505204826.
  4. Georgiou M, Grewal PS, Narayan A, Alser M, Ali N, Fujinami K, et al. Sector Retinitis Pigmentosa: Extending the Molecular Genetics Basis and Elucidating the Natural History. *Am J Ophthalmol.* 2021;221:299–310. doi: 10.1016/j.ajo.2020.08.004.
  5. Napier ML, Durga D, Wolsley CJ, Chamney S, Alexander S, Brennan R, et al. Mutational Analysis of the Rhodopsin Gene in Sector Retinitis Pigmentosa. *Ophthalmic Genet.* 2015;36:239–43. doi: 10.3109/13816810.2014.958862.
  6. Yahalom C, Volovelsky O, Macarov M, Altalbishi A, Alswaiti Y, Schneider N, et al. Senior-Løken Syndrome : A Case Series and Review of the Renoretinal Phenotype and Advances of Molecular Diagnosis. *Retina.* 2021;41:2179–87. doi: 10.1097/iae.0000000000003138.
  7. Sato M, Oshika T, Kaji Y, Nose H. A novel homozygous Gly107Arg mutation in the RDH5 gene in a Japanese patient with fundus albipunctatus with sectorial retinitis pigmentosa. *Ophthalmic Res.* 2004;36:43–50. doi: 10.1159/000076109.
  8. Pappalardo J, Heath Jeffery RC, Thompson JA, Charnig J, Chelva ES, Constable IJ, et al. Progressive sector retinitis pigmentosa due to c.440G>T mutation in SAG in an Australian family. *Ophthalmic Genet.* 2021;42:62–70. doi: 10.1080/13816810.2020.1832533.
  9. Marques JP, Carvalho AL, Henriques J, Murta JN, Saraiva J, Silva R. Design, development and deployment of a web-based interoperable registry for inherited retinal dystrophies in Portugal: the IRD-PT. *Orphanet J Rare Dis.* 2020;15:304. doi: 10.1186/s13023-020-01591-6.
  10. Richards S, Aziz N, Bale S, Bick D, Das S, Gastier-Foster J, et al. Standards and guidelines for the interpretation of sequence variants: a joint consensus recommendation of the American College of Medical Genetics and Genomics and the Association for Molecular Pathology. *Genet Med.* 2015;17:405–24. doi: 10.1038/gim.2015.30.
  11. Barragán I, Borrego S, Pieras JI, González-del Pozo M, Santoyo J, Ayuso C, et al. Mutation spectrum of EYS in Spanish patients with autosomal recessive retinitis pigmentosa. *Hum Mutat.* 2010;31:E1772–800. doi: 10.1002/humu.21334.
  12. Audo I, Sahel J-A, Mohand-Saïd S, Lancelot M-E, Antonio A, Moskova-Doumanova V, et al. EYS is a major gene for rod-cone dystrophies in France. *Hum Mutat.* 2010;31:E1406–35. doi: 10.1002/humu.21249.
  13. Marques JP, Porto FB, Carvalho AL, Neves E, Chen R, Sampaio SA, et al. EYS-Associated Sector Retinitis Pigmentosa. *Graefe's Arch Clin Exp Ophthalmol.* 2021 (in press). doi: 10.1007/s00417-021-05411-w.
  14. Xiao T, Xu K, Zhang X, Xie Y, Li Y. Sector Retinitis Pigmentosa caused by mutations of the RHO gene. *Eye.* 2019;33:592–9. doi: 10.1038/s41433-018-0264-3.
  15. Ramon E, Cordero A, Aguilà M, Srinivasan S, Dong X, Moore AT, et al. Differential light-induced responses in sectorial inherited retinal degeneration. *J Biol Chem.* 2014;289:35918–28. doi: 10.1074/jbc.M114.609958.
  16. Birtel J, Gliem M, Oishi A, Müller PL, Herrmann P, Holz FG, et al. Genetic testing in patients with retinitis pigmentosa: Features of unsolved cases. *Clin Experiment Ophthalmol.* 2019;47:779–86. doi: 10.1111/ceo.13516.
  17. Marsiglia M, Duncker T, Peiretti E, Brodie SE, Tsang SH. Unilateral retinitis pigmentosa: a proposal of genetic pathogenic mechanisms. *Eur J Ophthalmol.* 2012;22:654–60. doi: 10.5301/ejo.5000086.
  18. Mukhopadhyay R, Holder GE, Moore AT, Webster AR. Unilateral Retinitis Pigmentosa Occurring in an Individual With a Germline Mutation in the RP1 Gene. *Arch Ophthalmol.* 2011;129:954–6. doi: 10.1001/archophthalmol.2011.171.
  19. Sim PY, Jeganathan VSE, Wright AF, Cackett P. Unilateral retinitis pigmentosa occurring in an individual with a mutation in the CLRN1 gene. *BMJ Case Rep.* 2018;2018:bcr2017222045. doi: 10.1136/bcr-2017-222045.



**Corresponding Author/  
Autor Correspondente:**

**Telmo Cortinhal**

Centro de Responsabilidade Integrado  
em Oftalmologia, Centro Hospitalar e  
Universitário de Coimbra,  
Praceta Professor Mota Pinto  
3000-075 Coimbra, Portugal  
telmojc@gmail.com



ORCID: 0000-0002-9016-9031

