FACULDADE DE MEDICINA DA UNIVERSIDADE DE COIMBRA

MESTRADO INTEGRADO EM MEDICINA – TRABALHO FINAL

JOÃO ARTUR GUIOMAR DE ALMEIDA FERREIRA

Reticular Pseudodrusen and progression to late-stage Age-Related Macular Degeneration: a 5-year survival analysis

ARTIGO CIENTÍFICO

ÁREA CIENTÍFICA DE OFTALMOLOGIA

Trabalho realizado sob a orientação de:

DR. JOSÉ COSTA

PROFESSOR DOUTOR RUFINO SILVA

ABRIL 2018

Reticular Pseudodrusen and progression to late-stage Age-Related Macular Degeneration: a 5-year survival analysis

João Artur Guiomar de Almeida Ferreira[1]

Orientador: Doutor José Filipe Dias da Costa[1,2]

Co-orientador: Professor Doutor Rufino Martins da Silva[1,2,3]

[1]Faculdade de Medicina, Universidade de Coimbra, Portugal; joaoartur.f@gmail.com

[2]Centro de Responsabilidade Integrado de Oftalmologia – Centro Hospital e Universitário de Coimbra, Coimbra, Portugal

[3]Association for Innovation and Biomedical Research on Light and Image (AIBILI). Coimbra. Portugal

Table of contents

Resumo 3

Abstract 5

Keywords 6

List of abbreviations 7

Introduction 8

Materials and methods 10

1. Study design 10
2. Population 10
3. Study procedures 11
4. Image acquisition and grading 11
5. Statistical analysis 13

Results 14

1. Survival Analysis 15

Discussion 20

Conclusion 22

Agradecimentos 23

Referências 24

Resumo

Introdução

Drusen e pseudodrusen reticulares (RPD) são fatores de risco bem conhecidos de progressão para os estadios tardios da degenerescência macular relacionada com a idade (DMI). Contudo, o impacto preciso dos RPD e de características específicas dos drusen na taxa de conversão para esses estadios continua ainda por caracterizar. O nosso objetivo foi determinar, numa coorte a 5 anos, a influência dos RPD, tamanho, área e número de drusen nas taxas de conversão para as fases tardias da DMI no olho adelfo de pacientes com neovascularização coroideia (NVC).

Métodos

Estudo retrospetivo de seguimento incluindo os olhos adelfos de DMI com NVC. No início, todos os olhos foram avaliados com base num extenso protocolo imagiológico, que permitiu uma identificação dos RPD e caracterização do número, área e dimensão dos drusen. Todos os olhos incluídos foram seguidos até à conversão ou pelo menos até se atingir os 5 anos de seguimento. Análises de sobrevivência univariadas e multivariadas foram usadas para analisar os fatores preditores de conversão.

Resultados

Estudámos 63 olhos de 63 doentes (26 do sexo feminino) com uma idade media de 76.2 ± 6.6 anos e um seguimento médio de 45.8±26.8 meses. A prevalência de base de RPD foi de 55.6% (35). Não foi encontrada uma diferença estatisticamente significativa para idade (p=0.70) ou sexo (p=0.82) entre os grupos de doentes com e sem RPD. Quarenta e um olhos (65.1%) converteram para as fases tardias de DMI durante o seguimento: 7 (11.1%) para atrofia geográfica (AG) e 34 (54.0%) para NVC, após um tempo médio de 31.5±20.9 meses. O tempo

médio até à conversão foi de 39.2±12.7 meses: 29.8±6.1 meses nos doentes com RPD e 79.2 meses nos doentes sem RPD. A presença de RPD ($p<0.01$) e drusen grandes ($p=0.02$) foram fatores estatisticamente significativos para conversão. A taxa de risco (TR) para conversão em pacientes com RPD foi de 2.64 (95% CI 1.35-5.16, $p<0.01$), 0.36 para área de drusen >700 µm (95% CI 0.17-0.79, $p=0.01$) e com drusen grandes de 4.96 (95% CI 1.96-12.53, $p<0.01$).

Discussão e Conclusão

A conversão para os estadios tardios da DMI nos olhos adelfos de doentes com NVC ocorreu 2.64 vezes mais rapidamente na presença de RPD e 4.96 vezes quando drusen grandes estavam presentes. Uma área total de drusen aumentada esteve associada a um menor risco de conversão. Dada a sua influência na velocidade de conversão, é recomendado um seguimento metódico dos doentes que apresentem estas lesões, recorrendo às últimas técnicas de imagem multimodal disponíveis, de forma a possibilitar um diagnóstico e tratamento atempados.

Palavras chave

Degenerescência macular relacionada com a idade; Neovascularização coroideia; Drusen; Pseudodrusen reticular.

Abstract

Introduction

Drusen and reticular pseudodrusen (RPD) are well-known risk factors for progression to the late stages of age-related macular degeneration (AMD). However, the precise impact of RPD and specific drusen characteristics in the rate of conversion to those stages is not completely characterized. Our purpose was to determine, in a 5-year cohort, the influence of RPD, drusen size, area and number on the progression rates to late-stage AMD in the fellow eye of patients with unilateral choroidal neovascularization (CNV).

Methods

Retrospective follow-up study including fellow eyes of AMD with CNV. At baseline all eyes were evaluated with a comprehensive imaging protocol, which allowed for RPD identification and characterization of drusen number, area and size. All eyes were followed up until conversion or until at least 5 years of follow up were attained. Univariate and multivariate survival analysis was used to assess predictors of conversion.

Results

We studied 63 eyes of 63 patients (26 female) with a mean age of 76.2±6.6 years and a mean follow up of 45.8±26.8 months. Baseline prevalence of RPD was 55.6% (35 eyes). No statistically significant difference was found for age ($p=0.70$) or sex ($p=0.82$) between patients with and without RPD. Forty-one eyes (65.1%) converted to late-stage AMD during follow-up: 7 (11.1%) to geographic atrophy (GA) and 34 (54.0%) to CNV, after an average time of 31.5±20.9 months. The mean time until conversion was 39.2±12.7 months: 29.8±6.1 months for patients with RPD and 79.2 months for patients without RPD. RPD ($p<0.01$) and large drusen ($p<0.02$) were statistically significant for conversion. Hazard ratio (HR) for conversion

in patients with RPD was 2.64 (95% CI 1.35-5.16, p<0.01), with drusen area >700 µm was 0.36 (95% CI 0.17-0.79, p=0.01) and 4.96 (95% CI 1.96-12.53, p< 0.01) for large drusen.

Discussion & Conclusion

Conversion to late-stage AMD in fellow eyes of patients with CNV occurs 2.64 times faster when RPD are present and 4.96 times faster when large drusen are detected. Increased total drusen area was associated with a smaller risk of conversion. Given their influence in the speed of conversion, a strict follow-up of these patients with the latest available multi-modal imaging techniques available is recommended.

Keywords

Age-related macular degeneration; Choroidal neovascularization; Drusen; Reticular pseudodrusen.

List of abbreviations

AMD – Age-related macular degeneration

BCVA – Best corrected visual acuity

CFP – Color fundus photography

CNV – Choroidal neovascularization

Cox PH – Cox proportional hazard

FA – Fluorescein angiography

FAF – Fundus autofluorescence

GA – Geographic atrophy

HR – Hazard ratio

ICG – Indocyanine-green angiography

IR – Infra-red

NA – Non-aplicable

OCT – Optical coherence tomography

P – Probability value

RF – Red-free

RPD – Reticular pseudodrusen

RPE – Retinal pigment epithelium

SD – Standard deviation

SD-OCT – Spectral domain optical coherence tomography

Introduction

Age-related Macular Degeneration (AMD) is a multi-stage progressive chronic disease which affects the central part of the retina (1) in people aged 55 years and above (2).

AMD is estimated to affect between 30 and 50 million people worldwide (3). By 2020, that number will increase to 196 million and by 2040 will reach 288 million (4). It is regarded as the main cause of visual impairment among old people of European parentage (3) and the fourth most common cause of blindness worldwide (4).

In its early stages, deep structural changes take place: abnormalities in the retinal pigment epithelium (RPE) and formation of subretinial deposits such as drusen (5). Despite that, early-stage AMD is largely asymptomatic (6).

With the increase in number and size of drusen, AMD progresses to its intermediate and advanced stages, where two forms are described: “nonexudative” / “dry” / “geographic atrophy” (GA) AMD and “exudative”/ “wet” / “neovascular” AMD (5,6).

Although drusen have long been considered the hallmark of this disease, recently reticular pseudodrusen have been recognized as an additional clinical phenotype of AMD (1). Starting with spectral domain optical coherence tomography (SD-OCT) (7) and followed by infra-red (IR) reflectance scans, fundus autofluorescence (FAF) and red-free imaging (RF), the advent of new imaging techniques made further characterization of RPD possible (1).

First described in 1990 by Mimmoun and Soubranne while analyzing colour fundus photographs (1), reticular pseudodrusen (RPD), also known as *reticular drusen* and *subretinal drusenoid deposits* (8), are a pale yellowish interlacing network of individual deposits ranging from 25 to 1000μm that resemble soft confluent drusen (9) arranged in an ill-defined network of broad interlacing ribbons (8). Pseudodrusen present with distinct characteristics on

multimodal images (1) and are capable of coexisting with both GA and neovascular forms of AMD (10).

RPD are now recognized as an independent factor responsible for progression to late stages of AMD.(1,6,10) Eyes with RPD have a 4-8-fold greater risk of 5-year of progression to the late stages of AMD than eyes with drusen alone (11).

We are just starting to understand the impact of these lesions on the progression of AMD patients. Our study aims to strengthen the knowledge concerning not only RPD and progression to late-stage AMD but also the rate at which the conversion occurs.

The purpose of our study is to assess the influence of epidemiologic factors, presence of pseudodrusen, drusen size and area in the rate of progression to advanced AMD based on a 5-year retrospective cohort.

Materials and methods

1. Study design

This is a multicenter, retrospective, observational, longitudinal 5-year cohort of 63 patients (age range, 61-93 years) from three locations: Saco Hospital, University of Milan (Milan, Italy); Association for Innovation and Biomedical Research on Light and Image (AIBILI, Coimbra, Portugal) in collaboration with Department of Ophthalmology, Centro Hospitalar e Universitário de Coimbra, (Coimbra, Portugal). These patients were evaluated as part of two previous multicenter studies – Early Markers study (NCT00902785) and CNV Markers study (NCT00801541) – and a secondary analysis of their clinical databases was performed. The methodology was previously described (1) and is briefly summarized below.

2. Population

Patients attending the centers with a diagnosis of CNV in one eye and no signs of late-AMD in the fellow eye were recruited.

Eligibility included the following criteria: adequate pupillary dilation and sufficiently clear ocular media to allow good-quality fundus imaging of the study eye; study eye with no GA or CNV; best corrected visual acuity (BCVA) better than 20/40 (only on "early markers" study); macular scar or CNV due to AMD in the non-study eye.

Exclusion criteria included any of the following: any treatment in the 60 days prior to enrolment with an ocular or systemic investigational agent, reports of other ocular disease (which included a refraction higher than -8D diopter power) and any medical condition that would interfere with the patient's ability to complete the trial.

Conversion to CNV was detected by a complete ophthalmic evaluation and fluorescein angiography (FA).

3. *Study procedures*

Study visits were scheduled in 6 month-intervals during the first 2 years. After that, the interval between appointments was stretched to 12 months. If any symptoms were noted, extraordinary visits were arranged. Patients with a minimum follow-up of 5 years were selected.

4. *Image acquisition and grading*

The modalities chosen were optical coherence tomography (OCT), IR, FAF, RF and color fundus photography (CFP). Fluorescein angiography and indocyanine-green angiography (ICG) were performed by all patients for the detection of exudative AMD.

OCT and IR images were obtained using a Spectralis HRA + OCT (Heidelberg Engineering, Heidelberg Germany) device.

Color fundus photography digital images were obtained by using either a Topcon 50x fundus camera (Topcon, Ltd., Tokyo, Japan) or a Nikon high resolution camera (Nikon, Tokyo, Japan) in conjunction with a Zeiss FF450 fundus camera (Zeiss, Oberkochen, Germany) to achieve a 30º field of view.

Fundus autofluorescence was performed using the HRA II (Heidelberg Retina Angiograph; Heidelberg Engineering, Heidelberg, Germany) following a standard protocol. For the FAF film, multiple images with the 30º field of view centered and focused on the macula were captured, aligned and averaged.

Fluorescein angiography and ICG images were simultaneously acquired by the HRA II with the same 30º field of view centered on the macula.

RPD recognition was based on previously reported features (1). In every patient, the study eye and central macular field were analyzed.

RPD were defined on OCT as an accumulation of hyper-reflective material in the outer retinal layer anterior to the RPE; in RF as a network 125-250µm in diameter; on IR as organized hyporeflective lesions against a hyperreflective background; in CFP as an interlacing ribbon-like network of confluent drusen with individual lesions >125µm and in reticular autofluorescence as a hypo-fluorescent lesions against a background of elevated fluorescence. RPD were considered when visible in at least one image mode.

Grading was performed by two independent, trained and certified graders. When in doubt, images were re-graded in a side-by-side manner. If discrepancies remained, the images were adjudicated and verified by a senior specialist with grading experience.

Grading was semi-automatic software-assisted by Retmaker AMD (12,13) which not only computed the size, number and location of the AMD lesions (RPD and drusen) but also allowed their quantification as continuous variables, reflecting the real (absolute) area and number of drusen. For this software, The International Classification System was assumed and five circles (63, 125, 175, 250 and 500 µm) were available for grading.

Every image was manually calibrated by the user prior to analyses. An area of 6000 µm in diameter was delimitated around the fovea and all RPD and AMD signs were recorded. RPD located outside the area were manually graded and included as well.

Geographic atrophy was defined as a round or oval area >175 µm of hypopigmentation or apparent absence of retinal pigment epithelium. Conversion to choroidal neovascular neovascularization (CNV) was considered when a well-demarcated area of hyperfluorescence was identified in the early phases of the angiography. Drusen were labeled intermediate when their diameter was between 63 and 125 µm and large when it surpassed 125 µm.

5. *Statistical analysis*

Statistical analysis was performed using STATA 15 (StataCorp, LLC, Texas, USA). An alpha of 0.05 was used as the cut-off for the significance. To analyze independent variables, *two-sample t-tests* and *chi-squared test* were used. Survival analyzes was done using Cox proportional hazards (PH) test. To evaluate the fitness of the model, we used Cox-Snell residuals and compared them with the Nelson Alan cumulative hazard function.

Results

A total of 63 participants (26 female) with unilateral CNV and no signs of late-AMD were included. All patients were Caucasian and presented with a mean age of 76.2±6.6 years (61-93). Mean follow-up was 45.8±26.4 (4-93) months. The main characteristics (number, age, sex and study eye) are summarized in Table 1 and drusen characterization in Table 2.

Table 1 – Characteristics of patients with and without RPD

	Total (n=63)	No RPD (n=28)	RPD (n=35)	Significance (p)
Age–mean (SD)	76.2 (±6.6)	75.8 (±7.1)	76.5 (±6.3)	0.70
Female sex (%)	37 (58.7)	16 (25.4)	21 (33.3)	0.82
Right eye (%)	28 (44.4)	15 (23.8)	13(20.6)	0.19

Abbreviations: SD, Standard deviation

No statistically significant differences were noted in age, sex or eye distribution, as well as in the number, area or size of the drusen in patients with and without RPD (p>0.05).

Table 2 – Drusen characterization by presence of RPD

	Total	No RPD	RPD	Significance (p)
Number (SD)	120.5 (±109.3)	101.6 (±96.2)	135.6 (±117.9)	0.22
Area (SD)	1473.6 (±2171.2)	1296.4 (±180.0)	1615.4 (±2390.2)	0.57
Intermediate (%)	57 (90.5)	25 (39.7)	32 (50.8)	0.77
Large (%)	43 (68.2)	18 (28.6)	25 (39.7)	0.54

Abbreviations: SD, Standard deviation

Of the total 63 participants, 41 (65.1%) converted to late-stage AMD: 7 (11.1%) to GA and 34 (54.0%) to CNV, after a mean-time of 31.5±20.9 (4-89) months. Table 3 displays baseline drusen characterization over conversion status.

Table 3 – Drusen characterization by conversion

	Total	No Conversion	Conversion	Significance (p)
Age – mean (SD)	76.2 (±6.6)	74.6 (±7.1)	77.0 (±6.3)	0.17
Female sex (%)	37 (58.7)	14 (22.2)	23 (36.5)	0.56
Right eye (%)	38 (44.4)	8 (12.7)	20 (31.7)	0.34
RPD	35 (55.6)	7 (11.1)	28 (44.4)	<0.01
Drusen (%)	63 (100)	22 (24.9)	41 (65.1)	NA
Drusen number (SD)	120.5 (±109.3)	117.9 (±97.1)	121.9 (±116.4)	0.89
Drusen area (SD)	1473.6 (±2171.2)	1534.7 (±2388.0)	1440.8 (±2076.0)	0.87
Intermediate drusen (%)	57 (90.5)	20 (31.7)	37 (58.7)	0.93
Large drusen (%)	43 (68.2)	11 (17.5)	32 (50.8)	0.02

Abbreviations: SD, Standard deviation; NA, non-applicable

While mean age of patients who converted to late-stage AMD was higher than those who did not convert, statistical significance was not found (p=0.17). Patients with large drusen and RPD were however statistically more susceptible to convert to late-stage AMD than patients without those findings (p=0.02 and p<0.01, respectively).

1. Survival Analysis

We started by running a log-rank test for equality of survivor functions between patients who developed RPD and patients who did not. The log-rank test confirmed a statistically significant difference between the rates of conversion with and without RPD, this being higher in the RPD group (p<0.01).

Our observation was right censored since not every patient ended up converting to late-stage AMD, as expected (with a minimum of 5 years of follow-up). We applied the Kaplan-Meier method to quantify the survival experience of the whole group (Figure 1) and of those who did and did not had RPD separately (Figure 2).

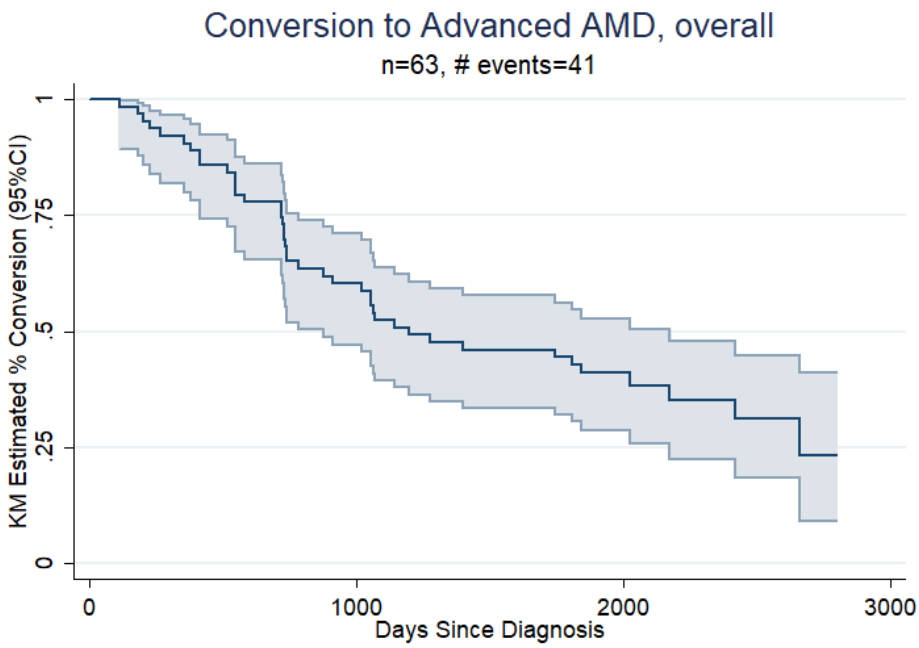

Figure 1 – Kaplan-Meier curve for overall survival for all patients

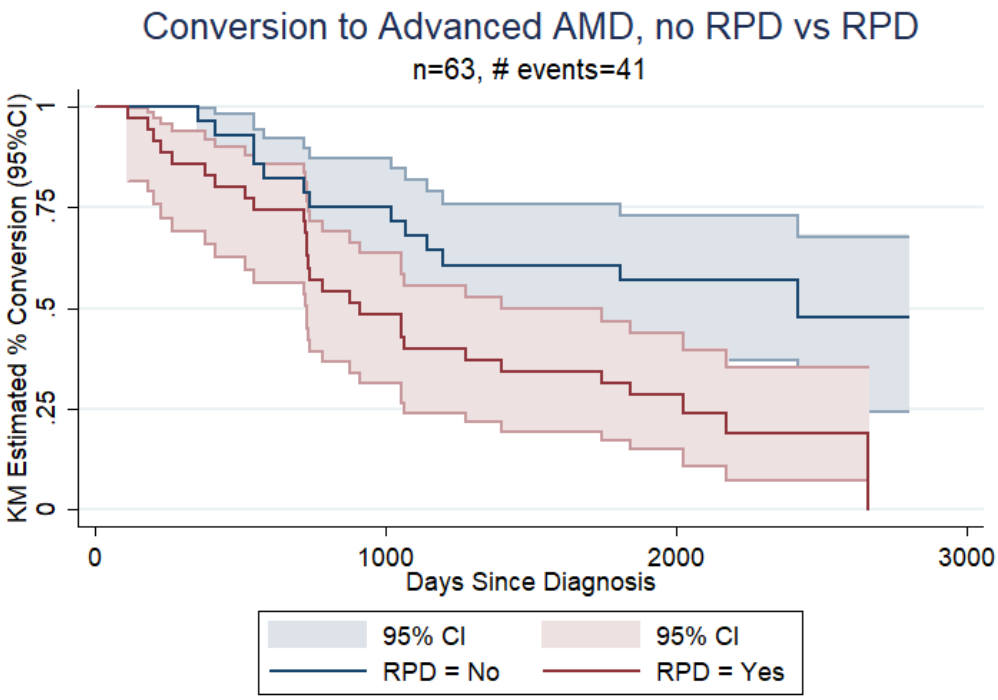

Figure 2 – Kaplan-Meier curves for overall survival for two groups of patients: with and without RPD

Median survival time for the whole population was 39.2±12.7 months. Patients with RPD had a median survival time 49.4 months shorter than those without RPD (29.8±6.1 and 79.2 months, respectively).

To determine the variables to be included in the final model, the univariate Cox proportional hazard regression analysis was applied first to identify the impact of each individual study variable on time to conversion. Table (4) presents the univariate Cox PH analysis.

Table 4 – Univariate Cox PH analysis

	Hazard Ratio (HR)	**95% confidence interval (CI) for hazard ratio**		**Significance (p)**
		Lower	Upper	
Age	1.04	0.99	1.09	0.13
Female	0.98	0.53	1.82	0.95
RPD	2.40	1.24	4.66	<0.01
Drusen:				
Number	1.00	1.00	1.00	0.99
Area > 700 µm	1.11	0.60	2.06	0.74
Intermediate	1.14	0.40	3.21	0.80
Large	2.35	1.12	4.96	0.02

In this univariate analysis, presence of RPD and large drusen were significant factors for conversion over time (RPD HR 2.40 95% CI 1.24-4.66, p<0.01; Large Drusen HR 2.35 95% CI 1.12-4.96).

We then built a multivariate model for independent predictors of conversion to advanced AMD using a proportional hazard multivariate regression analysis (Table 5).

Table 5 – Multivariate cox regression

	Hazard Ratio	95% confidence interval for hazard ratio		Significance (p)
		Lower	Upper	
RPD	2.64	1.35	5.16	<0.01
Drusen:				
Area > 700 µm	0.36	0.17	0.79	0.01
Large	4.96	1.96	12.53	<0.01

The test concluded that the presence of RPD and the number of large drusen increased the risk of conversion to late-stage AMD ($p<0.01$). Patients with RPD were 2.64 times more prone to convert to late-AMD than patients without (95% CI 1.35-5.16, $p<0.01$). The risk was 4.96 times higher when large drusen were present (95% CI 1.96-12.53, $p<0.01$). Surprisingly, drusen area over 700 µm predicted a smaller rate of conversion, when adjusting for the presence of RPD and large drusen (HR 0.36, 95% CI 0.17-0.79, $p=0.01$).

To confirm the validity of our prediction model we ran standard regression diagnostic procedures. By definition, the Cox model is constrained to follow the assumption that the hazard ratio is constant over time. In order to test this assumption and confirm the results, we ran a test of proportional hazards (Table 6).

Table 6 – Test of proportional-hazards assumption

	rho	Chi2	p
RPD	0.09	0.31	0.58
Drusen:			
Area > 700 µm	0.01	0.01	0.92
Large	-0.07	0.22	0.64
Global test			0.89

The proportional hazards were not violated by the RPD (p=0.58), area >700µm (p=0.92) and number of large drusen (p=0.64).

The goodness of fit test for the inclusion of design variables based on 2 quantiles of risk showed that there was no statistically significant evidence of a poor fit (p=0.89, p>0.05).

To evaluate the fit of the model we used Cox-Snell residuals and compared them with the Nelson Alan cumulative hazard function (Figure 3).

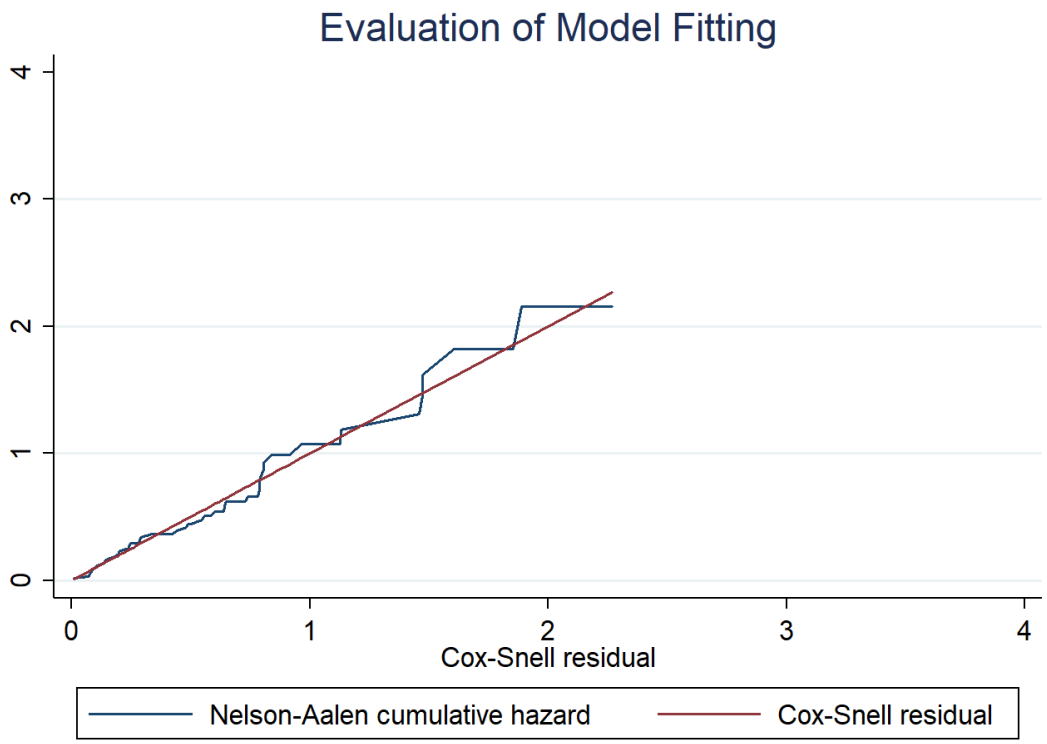

Figure 3 – The cox-snell residual plot for Cox PH model

The hazard function follows the 45-degree line very closely except for very large values of time. The final model fits the data well and is overall valid from a statistical standpoint.

Discussion

The prevalence of RPD in our patients (55.6%) was in line with other studies (11,14). We did not report a statistically significant difference between male and female sex like other studies did (8,11,15,16). Interestingly, patients that had RPD presented, on average, with more and bigger drusen than those without RPD.

Our observed conversion rate to late-stage AMD of 65.1% was in line with the literature (1,11,14). The 5-year progression from RPD to late-stage AMD (44.4%) was slightly higher than the 37.8% described in the Blue Mountain Eye Study (8) but lower than the 56% described in the 3-year cohort from the Nutritional AMD Treatment 2 study (17). Conversion was significantly higher to CNV than to GA (54% vs 11.1%) as expected (5,16), supporting the idea of a stronger association between RPD and CNV rather than GA (1).

The 49.4 months shorter progression to late-stage AMD on patients with RPD when compared to patients without RPD was among the most interesting findings. In fact, those patients convert 2.6 times faster. To our knowledge, this is the first study to present survival rates in fellow eyes of patients with CNV and reinforces the relevance of RPD in the progression of AMD.

Although its role as primary evidence of early stage AMD is debatable (6), the association between large-drusen and AMD is not new (8). We now go one step further by saying that they are accounted for increasing the rate of conversion nearly 5 times (HR: 4.96, 95% CI 1.96-12.53, $p<0.01$) when compared to patients without them.

We were surprised by the apparent protective effect that a drusen area over 700 µm conferred. It was an unexpected finding, possibly due to the fact that our sample was already

adjusted for the presence of large drusen and RPD *per se*. As a result, the increased area may be thanks to smaller drusen, which are not associated with progression to late-stage AMD (5).

This study has its limitations. Since it is a retrospective study of patients who participated in other studies, namely the Early Markers and CNV Markers studies, it does not represent a random sampling of patients with pseudodrusen. In fact, it was conducted in an already at-risk population: CNV was already present in the fellow eye. In future studies, the potential bias may be reduced by recurring to systematic sampling.

On the other hand, the present study also has strengths. The lengthy cohort of 5-years and the homogeneity between groups with and without RPD are important to draw meaningful comparisons. The uncompromised retinal imaging acquisition and grading protocol reassured us that close to no lesions were left undiagnosed. Few studies have been done regarding survival rates of these patients (8). In fact, using survival analysis allows to simultaneously account not only for the absolute influence of a factor on the outcome (in this case conversion to AMD) but also its influence of the speed of conversion. Knowing which factors influence speed of conversion might therefore be helpful in tailoring more intensive follow-up strategies for at risk patients.

Conclusion

In conclusion, our study demonstrated in a multivariate survival analysis model not only that presence of RPD and large drusen are associated with a higher risk of conversion to late-stage AMD in fellow eyes of patients with unilateral CNV but also their influence on the speed of conversion. Surprisingly, when already accounting for the presence of large drusen and RPD, increased total drusen area was actually associated with a smaller risk of conversion.

We recommend a strict multimodal imaging-based follow-up of patients who present with these lesions, given their influence in the speed of conversion.

Agradecimentos

Ao Professor Doutor Rufino Silva pela sugestão do tema e plena disponibilidade durante este longo período.

Ao Dr. José Costa por ter aceitado orientar esta tese e prestado precioso auxílio na recolha de dados.

Ao Dr. Miguel Raimundo pela paciência, disponibilidade e indispensável ajuda no tratamento estatístico.

À minha família, namorada e amigos pelo constante e incondicional apoio.

Referências

1. Gil JQ, Marques JP, Hogg R, Rosina C, Cachulo ML, Santos A, et al. Clinical features and long-term progression of reticular pseudodrusen in agerelated macular degeneration: Findings from a multicenter cohort. Eye. 2017;31(3):364–71.
2. Gheorghe A, Mahdi L, Musat O. Age-Related Macular Degeneration. Romanian J Ophthalmol. 2015;59(2):74–7.
3. Colijn JM, Buitendijk GHS, Prokofyeva E, Alves D, Cachulo ML, Khawaja AP, et al. Prevalence of Age-Related Macular Degeneration in Europe: The Past and the Future. Ophthalmology. 2017;124(12):1753–63.
4. Degeneration AM, Jonas JB, Ming C, Cheung G. Updates on the Epidemiology of Age-Related Macular Degeneration. Asia-Pacific J Ophthalmol. 2017;6(6):493–7.
5. Nivison-smith L, Milston R, Madigan M, Kalloniatis M.Age-Related Macular degeneration: Linking Clinical Presentation to Pathology. Optometry and vision Science. 2014;91(8):832–48.
6. Ferris FL, Wilkinson CP, Bird A, Chakravarthy U, Chew E, Csaky K, et al. Clinical classification of age-related macular degeneration. Ophthalmology. 2013;120(4):844–51.
7. Zweifel SA, Spaide RF, Curcio CA, Malek G, Imamura Y. Reticular Pseudodrusen Are Subretinal Drusenoid Deposits. Ophthalmolog. 2010;117(2):303–312.e1.
8. Joachim N, Mitchell P, Rochtchina E, Tan AG, Wang JJ. Incidence and progression of reticular drusen in age-related macular degeneration: Findings from an older Australian cohort. Ophthalmology. 2014;121(4):917–25.
9. Wenick AS, Bressler NM, Bressler SB. "Age-Related Macular Degeneration: Non-Neovascular Early AMD, Intermediate AMD, and Geographic Atrophy" *in Ryan's Retina*. London: Elsevier, 2017. 1293-344, Print.

10. Sivaprasad S, Bird A, Nitiahpapand R, Nicholson L, Hykin P, Chatziralli I. Perspectives on reticular pseudodrusen in age-elated macular degeneration. Surv Ophthalmol. 2016;61(5):521–37.

11. Hogg RE, Silva R, Staurenghi G, Murphy G, Santos AR, Rosina C, et al. Clinical characteristics of reticular pseudodrusen in the fellow eye of patients with unilateral neovascular age-related macular degeneration. Ophthalmology. 2014;121(9):1748–55.

12. Cachulo MDL, Lobo C, Figueira J, Ribeiro L, Laíns I, Vieira A, et al. Prevalence of age-related macular degeneration in Portugal: The Coimbra eye study - Report 1. Ophthalmologica. 2015;233:119–27.

13. Marques JP, Costa M, Melo P, Oliveira CM, Pires I, Cachulo ML, et al. Ocular Risk Factors for Exudative AMD: A Novel Semiautomated Grading System. ISRN Ophthalmol. 2013;2013(3):464218.

14. Finger RP, Wu Z, Luu CD, Kearney F, Ayton LN, Lucci LM, et al. Reticular pseudodrusen: A risk factor for geographic atrophy in fellow eyes of individuals with unilateral choroidal neovascularization. Ophthalmology. 2014;121(6):1252–6.

15. Klein R, Meuer SM, Knudtson MD, Iyengar SK, Klein BEK. The Epidemiology of Retinal Reticular Drusen. Am J Ophthalmol. 2008;145(2).

16. Smith RT, Sohrab MA, Busuioc M, Barile G. Reticular Macular Disease. Am J Ophthalmology. 2009;148(5):733–743.e2.

17. Pumariega NM, Smith RT, Sohrab MA, Letien V, Souied EH. A prospective study of reticular macular disease. Ophthalmology. 2011;118(8):1619–25.