

## Research Article

# Preventive but Not Curative Efficacy of Celecoxib on Bladder Carcinogenesis in a Rat Model

José Sereno,<sup>1</sup> Belmiro Parada,<sup>1,2</sup> Flávio Reis,<sup>1,3</sup> Fernanda X. Cunha,<sup>4</sup>  
Edite Teixeira-Lemos,<sup>1</sup> Patrícia Garrido,<sup>1</sup> Rui Pinto,<sup>5</sup> Petronila Rocha-Pereira,<sup>3,6</sup>  
Paula Neto,<sup>4</sup> José Ruivo,<sup>4</sup> Paulo Rodrigues-Santos,<sup>7</sup> Sara Nunes,<sup>1</sup> Alfredo Mota,<sup>2</sup>  
Arnaldo Figueiredo,<sup>1,2</sup> and Frederico Teixeira<sup>1,3</sup>

<sup>1</sup>Institute of Pharmacology & Experimental Therapeutics, IBILI, Medicine Faculty, Sub-Unit 1 (Polo III), Coimbra University, 3000-354 Coimbra, Portugal

<sup>2</sup>Department of Urology & Renal Transplantation, Coimbra University Hospital, 3000-075 Coimbra, Portugal

<sup>3</sup>Institute for Molecular and Cellular Biology, Porto University, 4150 Porto, Portugal

<sup>4</sup>Service of Anatomic Pathology, Coimbra University Hospital, 3000-075 Coimbra, Portugal

<sup>5</sup>Pharmacology & Pharmacotoxicology Unit, Pharmacy School of Lisbon, 1649-003 Lisboa, Portugal

<sup>6</sup>Research Centre for Health Sciences, Beira Interior University, 6201-001 Covilhã, Portugal

<sup>7</sup>Immunology & Oncology Laboratory, Centre for Neuroscience and Cell Biology, 3004-517 Coimbra, Portugal

Correspondence should be addressed to Frederico Teixeira, fredjt@ci.uc.pt

Received 29 July 2010; Revised 23 October 2010; Accepted 2 December 2010

Academic Editor: Fulvio D'Acquisto

Copyright © 2010 José Sereno et al. This is an open access article distributed under the Creative Commons Attribution License, which permits unrestricted use, distribution, and reproduction in any medium, provided the original work is properly cited.

To evaluate the effect of a cyclooxygenase 2 inhibitor, celecoxib (CEL), on bladder cancer inhibition in a rat model, when used as preventive versus as curative treatment. The study comprised 52 male Wistar rats, divided in 5 groups, during a 20-week protocol: control: vehicle, carcinogen: 0.05% of *N*-butyl-*N*-(4-hydroxybutyl) nitrosamine (BBN), CEL: 10 mg/kg/day of the selective COX-2 inhibitor Celebrex, preventive CEL (CEL+BBN-P), and curative CEL (BBN+CEL-C) groups. Although tumor growth was markedly inhibited by the preventive application of CEL, it was even aggravated by the curative treatment. The incidence of gross bladder carcinoma was: control 0/8(0%), BBN 13/20(65%), CEL 0/8(0%), CEL+BBN-P 1/8(12.5%), and BBN+CEL-C 6/8(75%). The number and volume of carcinomas were significantly lower in the CEL+BBN-P versus BBN, accompanied by an ample reduction in hyperplasia, dysplasia, and papillary tumors as well as COX-2 immunostaining. In spite of the reduction of tumor volumes in the curative BBN+CEL-C group, tumor malignancy was augmented. An anti-inflammatory and antioxidant profile was encountered only in the group under preventive treatment. In conclusion, preventive, but not curative, celecoxib treatment promoted a striking inhibitory effect on bladder cancer development, reinforcing the potential role of chemopreventive strategies based on cyclooxygenase 2 inhibition.

## 1. Introduction

Bladder cancer is a prevalent tumor, accounting for 5%–10% of all malignancies in Western countries [1, 2]. It has a high recurrence and progression rate and the prognosis, except for superficial forms, is poor [3]. Furthermore, it has high mortality rates and socioeconomic costs [4, 5]. The conventional surgical techniques and therapeutic options might cause discomfort to patients, especially in invasive and aggressive forms of cancer [6, 7]. Therefore,

the improvement of bladder cancer management and treatment could rely on better preventive strategies. The identification of promising drugs remains dependent on a better elucidation of the molecular/cellular mechanisms underlying cancer appearance and progression [8, 9]. Apart from the genetic features and markers already characterized [10, 11], the cellular and molecular mechanisms for development and/or progression might involve inflammatory, proliferative, and oxidative stress phenomena that should be better elucidated.

Inflammation through the cyclooxygenase (COX) pathway has been involved in cancer development [12]. While COX-1 is constitutively expressed in a huge range of tissues, playing a role in prostaglandins production and maintenance of homeostasis, COX-2 expression is induced by cytokines and growth/tumor factors, usually as a reaction to an inflammatory process [13]. Previous studies have been suggesting a key role of COX-2 in carcinogenesis [12, 14] and its modulation has been associated with reduction of tumor incidence in experimental and clinical studies for distinct types of carcinomas [15–17]. Since COX-2 overexpression has been reported in bladder tumors [8, 18–21], COX-2 inhibitors (Coxibs) might be viewed as promising for chemoprevention of this cancer.

Bladder cancer, induced in rats with the carcinogen *N*-butyl-*N*-(4-hydroxybutyl) nitrosamine (BBN), has been used as a model for study pathophysiology and therapeutics of this cancer [22], particularly due to the histological similarities with the human transitional cell carcinoma [23, 24]. Previous studies have demonstrated a positive response to some prevention strategies [25, 26], but the curative efficacy of new and promising pharmacological options, such as the celecoxib, remains to be elucidated. Considering the poor prognosis for a high percentage of the patients diagnosed for bladder cancer, as well as the high recurrence and progression rates, curative strategies might assume a key relevance in the management/treatment of these carcinomas in many patients.

This study aimed to evaluate, using a rat bladder carcinogenesis model, the preventive versus curative efficacy of the COX-2 inhibitor Celecoxib (CEL) on bladder cancer.

## 2. Material and Methods

**2.1. Animals and Groups.** Male Wistar rats (Charles River Lab. Inc, Barcelona, Spain), 250–285 g, were maintained in an air-conditioned room, subjected to 12-hour dark/light cycles and given standard laboratory rat chow (IPM-R20, Letica, Barcelona, Spain) and free access to tap water. Animal experiments were conducted according to the European Community Council Directives on Animal Care and with the National Institutions for Science & Technology.

The animals were divided in five groups: control group ( $n = 8$ ): vehicle (orange juice); carcinogen (BBN) group ( $n = 20$ ): 0.05% of *N*-butyl-*N*-(4-hydroxybutyl) nitrosamine (Tokyo Chemical Industry Co., Ltd, Tokyo, Japan); celecoxib (CEL) group ( $n = 8$ ): 10 mg/kg/day of the selective COX-2 inhibitor celebrex (Laboratórios Pfizer, S.a., Lisbon, Portugal); preventive celecoxib group ( $n = 8$ ): CEL+BBN-P; curative celecoxib group ( $n = 8$ ): BBN+CEL-C. Treatments were performed according to a two-step protocol: a first period of eight weeks for tumor induction and pharmacological treatment (orange juice, BBN, CEL control, and preventive CEL) and a second one of 12 weeks for cancer expression/prevention. In the curative treatment, rats were first treated with BBN for 8 weeks and, thereafter, with CEL until the week 20. BBN was given in drinking water and orange juice (given to all groups) and CEL (prepared

in vehicle) were given by an esophageal cannula. All the animals have completed the 20-week protocol. Body weight and beverage consumption were monitored during the entire experiment.

### 2.2. Tumor Data Analysis

**2.2.1. Bladder Removal.** The rats were sacrificed by cervical dislocation, and the lungs, stomach, liver, kidneys, and intestines were immediately removed, weighted, and placed in formaldehyde for further analysis. Before removal, bladders were intraluminally injected with a buffered formaldehyde solution as prefixation for histological analyses.

**2.2.2. Quantitative Analysis (Number and Volume of Tumors).** Each bladder prefixed in formaldehyde was carefully opened, the lumen was inspected for grossly visible lesions and the number of tumors per rat and the volume of each tumor were reported in order to further calculate the % of tumor per group and the mean volume per rat and tumor.

**2.2.3. Qualitative Analysis (Bladder Histology).** The bladder was immersion-fixed in 4% buffered formaldehyde and processed for paraffin sectioning. Three slices from each bladder were embedded. Three micrometer thick sections were stained with haematoxylin and eosin (H&E) and examined histologically by one author (M.F. Cunha) unknowing the treatments.

### 2.3. Renal and Liver Data

**2.3.1. Blood Collection and Preparation.** At the end of treatments the rats were injected with intraperitoneal anesthesia with 2 mg/Kg BW of a 2:1 (v:v) 50 mg/mL Ketamine (Ketalar, Parke-Davis, Pfizer Lab., Seixal, Portugal) solution in 2.5% chlorpromazine (Largatil, Rhône-Poulenc Rorer, Vitória lab., Amadora, Portugal). Blood samples were immediately collected by venipuncture from the jugular vein in needles with no anticoagulant (for serum samples collection).

**2.3.2. Renal and Liver Data.** Serum creatinine, urea, and uric acid concentrations were used as renal function indexes and serum aspartate aminotransferase (AST) and alanine aminotransferase (ALT) levels were assessed for liver evaluation, through automatic validated methods and equipments (Hitachi 717 analyser, Roche Diag. Inc., MA, USA).

**2.4. COX-2 Immunostaining.** Formalin-fixed, paraffin-embedded tissue blocks were sectioned at 5 mm thickness, and immunostaining was performed using the avidin-biotin peroxidase method. Sections were deparaffinized and blocked for endogenous peroxidase in 0.3% H<sub>2</sub>O<sub>2</sub> in methanol for 20 minutes. Antigen enhancement was performed by pretreating with microwave heating in a citrate buffer, pH 6.00 (twice for 5 minutes each at 750 W). The slides were washed three times, 2 minutes each, and then incubated with blocking serum for 10 minutes to

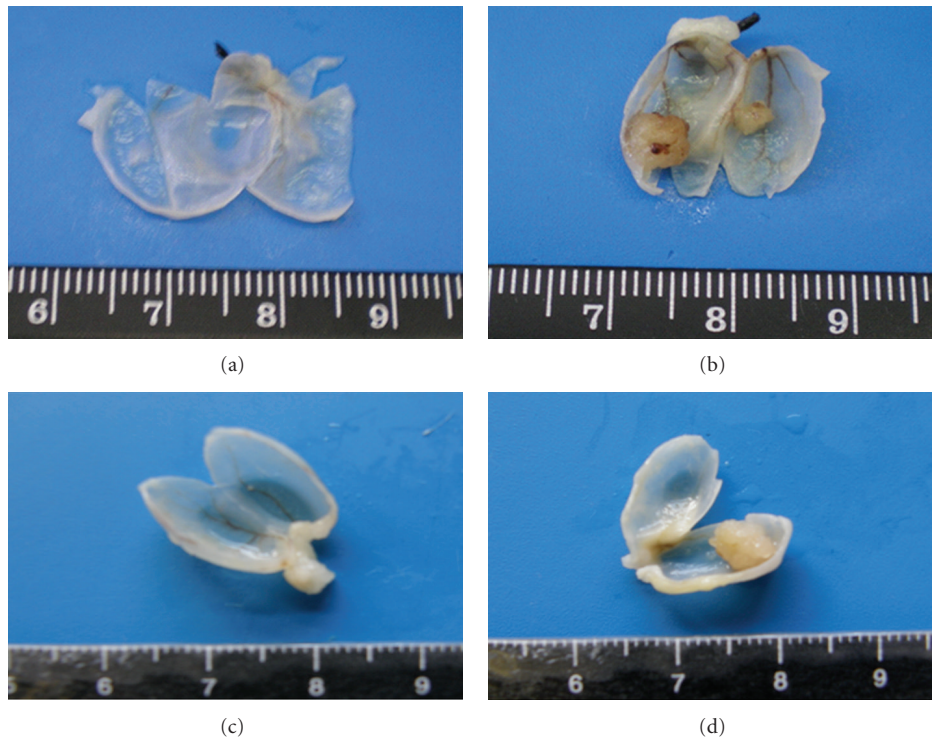


FIGURE 1: Macroscopic histomorphological evaluation of bladders. All the bladders from the control (a) and CEL (data not shown) treated rats have revealed a pattern of normality, with absence of any type of malignancy. In the BBN group (b), 65.0% of the rats had bladder tumors, almost all easily seen by macroscopic analysis. The bladder walls were thicker, with new or enlarged small vessels, suggesting neo-angiogenesis, and there was unequivocal formation of tumor (some bladder presented more than one tumor). In the preventive CEL (CEL+BBN-P group) treatment (c), except in one case, all bladders shows a similar pattern to those seen for the control or CEL rats, with macroscopically unrecognized signs of abnormality. However, in the curative CEL (BBN+CEL-C group) use (d), there was 75% of tumor incidence, with even more malignant neoplastic lesions.

block the nonspecific binding. The excess of blocking serum was removed, and then the sections were incubated at 4C overnight with primary polyclonal antibody against COX-2 at proper dilution and secondary antibody was then applied (Cayman Chemical Co., Ann Arbor, MI, USA). Reactivity was visualized with an avidin-biotin complex immunoperoxidase system using diaminobenzidine as the chromogen and Mayer's hematoxylin as the counterstain. Sections of normal urothelium were included in all experiments. In addition, many tumor sections contained adjacent normal bladder mucosa, which served as internal controls. Known strong COX-2 staining specimens served as positive controls. All slides were reviewed independently by 2 investigators blinded to the data.

**2.5. Serum Inflammatory Profile and Redox Status.** Serum levels of interleukin  $1\beta$  (IL- $1\beta$ ) were measured by ultrasensitive Quantikine ELISA kits (R&D Systems, Minneapolis, USA) and C-reactive protein (CRP) by using an ELISA kit from Helica Biosystems, Inc. (Fullerton, CA, USA). All assays were performed in duplicate.

The thiobarbituric acid reactive-species (TBARS) assay was used to assess serum products of lipid peroxidation, via malondialdehyde (MDA), according to previously

described [27]. Samples were analysed spectrophotometrically at 532 nm using 1,1,3,3-tetramethoxypropane as external standard. The serum concentration of lipid peroxides (in MDA) was expressed as  $\mu\text{mol/l}$ . Ferric reducing antioxidant potential (FRAP) assay was used to estimate serum total antioxidant status (TAS) [28].

**2.6. Statistical Analysis.** We used the Statview 4.53 software from Abacus Concepts Inc. (Berkeley, CA, USA). Results are means  $\pm$  standard error of means (SEM). Comparisons between groups were performed using ANOVA and Mann-Whitney post hoc test. Significance was accepted at  $P$  less than .05.

### 3. Results

#### 3.1. Preventive versus Curative Effect of Celecoxib on Tumor Growth

**3.1.1. Macroscopic Evaluation.** All formaldehyde prefixed bladders were opened and analysed macroscopically for wall (urothelium) texture, thickness, and vascularization (Figure 1). The number of rats with tumor, the number of tumors per rat, and the volume of each tumor were reported

TABLE 1: The preventive versus curative effect of Celecoxib on bladder cancer: quantitative evaluation of urothelium lesions.

Macroscopy (quantitative)	Control ( <i>n</i> = 8)	CEL ( <i>n</i> = 8)	BBN ( <i>n</i> = 20)	CEL+BBN-P ( <i>n</i> = 8)	BBN+CEL-C ( <i>n</i> = 8)
Tumor number (%)					
% of rats with tumor	0	0	(13 in 20) 65.0%	(1 in 8) 12.5%	(6 in 8) 75.0%
Nr tumors/rat with tumor	0	0	1.2 ± 0.1 (16 in 13)	4.0 <sup>†</sup> (4 in 1)	1.8 ± 0.5 (11 in 6)
Tumor volume (mm <sup>3</sup> )					
Mean/rat with tumor	0	0	138.5 ± 7.5 (in 13)	21.2 <sup>†</sup> (in 1)	59.8 ± 20.8 (in 6)
Mean/tumor	0	0	112.5 ± 6.4 (in 16)	5.3 ± 0.4 (in 4)	35.9 ± 14.8 (in 11)

<sup>†</sup>Represents only 1 rat in 8 of the group (s.e.m. in not applicable). Values are mean ± SEM, excepting for % of rats with tumor. BBN: *N*-butyl-*N*-(4-hydroxybutyl) nitrosamine; CEL: celecoxib; C: curative; P: preventive.

TABLE 2: The preventive versus curative effect of Celecoxib on bladder cancer: qualitative evaluation of urothelium lesions.

Microscopy (qualitative)	Control ( <i>n</i> = 8)	CEL ( <i>n</i> = 8)	BBN ( <i>n</i> = 20)		CEL+BBN-P ( <i>n</i> = 8)		BBN+CEL-C ( <i>n</i> = 8)	
			Tumor group	Total group	Tumor group	Total group	Tumor group	Total group
Preneoplastic lesions: %(nr/nr)								
Hyperplasia	0	0	100 (13/13)	100 (20/20)	100 (1/1)	37.5 (3/8)	100 (6/6)	100 (8/8)
High-Grade Dysplasia	0	0	100 (13/13)	75 (15/20)	0 (0/1)	0 (0/8)	14 (1/6)	12.5 (1/8)
Low-Grade Dysplasia	0	0	0 (0/13)	25 (5/20)	100 (1/1)	12.5 (1/8)	83 (5/6)	62.5 (5/8)
Neoplastic lesions: %(nr/nr)								
Papillary tumor	0	0	100 (13/13)	65 (13/20)	100 (1/1)	12.5 (1/8)	100 (6/6)	75 (6/8)
Infiltrative tumor	0	0	15 (2/13)	10 (2/20)	0 (0/1)	0 (0/8)	0 (0/6)	0 (0/8)
Carcinoma <i>In Situ</i>	0	0	31 (4/13)	20 (4/20)	0 (0/1)	0 (0/8)	0 (0/6)	0 (0/8)

BBN: *N*-butyl-*N*-(4-hydroxybutyl) nitrosamine; CEL: celecoxib; C: curative; P: preventive.

in order to further calculate the % of rats with tumor in each group, the number of tumors per rat with tumor, as well as the mean tumor volume per rat and per tumor (Table 1).

All the bladders from the control animals have revealed a pattern of normality, with absence of any type of malignity. The wall texture, thickness, and vascularization were normal (Figure 1(a)). Similar profile was found for the CEL group, with limpid, translucent, and tiny bladders, without presence of any abnormal mass or vascularization (data not shown). In the BBN group, however, 65.0% of the rats had bladder tumors, almost all easily seen by macroscopic analysis. The bladder walls were thicker, with new or enlarged small vessels, suggesting neo-angiogenesis, and there was unequivocal formation of tumor. Furthermore, some bladders presented more than one tumor (Figure 1(b)). In the preventive CEL+BBN-P group, apart from one case, all bladders show a similar pattern to those seen for the control or CEL rats, with macroscopically unrecognized signs of abnormality (Figure 1(c)), which contrasts with the bladders from the curative BBN+CEL-C group (Figure 1(d)).

**3.1.2. Quantitative Evaluation.** In the control group, as expected, no rat developed bladder cancer. The same profile was found for the CEL animals. In the BBN group (*n* = 20 rats), the percentage of rats with bladder cancer was 65.0% (13 in 20), with a mean of 1.2 ± 0.1 tumors per rat with tumor. Furthermore, the mean tumor volume per rat with tumor (in 13 rats) was 138.5 ± 7.5 mm<sup>3</sup> and the mean tumor

volume per tumor (in 16 tumors) was 112.5 ± 6.4 mm<sup>3</sup> (Table 1). In the preventive CEL treatment (CEL+BBN-P group), there was notorious bladder cancer prevention, with a percentage of tumors in the group of 12.5% (1 in 8), which corresponds to only one rat with cancer in the group universe of 8 animals. In agreement, the mean tumor volume per rat with tumor was 21.2 and per tumor (in 4 tumors of only 1 rat) was 5.3 ± 0.4 mm<sup>3</sup> (Table 1). This pattern contrasts with the ineffective curative CEL treatment (BBN+CEL-C group), which did not show relevant inhibitory effect on tumor growth, demonstrated by the even higher percentage of rats with tumors 75% (6 in 8) and number of tumors per rat with tumour (1.8 ± 0.5, representative of 11 tumors in 6 bladder with tumor), versus the BBN group. However, the decreased tumor volume should be reported: the mean tumor volume per rat with tumor (in 6 rats) was 59.8 ± 20.8 mm<sup>3</sup> and the mean tumor volume per tumor (in 11 tumors) was 35.9 ± 14.8 mm<sup>3</sup> (Table 1).

**3.1.3. Qualitative Evaluation.** Concerning the microscopic analysis of urothelium layer and urothelial tumors, the control and the CEL rats have shown normal patterns (Figures 2(a) and 2(b), resp.). The bladder from control animals had no signs of preneoplastic lesions (neither hyperplasia nor dysplasia), as well as those from the CEL rats (Table 2). In the carcinogen (BBN) group, there was evident malignant transformation, including hyperplasia (100%) and dysplasia (100%), present in all the animals, including those without

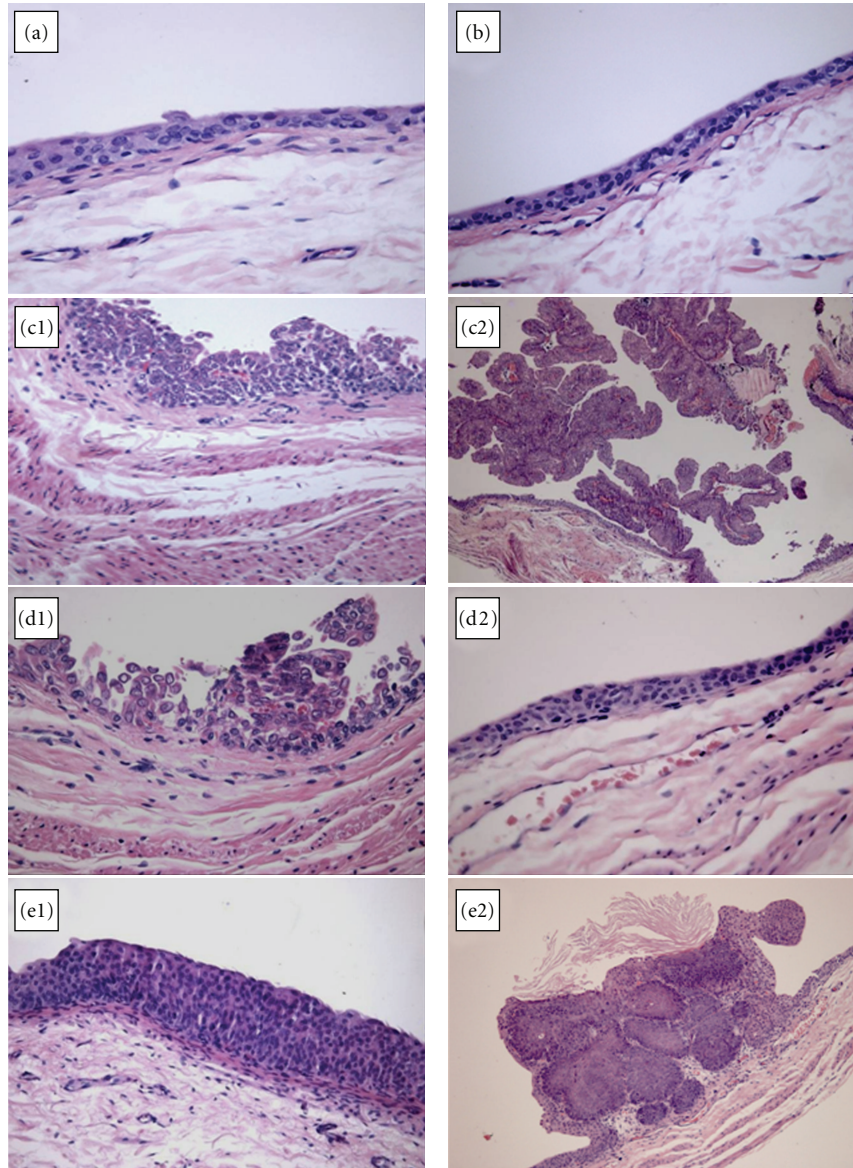


FIGURE 2: Microscopic histomorphological evaluation of bladder urothelium. The bladder from control (a) and CEL (b) treated rats had no signs of preneoplastic lesions (neither hyperplasia nor dysplasia) or gross tumor formation. In the carcinogen (BBN) group (c), the bladder from all the animals presented hyperplasia and high-grade dysplasia (c1), including those without tumor formation, as well as malignant lesions, mainly papillary tumors (c2), but also infiltrative and CIS. In the preventive CEL+BBN-P treatment (d), only one bladder of the 8 rats presented tumor formation with dysplasia (d1), while all the other rats have presented a normal urothelium profile (d2), contrasting with the pattern found in the curative CEL (BBN+CEL-C group) use (e), which reveals preneoplastic, including high-grade hyperplasia and dysplasia (e1), and neoplastic lesions, even more malignant (e2) (H&E staining (x100)).

tumor formation (Table 2 and Figure 2(c1)). Furthermore, there were also malignant lesions, papillary, infiltrative, and CIS (Table 2 and Figure 2(c2)). The preventive use of CEL (group CEL+BBN-P) has undoubtedly prevented bladder cancer development. Therefore, as above mentioned, only one bladder of the 8 rats from the group has shown cancer development (12.5% of the rats from the group) (Table 1). Apart from the rat with tumors (all papillary), whose urothelium has demonstrated hyperplasia and dysplasia, without infiltrative or CIS (Table 2 and Figure 2(d1)), all the other rats have presented a normal urothelium profile

(there was only low-grade hyperplasia in two of those 7 animals) (Table 2 and Figure 2(d2)). On the contrary, the curative CEL treatment (BBN+CEL-C group), despite lower tumor volume (Table 1), not only did not reverse tumor (75%) and preneoplastic lesions (hyperplasia and metaplasia) development (Table 2 and Figure 2(e1)) but also promoted increased malignancy, presenting more aggressive (T1G2) carcinomas (Table 2 and Figure 2(e2)).

The lungs, stomach, liver, kidneys, and intestines were normal on gross inspection and on histological examination for all the groups under study. Body weight and beverage

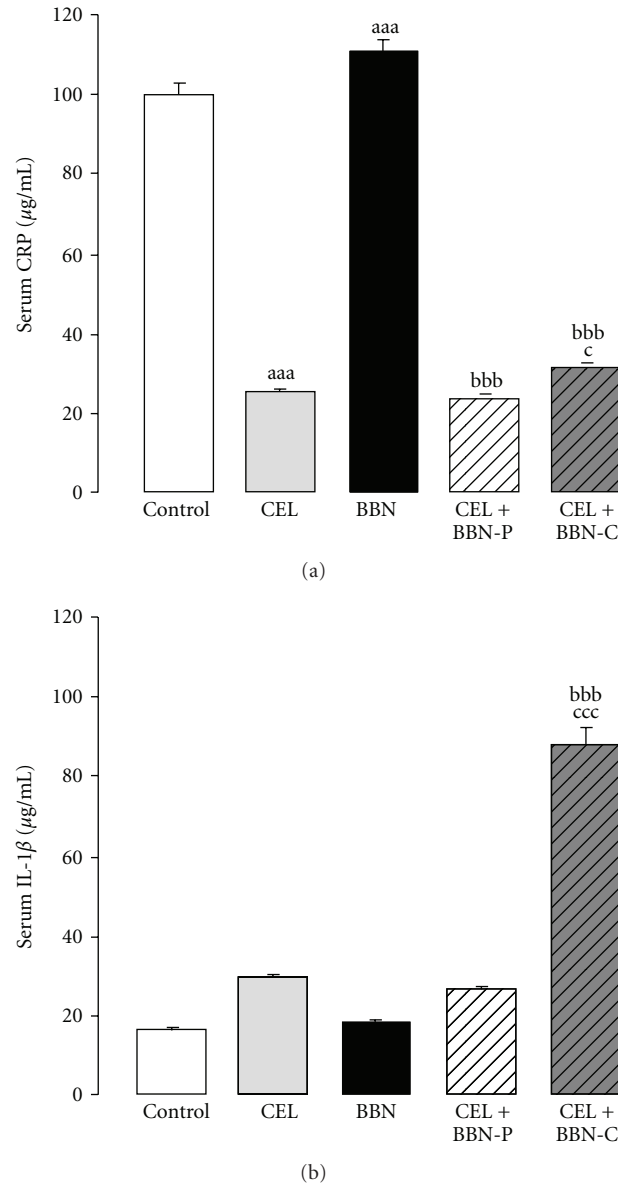


FIGURE 3: Serum markers of inflammation: C-Reactive Protein (a) and Interleukin-1 $\beta$  (IL-1 $\beta$ )—in the five groups under study. Values are mean  $\pm$  SEM. <sup>aaa</sup>- $P < .001$  versus the control group; <sup>bbb</sup>- $P < .001$  versus the BBN group and <sup>c</sup>- $P < .05$  and <sup>ccc</sup>- $P < .001$  versus the CEL+BBN-P group.

consumption were almost unchanged between the groups, not interfering with the tumor data analysis (data not shown).

**3.2. Serum Inflammatory Profile and Redox Status Markers.** Serum CRP levels were significantly higher ( $P < .001$ ) in the BBN rats, when compared with the control animals. In all the CEL groups, however, CRP concentration was substantially lower ( $P < .001$ ) than that of the control and BBN rats (Figure 3(a)). Serum IL-1 $\beta$  contents were unchanged between the control, CEL, and BBN groups. While in the preventive CEL treatment (CEL+BBN-P group) the concentration was identical to those of the BBN rats, in the curative CEL use (BBN+BBN-C group) there was

a remarkable increment ( $P < .001$ ) in IL-1 $\beta$  serum levels (Figure 3(b)).

Concerning the serum redox status markers, in the BBN rats there was a trend to higher serum lipid peroxidation marker (MDA) content versus the control, and a significant reduction ( $P < .05$ ) in the CEL rats. While the preventive CEL treatment (CEL+BBN-P group) promoted a reduction ( $P < .01$ ) of serum MDA, versus the BBN group, the curative CEL use (BBN+BBN-C group) further significantly aggravated ( $P < .001$ ) the MDA increment (Figure 4(a)). This group also shows a significant augment of serum total antioxidant status (TAS), eventually as a counteraction against the increment of reactive species (which is suggested by the notable MDA increase). All the other groups showed

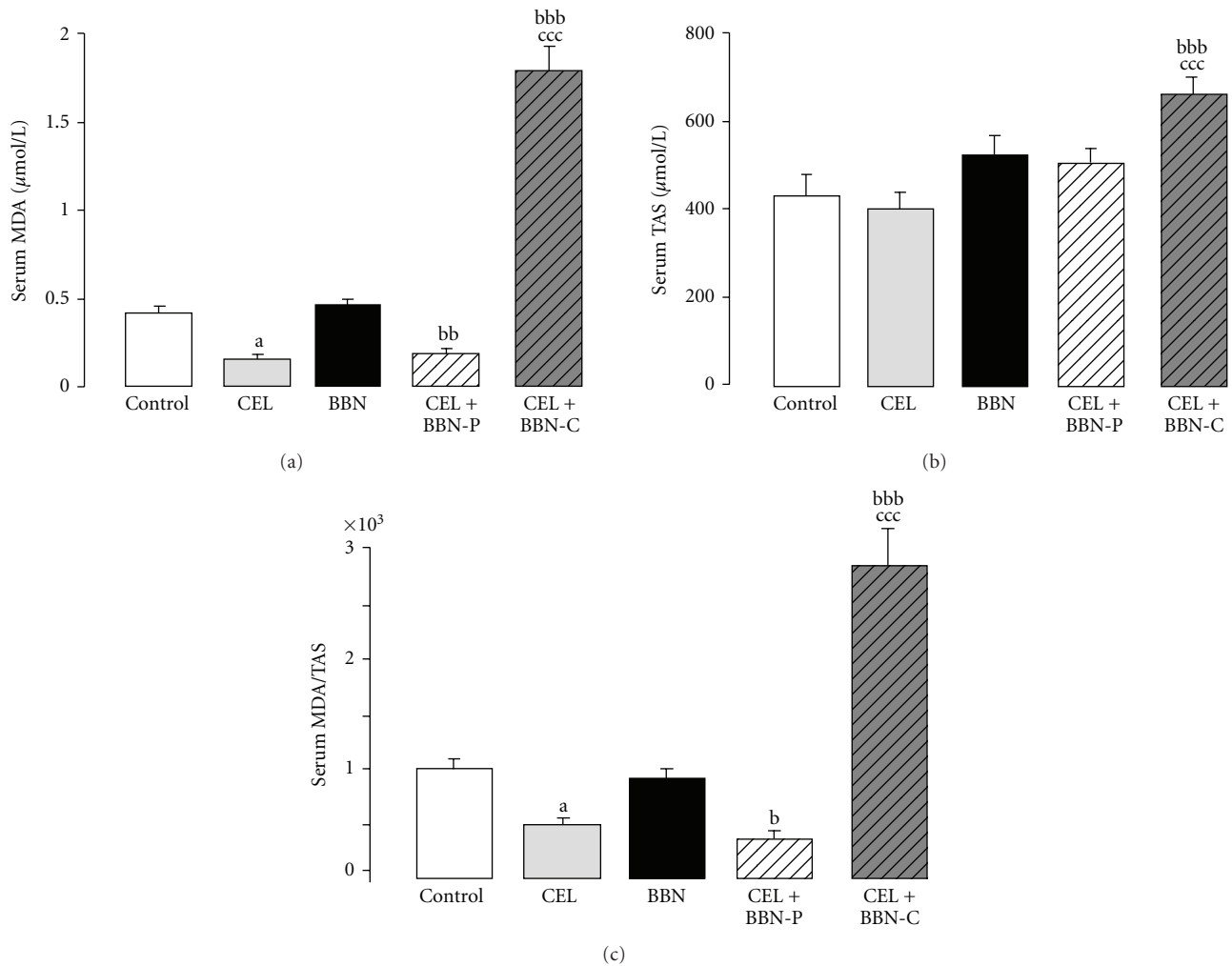


FIGURE 4: Serum markers of redox status: lipid peroxidation, through MDA (a), total antioxidant status (b), and MDA/TAS (c)—in the five groups under study. Values are mean  $\pm$  SEM. <sup>a</sup>- $P$  < .05 versus the control group; <sup>b</sup>- $P$  < .05, <sup>bb</sup>- $P$  < .01, and <sup>bbb</sup>- $P$  < .001 versus the BBN group; <sup>ccc</sup>- $P$  < .001 versus the CEL+BBN-P group.

an unchanged pattern for serum TAS (Figure 4(b)). As a result, the ratio MDA/TAS was reduced in the CEL group and unchanged in the BBN rats, versus the control significantly diminished in the preventive CEL treatment (CEL+BBN-P group), and notably increased in the curative CEL group (BBN+BBN-C), versus the BBN animals (Figure 4(c)).

**3.3. COX-2 Immunostaining.** In the control (Figure 5(a)) and CEL groups (Figure 5(b)), COX-2 immunostaining was only slightly evident in the external urothelium layer, demonstrating even less presence in the suburothelial layers. However, in the BBN group, both the areas of preneoplastic lesions (such as hyperplasia, Figure 5(c1)) and of neoplastic formations (such as papillary tumors, Figure 5(c2)) were intensely stained for COX-2, demonstrating an unequivocal overexpression. In the preventive CEL+BBN-P treatment (d), only one bladder of the 8 rats presented tumor formation, in which COX-2 staining was encountered, but only in the external layer of the papillary tumor region

(Figure 5(d1)), while no significant staining was found in the nontumoral urothelium (Figure 5(d2)). In the curative CEL treatment (BBN+CEL-C group), in which Celecoxib use was performed between the weeks 12 and 20, after which the bladders were collected, the non-neoplastic areas showed a clear inhibition of COX-2 (Figure 5(e1)), which is in agreement with the treatment performed. However, in the tumor lesion, an intense COX-2 immunostaining was found (Figure 5(e2)), demonstrating a clear overexpression, similar to that encountered in the BBN-treated rats.

**3.4. Renal and Liver Data.** In the BBN group, there was a trend to lower values of urea and higher of uric acid, when compared with the control group, without significant changes of serum creatinine content. An inversely profile, also nonsignificant, was found for the CEL group. In the group under preventive CEL+BBN-P treatment, all biochemical renal parameters (creatinine:  $64.53 \pm 2.65$   $\mu$ mol/L; urea:  $18.55 \pm 0.71$   $\mu$ mol/L and uric acid:

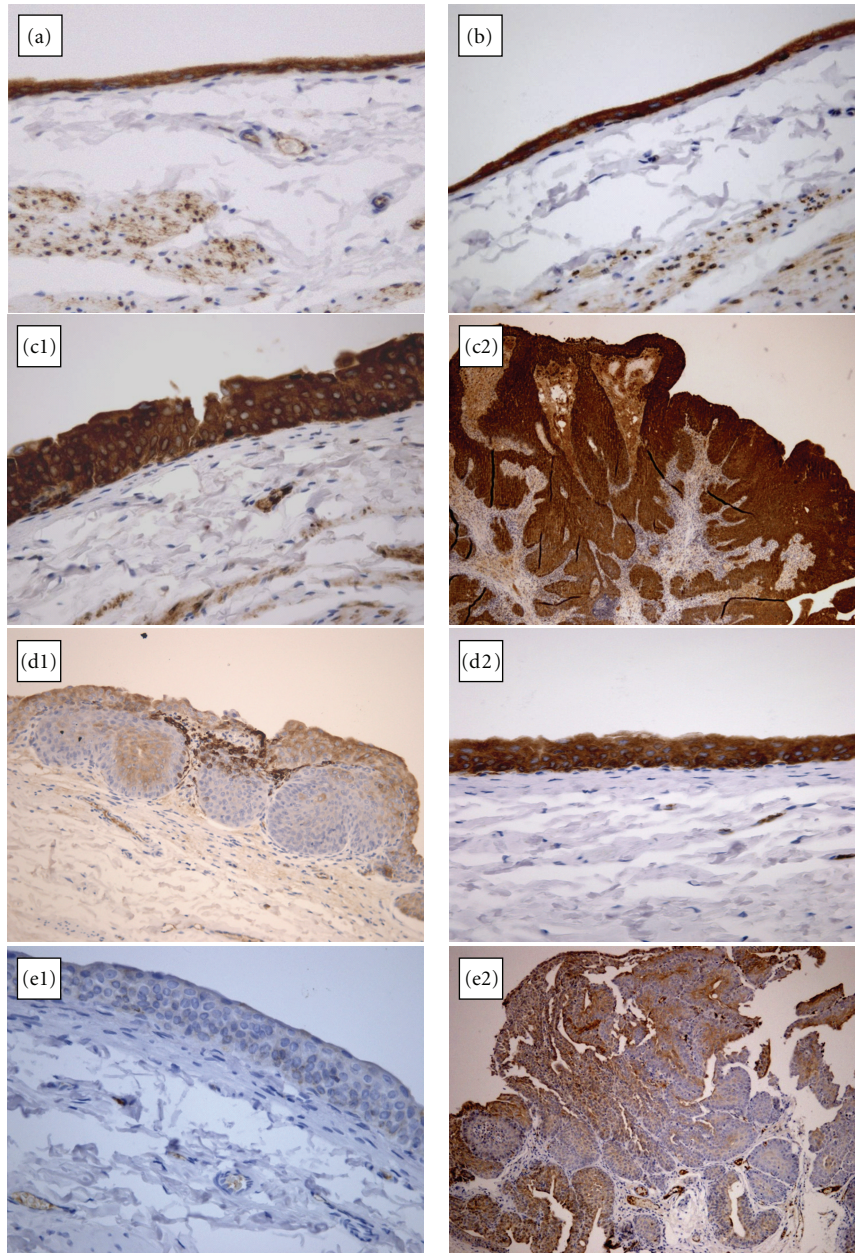


FIGURE 5: COX-2 immunohistochemistry (the positivity is the brown nuclear staining) in the five groups under study: control (a), CEL (b), carcinogen (BBN) group (c1 and c2), preventive CEL+BBN-P treatment (d1 and d2), and curative CEL (BBN+CEL-C group) use (e1 and e2) (original magnification X 400).

109.44 ± 14.87 μmol/L) were significantly ( $P < .01$ ) higher than those in the BBN group (54.81 ± 1.77; 13.50 ± 0.47, and 57.10 ± 7.14, resp.), contrasting with the curative BBN+CEL-C one that showed unchanged creatinine (54.70 ± 1.58) and urea (12.64 ± 0.41) levels and lower ( $P < .05$ ) of uric acid (39.19 ± 5.15).

Concerning the liver data, AST (78.15 ± 6.04 IU/L) and ALT (38.15 ± 2.92 IU/L) for the BBN rats were higher ( $P < .05$ ) than those in the control animals (51.57 ± 1.09 and 30.86 ± 1.75, resp.), contrasting with the profile of the CEL group, identical to that of the control. However, in the CEL+BBN-P group, both parameters (64.57 ± 4.30 and

30.14 ± 2.58, resp.) were substantially lower ( $P < .01$ ) than those of the BBN rats, mimicking those of the CEL rats and closer to those of the control, again contrasting with the BBN+CEL-C data that revealed substantial higher values of both AST (102.11 ± 11.24;  $P < .05$ ) and ALT (54.00 ± 5.14;  $P < .001$ ) versus the BBN rats.

#### 4. Discussion

The present study is part of an ongoing preclinical research concerning the effects of distinct agents against urinary bladder cancer prevention or reversion. The main purpose



was the assessment of whether the COX-2 inhibitor celecoxib is effective as preventive or curative therapy for bladder carcinogenesis in an animal model previously described in the literature using 0.05% of BBN as the carcinogen inductor [22].

In recent years, there has been a great interest in the question of whether COX-2 inhibitors could prevent/revert carcinogenesis through COX-2 modulation, which seems to play a key role in cancer development [12, 14]. Since COX-2 downregulation has been positively linked to chemoprevention in other tissues and organs [15–17], its efficacy deserves further research on the bladder cancer. Considering that, the second step of our work was to evaluate the potential preventive and curative effect of COX-2 inhibition on bladder carcinoma development and progression. The main finding was that tumor growth is undoubtedly inhibited by CEL treatment, with an incidence of only 12.5% (1 in 8 rats), with a reduced mean tumor volume per tumor of  $5.3 \pm 0.4 \text{ mm}^3$  (in 4 tumors of 1 rat), contrasting with the data from the BBN rats: 65% and  $112.5 \pm 6.4 \text{ mm}^3$  (in 16 tumors of 13 rats with tumor), respectively. Furthermore, and even more relevant, apart from the rats with tumors (all papillary), whose urothelium has demonstrated hyperplasia and dysplasia of low-grade, without infiltrative or CIS, all the other rats (7 in 8) have presented a normal urothelium profile (there was only low-grade hyperplasia in two of those 7 animals). These data confirm that this drug is effective not only for chemoprevention of gross tumor appearance and growth but also for prevention of preneoplastic lesions formation. These data were reinforced by the pattern of immunochemistry found for the group, in which staining was encountered only in the external layer of the papillary tumor region, while no significant staining was found in the nontumoral urothelium.

Our study showed a remarkable chemopreventive efficacy on tumor growth using a lower COX-2 inhibitor dose (10 mg/kg) than those tested in other studies (200, 500, and 1250 mg/kg) [29] and that better reproduce the doses clinically used for anti-inflammatory actions, thus reinforcing the markedly promising results. Moreover, apart from some deterioration of renal markers, which might be due to deregulation of renal prostanoids pathway or due to low water consumption, CEL treatment has prevented BBN-induced liver impairment, suggesting that a low-dose celecoxib is not aggressive concerning the main organ functions. In relation to the nature of urothelium lesion, the hyperplasia and high-grade dysplasia induced by the carcinogen were highly prevented, decreasing from an incidence of 100% to 12.5%, together with a total prevention of papillary tumors and carcinomas.

Apart from the chemopreventive effect of selective COX-2 inhibition on cancer development, we were interested in assess the putative regressive action of this drug. In clinical practice, if a similar benefit was confirmed, this curative treatment could be useful for situations of bladder cancer irresponsive for surgical and pharmacological treatments, which is a common situation, as demonstrated by the high recurrence and progression rate and the poor prognosis, particularly for initial superficial forms, namely, when lately

diagnosed [3]. However, surprisingly, when used as curative treatment, the selective COX-2 inhibition was not only unable to inhibit tumor growth and development (75% incidence versus 65% in the carcinogen group) but also showed a promotion of tumor malignancy, demonstrated by the presence of more aggressive tumor types (such as the T1G2). Furthermore, this use of Celecoxib was more deleterious to the liver, as shown by the increased serum markers AST and ALT, contrasting with the preventive CEL treatment.

Human and animal, *in vitro* and *in vivo*, studies have proposed distinct cellular/molecular mechanisms to explain the chemopreventive effects of this group of compounds, particularly in prostate cancer, which includes the expected reduction of inflammation as a result of COX-2 inhibition, as well as other dependent or independent pathways, such as apoptosis induction, inhibition of cell growth, angiogenesis suppression, induction of cell cycle arrest, inhibition of peroxisome proliferator-activated receptors (PPARs) expression, or through other components, namely, of the immune system [30–35]. Not excluding other eventually relevant contributions, according to our data preventive Celecoxib use is able to promote cancer chemoprevention by mechanisms related with its expected anti-inflammatory action, but also with antioxidant properties. Therefore, serum CRP levels were highly reduced when compared with the carcinogen (BBN) group, which was accompanied by a more beneficial redox status profile, given by the lower lipid peroxidation, most likely indicative of reduced reactive oxygen species (ROS) formation. Thus, considering that inflammation and oxidative stress are key fuels for cancer development [36], the inhibition of those pathways in very early stages of the carcinogenesis process seems to be crucial for the prevention of tumor growth. This idea is reinforced by the results obtained for the curative celecoxib application, which was unable to reverse cancer progression, even demonstrating a malignant induction. The notorious augment of serum IL-1 $\beta$  in the group with higher tumor incidence (curative CEL group) suggests a special role of this cytokine in carcinogenesis and a potential therapeutic target, as was suggested by other studies [37, 38]. This was accompanied by a huge increment in serum IL-1 $\beta$ , demonstrating that further inflammatory pathways are activated when the celecoxib is used after the tumor induction. Moreover, in spite of lipid peroxidation reduction, the late CEL treatment was responsible for an undoubted aggravation of oxidative stress, most certainly involved in tumor progression. Our data are in agreement with the chemopreventive activity of celecoxib against colon carcinogenesis when the COX-2 inhibitor was administered during the initiation stage of carcinogenesis [39]. In our study, the curative CEL (BBN+CEL-C) group, despite a lower COX-2 staining in non-neoplastic areas, which is in agreement with the treatment performed (Celecoxib was given between the end of BBN treatment, week 12, and the final time for bladder collection: week 20), severe COX-2 immunostaining in the tumor lesion was encountered, demonstrating a clear overexpression, similar to that encountered in the BBN-treated rats.

The multistep nature of cancer development might provide opportunities for intervention with agents targeted at specific mechanisms involved in the initiation, promotion, and progression stages of cancers. Our data reinforce the pivotal role of inflammation in tumor development as well as the relevance of chemopreventive strategies based on earlier COX-2 inhibition, which might be particularly relevant for high-risk individuals as well as for patients treated for a previous episode of bladder cancer and under high possibility of recurrence. However, attention should be taken when using those drugs in patients with sustained bladder cancer, since, according to our data, cancer growth could not be reversed and, even more preoccupant, might be yet aggravated.

## 5. Conclusions

Inflammation, with COX-2 overexpression and/or hyperactivity, is a major contributor to bladder tumor development/progression. Inhibition of COX-2 by celecoxib proved to be a promising pharmacological modulation as chemoprevention of urinary bladder carcinogenesis if used earlier in tumor growth, as preventive, but not if used as a curative or regressive therapy. Our findings might be viewed as an open promising opportunity for improvement of pharmacological bladder cancer management based on preventive strategies of COX-2 inhibition but should also be viewed as an alert concerning its potential deleterious application in patients with consistent bladder cancer stages.

## Declaration of Interest

The authors report no conflict of interest.

## Acknowledgment

José Sereno, Belmiro Parada, and Flávio Reis equally contribute to the work.

## References

- [1] Z. Kirkali, T. Chan, M. Manoharan et al., "Bladder cancer: epidemiology, staging and grading, and diagnosis," *Urology*, vol. 66, no. 6, supplement, pp. 4–34, 2005.
- [2] J. Ferlay, P. Autier, M. Boniol, M. Heanue, M. Colombet, and P. Boyle, "Estimates of the cancer incidence and mortality in Europe in 2006," *Annals of Oncology*, vol. 18, no. 3, pp. 581–592, 2007.
- [3] K. Matsumoto, A. Irie, T. Satoh, H. Kuruma, T. Arakawa, and S. Baba, "Occupational bladder cancer: from cohort study to biologic molecular marker," *Medical Science Monitor*, vol. 11, no. 10, pp. RA311–RA315, 2005.
- [4] V. K. Sangar, N. Ragavan, S. S. Matanhelia, M. W. Watson, and R. A. Blades, "The economic consequences of prostate and bladder cancer in the UK," *BJU International*, vol. 95, no. 1, pp. 59–63, 2005.
- [5] M. Grasso, "Bladder cancer: a major public health issue," *European Urology, Supplements*, vol. 7, no. 7, pp. 510–515, 2008.
- [6] R. J. Sylvester, A. P. M. Van Der Meijden, W. Oosterlinck et al., "Predicting recurrence and progression in individual patients with stage Ta T1 bladder cancer using EORTC risk tables: a combined analysis of 2596 patients from seven EORTC trials," *European Urology*, vol. 49, no. 3, pp. 466–475, 2006.
- [7] S. B. Malkowicz, H. van Poppel, G. Mickisch et al., "Muscle-invasive urothelial carcinoma of the bladder," *Urology*, vol. 69, no. 1, supplement, pp. 3–16, 2007.
- [8] S. F. Shariat, J. H. Kim, G. E. Ayala, K. Kho, T. M. Wheeler, and S. P. Lerner, "Cyclooxygenase-2 is highly expressed in carcinoma in situ and T1 transitional cell carcinoma of the bladder," *Journal of Urology*, vol. 169, no. 3, pp. 938–942, 2003.
- [9] R. Baffa, J. Letko, C. McClung, J. LeNoir, A. Vecchione, and L. G. Gomella, "Molecular genetics of bladder cancer: targets for diagnosis and therapy," *Journal of Experimental and Clinical Cancer Research*, vol. 25, no. 2, pp. 145–160, 2006.
- [10] D. J. Wolff, "The genetics of bladder cancer: a cytogeneticist's perspective," *Cytogenetic and Genome Research*, vol. 118, no. 2–4, pp. 177–181, 2007.
- [11] D. Ahirwar, A. Mandhani, and R. D. Mittal, "Interleukin-10 G-1082A and C-819T polymorphisms as possible molecular markers of urothelial bladder cancer," *Archives of Medical Research*, vol. 40, no. 2, pp. 97–102, 2009.
- [12] R. E. Harris, "Cyclooxygenase-2 (cox-2) and the inflammogenesis of cancer," *Sub-Cellular Biochemistry*, vol. 42, pp. 93–126, 2007.
- [13] P. C. A. Kam and A. U. L. See, "Cyclo-oxygenase isoenzymes: physiological and pharmacological role," *Anaesthesia*, vol. 55, no. 5, pp. 442–449, 2000.
- [14] J. M. Di, J. Zhou, X. L. Zhou et al., "Cyclooxygenase-2 expression is associated with vascular endothelial growth factor-C and lymph node metastases in human prostate cancer," *Archives of Medical Research*, vol. 40, no. 4, pp. 268–275, 2009.
- [15] A. Sengupta, S. Ghosh, R. K. Das, S. Bhattacharjee, and S. Bhattacharya, "Chemopreventive potential of diallylsulfide, lycopene and theaflavin during chemically induced colon carcinogenesis in rat colon through modulation of cyclooxygenase-2 and inducible nitric oxide synthase pathways," *European Journal of Cancer Prevention*, vol. 15, no. 4, pp. 301–305, 2006.
- [16] L. S. Fournier, V. Novikov, V. Lucidi et al., "MR monitoring of cyclooxygenase-2 inhibition of angiogenesis in a human breast cancer model in rats," *Radiology*, vol. 243, no. 1, pp. 105–111, 2007.
- [17] R. W. Stockbrügger, "Nonsteroidal anti-inflammatory drugs (NSAIDs) in the prevention of colorectal cancer," *European Journal of Cancer Prevention*, vol. 8, no. 1, supplement, pp. S21–S25, 1999.
- [18] W. Kitayama, A. Denda, E. Okajima, T. Tsujiuchi, and Y. Konishi, "Increased expression of cyclooxygenase-2 protein in rat urinary bladder tumors induced by N-butyl-N-(4-hydroxybutyl) nitrosamine," *Carcinogenesis*, vol. 20, no. 12, pp. 2305–2310, 1999.
- [19] T. Shirahama, "Cyclooxygenase-2 expression is up-regulated in transitional cell carcinoma and its preneoplastic lesions in the human urinary bladder," *Clinical Cancer Research*, vol. 6, no. 6, pp. 2424–2430, 2000.
- [20] A. Ristimäki, O. Nieminen, K. Saukkonen, K. Hotakainen, S. Nordling, and C. Haglund, "Expression of cyclooxygenase-2 in human transitional cell carcinoma of the urinary bladder," *American Journal of Pathology*, vol. 158, no. 3, pp. 849–853, 2001.

- [21] R. D. Klein, C. S. Van Pelt, A. L. Sabichi et al., "Transitional cell hyperplasia and carcinomas in urinary bladders of transgenic mice with keratin 5 promoter-driven cyclooxygenase-2 over-expression," *Cancer Research*, vol. 65, no. 5, pp. 1808–1813, 2005.
- [22] B. Parada, J. Sereno, F. Reis et al., "Anti-inflammatory, anti-proliferative and antioxidant profiles of selective cyclooxygenase-2 inhibition as chemoprevention for rat bladder carcinogenesis," *Cancer Biology and Therapy*, vol. 8, no. 17, pp. 1615–1622, 2009.
- [23] S. Fukushima, M. Hirose, and H. Tsuda, "Histological classification of urinary bladder cancers in rats induced by N butyl N (4 hydroxybutyl)nitrosamine," *Gann, The Japanese Journal of Cancer Research*, vol. 67, no. 1, pp. 81–90, 1976.
- [24] R. Montironi and R. Mazzucchelli, "Preneoplastic lesions and conditions of the urinary bladder," *EAU Update Series*, vol. 1, no. 2, pp. 53–63, 2003.
- [25] G. Sauter, F. Algaba, and M. Amin, "Tumors of the urinary system: non-invasive urothelial neoplasias," in *WHO Classification of Tumors of the Urinary System and Male Genital Organs*, J. N. Eble, G. Sauter, J. L. Epstein, and I. Sesterhenn, Eds., pp. 29–34, IARCC Press, Lyon, France, 2004.
- [26] J. T. Leppert, O. Shvarts, K. Kawaoka, R. Lieberman, A. S. Belldgrun, and A. J. Pantuck, "Prevention of bladder cancer: a review," *European Urology*, vol. 49, no. 2, pp. 226–234, 2006.
- [27] V. Estepa, S. Ródenas, and M. C. Martín, "Optimización de un método para la determinación de la peroxidación lipídica en suero humano," *Anales de la Real Academia de Farmacia*, vol. 67, no. 3, pp. 1–17, 2001.
- [28] I. F. F. Benzie and J. J. Strain, "The ferric reducing ability of plasma (FRAP) as a measure of "antioxidant power": the FRAP assay," *Analytical Biochemistry*, vol. 239, no. 1, pp. 70–76, 1996.
- [29] C. J. Grubbs, R. A. Lubet, A. T. Koki et al., "Celecoxib inhibits N-butyl-N-(4-hydroxybutyl)-nitrosamine-induced urinary bladder cancers in male B6D2F1 mice and female Fischer-344 rats," *Cancer Research*, vol. 60, no. 20, pp. 5599–5602, 2000.
- [30] H. Süleyman, B. Demircan, and Y. Karagöz, "Anti-inflammatory and side effects of cyclooxygenase inhibitors," *Pharmacological Reports*, vol. 59, no. 3, pp. 247–258, 2007.
- [31] A. L. Hsu, T. T. Ching, D. S. Wang, X. Song, V. M. Rangnekar, and C. S. Chen, "The cyclooxygenase-2 inhibitor celecoxib induces apoptosis by blocking Akt activation in human prostate cancer cells independently of Bcl-2," *The Journal of Biological Chemistry*, vol. 275, no. 15, pp. 11397–11403, 2000.
- [32] X. Song, H. P. Lin, A. J. Johnson et al., "Cyclooxygenase-2, player or spectator in cyclooxygenase-2 inhibitor-induced apoptosis in prostate cancer cells," *Journal of the National Cancer Institute*, vol. 94, no. 8, pp. 585–591, 2002.
- [33] X. H. Liu, A. Kirschenbaum, S. Yao, R. Lee, J. F. Holland, and A. C. Levine, "Inhibition of cyclooxygenase-2 suppresses angiogenesis and the growth of prostate cancer in vivo," *Journal of Urology*, vol. 164, no. 3, pp. 820–825, 2000.
- [34] B. A. Narayanan, M. S. Condon, M. C. Bosland, N. K. Narayanan, and B. S. Reddy, "Suppression of N-methyl-N-nitrosourea/testosterone-induced rat prostate cancer growth by celecoxib: effects on cyclooxygenase-2, cell cycle regulation, and apoptosis mechanism(s)," *Clinical Cancer Research*, vol. 9, no. 9, pp. 3503–3513, 2003.
- [35] V. Vital-Reyes, C. Rodríguez-Burford, D. C. Chheng et al., "Celecoxib inhibits cellular growth, decreases Ki-67 expression and modifies apoptosis in ovarian cancer cell lines," *Archives of Medical Research*, vol. 37, no. 6, pp. 689–695, 2006.
- [36] A. Federico, F. Morgillo, C. Tuccillo, F. Ciardiello, and C. Loguercio, "Chronic inflammation and oxidative stress in human carcinogenesis," *International Journal of Cancer*, vol. 121, no. 11, pp. 2381–2386, 2007.
- [37] A. M. Lewis, S. Varghese, H. Xu, and H. R. Alexander, "Interleukin-1 and cancer progression: the emerging role of interleukin-1 receptor antagonist as a novel therapeutic agent in cancer treatment," *Journal of Translational Medicine*, vol. 4, article 48, 2006.
- [38] C. A. Dinarello, "Why not treat human cancer with interleukin-1 blockade?" *Cancer and Metastasis Reviews*, vol. 29, no. 2, pp. 317–329, 2010.
- [39] B. S. Reddy, Y. Hirose, R. Lubet et al., "Chemoprevention of colon cancer by specific cyclooxygenase-2 inhibitor, celecoxib, administered during different stages of carcinogenesis," *Cancer Research*, vol. 60, no. 2, pp. 293–297, 2000.



# Hindawi

Submit your manuscripts at  
<http://www.hindawi.com>

