



Contents lists available at ScienceDirect

## International Journal of Surgery Case Reports

journal homepage: [www.casereports.com](http://www.casereports.com)

## Stable fixation of a madreporic Lord femoral prosthesis at 31-year follow-up in a total hip arthroplasty: A case report



Fernando M. Judas<sup>a,\*</sup>, Joana Fonseca Ferreira<sup>b</sup>, Rui Freitas Dias<sup>a</sup>, Francisco M. Lucas<sup>a</sup>

<sup>a</sup> Orthopedics Department, Centro Hospitalar e Universitário de Coimbra (CHUC), Faculty of Medicine, University of Coimbra, Praceta Prof. Mota Pinto, 3000-075 Coimbra, Portugal

<sup>b</sup> Rheumatology Department, Centro Hospitalar e Universitário de Coimbra (CHUC), Faculty of Medicine, University of Coimbra, Praceta Prof. Mota Pinto, 3000-075 Coimbra, Portugal

## ARTICLE INFO

## Article history:

Received 14 September 2015

Received in revised form 8 December 2015

Accepted 9 December 2015

Available online 14 December 2015

## Keywords:

Lord total hip prosthesis

Lord femoral stem

Long-term result

## ABSTRACT

**INTRODUCTION:** Lord total hip prosthesis was discontinued due to high revision rates of the smooth threaded acetabular component and negative effects of stress shielding in the proximal femur.

**PRESENTATION OF CASE:** We report the outcome of a Lord cementless femoral stem, in a 55-year-old woman. In 1984, the patient underwent a Lord total hip arthroplasty for the treatment of advanced dysplastic osteoarthritis of the left hip. After 12 years, the cementless acetabular component of the prosthesis had been revised due to aseptic loosening. An acetabular metallic support ring and a cemented polyethylene cup were implanted, the femoral stem was not changed. The acetabular bone loss was reconstructed with morsellised cancellous bone allografts by the impacting technique. No complications were reported during the period of 19 years of the postoperative course. At the last clinical and radiological evaluations, the patient presented an asymptomatic hip and expressed high degree of satisfaction with the surgery result. The femoral stem was stable, with no measurable subsidence or radiolucent lines around the stem.

**DISCUSSION:** Several reports have presented a high clinical success rate with the fully-porous-coated Lord femoral stem in both primary and revision cases. However, the long-term results showed a substantial rate of proximal femoral bone loss and thigh pain.

**CONCLUSION:** In our case, the Lord stem showed an excellent long-term result at the 31-year follow-up. To our knowledge, there is no published report with results of the Lord stem longer than 26-year's follow-up.

© 2015 The Authors. Published by Elsevier Ltd. on behalf of IJS Publishing Group Ltd. This is an open access article under the CC BY-NC-ND license (<http://creativecommons.org/licenses/by-nc-nd/4.0/>).

### 1. Introduction

In the 1970s Lord and most investigators developed various types of cementless hip prosthesis. The emergence of cementless fixation of hip prosthesis was partially based on the early failure of cement fixation, with radiographic loosening upward of 30–40% at 10 years, namely in younger and more active patients. [1,2] Lord total hip arthroplasty (THA) was composed by cementless cobalt–chromium implants with a fully porous coated stem and a threaded cup (Fig. 1). The stem was relatively long coated with a sintered bead porous ingrowth/ongrowth surface, similar to the surface of some corals (madreporic), to provide osseous anchorage. Initial femoral stem fixation depended on a fit in the tight trochanteric and in the diaphyseal area of the femur [2].

Lord THA has been used rather extensively for the treatment of the hip osteoarthritis, namely in younger patients. At 1988, Lord

reports favorable results, an experience over ten years in a series of 2688 personal cases [3]. Most authors confirmed the excellent survival rate of the femoral component at long-term follow-up, and the poor results associated to the threaded acetabular cup [1,4,5]. Lord THA was abandoned at 1987 in our Orthopedic Department, due to the high failure rate of the threaded cup by aseptic loosening.

Studies of cementless stems with a minimum follow-up exceeding 20 years are uncommon [6]. The purpose of this paper is to show the excellent outcome of a Lord femoral stem at the 31-year follow-up, implanted for the treatment of end-stage hip osteoarthritis.


### 2. Case report

A 24-year-old woman, an active clothing store worker, underwent a total hip arthroplasty due to advanced dysplastic osteoarthritis of the left hip. A Lord cementless THA was implanted in 1983. The postoperative course was uneventful and she recovered promptly and had free of pain until 1996.

In 1995, at the 12-years follow-up, she was observed in our Orthopedics Department due to severe groin pain, resistant to analgesic medication, needing two forearm crutches to walk. Her body mass index was 23. The hip radiographic studies were consistent

\* Corresponding Author.

E-mail addresses: [fernandojudas@gmail.com](mailto:fernandojudas@gmail.com), [fernandojudas@iol.pt](mailto:fernandojudas@iol.pt) (F.M. Judas), [joana.fonseca.ferreira@gmail.com](mailto:joana.fonseca.ferreira@gmail.com) (J.F. Ferreira), [freitasdiasrui@sapo.pt](mailto:freitasdiasrui@sapo.pt) (R.F. Dias), [francisco.m.lucas@gmail.com](mailto:francisco.m.lucas@gmail.com) (F.M. Lucas).



**Fig. 1.** The Lord stem and the smooth threaded cup. The chrome–cobalt stem had a porous surface made up of 1 mm spheres, to provide osseous ingrowth/ongrowth and a solid fixation to the femoral bone.

with aseptic loosening of the acetabular component and a surgical intervention was proposed.

Surgery was performed via the posterior approach, the loosening cup was removed and an acetabular metallic support ring with a cemented polyethylene cup were implanted. The femoral stem was not changed. The associated acetabular bone loss was reconstructed with morsellized cancellous bone allografts, by the impacting technique.

No complications were reported in the perioperative course or during the hospitalization period. At 2 month postoperatively the patient was clinically able to walk without external support.

At 9 years after the revision of the acetabular cup, the clinical and radiological results were very favorable. Patient was free of pain, hip radiograph showed signs of stress shielding in the proximal femur, with no functional repercussion. Acetabulum bone allografts were incorporated, femoral stem was osseointegrated (Fig. 2).

In the last clinical and radiological controls, at 19 years after revision surgery, the patient was asymptomatic, the hip mobility was normal, and with no limitations on her social and professional life. Hip radiographic study showed a stable seating of the acetabular component and signs of stress shielding of the proximal femur. However, the femoral stem continued stable, with no measurable subsidence or radiolucent lines around the stem (Fig. 3). It was also possible to see signs of wear of the polyethylene cup, evidenced by a superior displacement of the metallic femoral head from the center of the acetabular cup.

### 3. Discussion

The importance of the present report is that it shows the excellent clinical and radiological outcomes of an extensively porous-coated femoral stem at the 31-years follow-up.

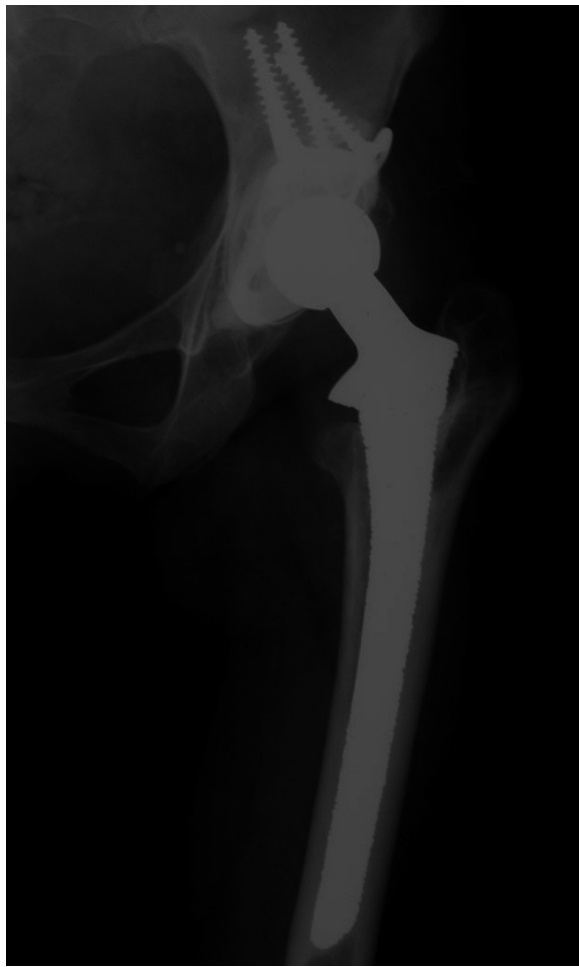Several reports have presented a high clinical success rate with the fully-porous-coated Lord femoral stem in both primary and revision cases [7]. Grant in a study of one hundred and two patients (116 hips) with a mean age of sixty-two years at the time of the

index arthroplasty, reported excellent survival rate after 17.5 years of follow-up [8]. However, there was a substantial rate of proximal femoral bone loss.

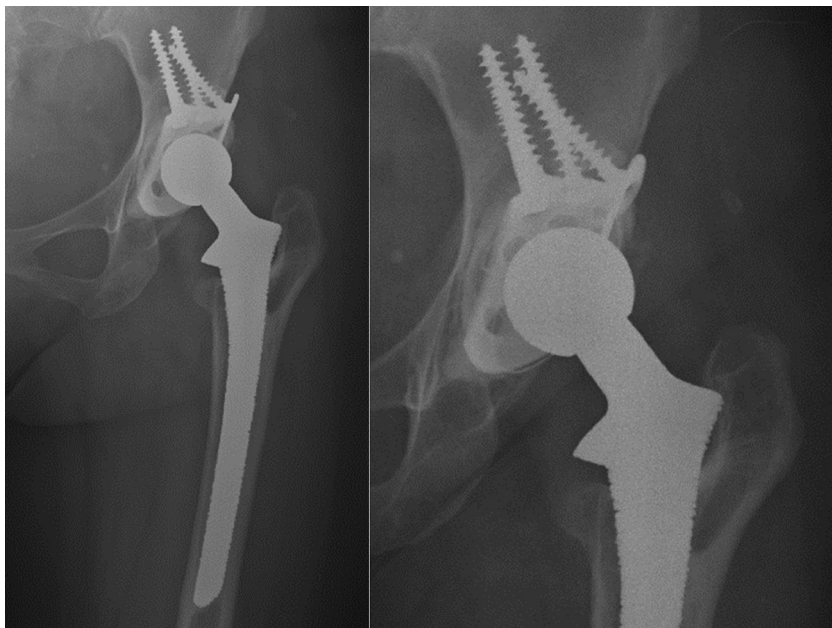
This type of porous coated of the femoral stem has introduced the new clinical problems of thigh pain and osteoporosis due to stress shielding of the proximal femur. Engh et al. showed that large and extensively coated stems were associated with an increase in bone resorption and osteolysis [9]. Proximal stress protection due to distal fixation has been regarded as a major problem with fully-coated stems. In addition, others problems could also be observed including, fractures of the femoral stem or surgical difficulties to extract the stem in cases of deep sepsis or aseptic loosening [1].

In contrast the uncoated smooth threaded cup of Lord has demonstrated poor fixation, early migration rate, resulting in reported high revision rates [4]. Our case confirmed this findings, the aseptic loosening of the cup was seen at the 12-year follow-up. Then, the cup was removed and an acetabular metallic support ring with a cemented polyethylene cup were implanted. The pelvic bone loss was reconstructed with morsellized cancellous bone allograft deep-freezing. The femoral stem was maintained confirmed by a solid fixation in the hip radiographic studies and there was neither stem subsidence nor distal bone density. Nonetheless is evident that bone of femoral calcar was resorbed and a moderate osteopenia and osteolysis were presented in the proximal femur, caused partly by stress shielding and partly by biological reaction to polyethylene wear debris. A pathologic fracture of the greater trochanter due to osteolysis can occur. Contrariwise, we consider that there is a very low risk of stem fatigue fracture. No complications were reported during the 19 years of the postoperative course.

The metal ring can be optimally adapted to the shape of the acetabulum since the polyethylene cup is anchored using cement and, thus, may be freely positioned. Favorable results were described using metal rings in congenital dysplasia of the hip, and in complex primary or revision hip arthroplasty. [10–12]



**Fig. 2.** Hip radiograph made 21 years after the Lord primary THA, showing a well-fixed Lord primary stem with signs of stress shielding of the proximal femur, and osteolysis of the great trochanter. At 9 years after the revision of the Lord primary acetabular cup, it was seen a stable fixation of the acetabular revision prosthesis.



**Fig. 3.** Hip radiograph made 31 years after the Lord primary THA. The femoral stem presented a solid fixation, with proximal osteolysis and no pain. Stable acetabular revision prosthesis with signs of wear of the polyethylene cup, 19 years after de acetabular revision surgery.

At follow-up period of 19 years, the anteroposterior total hip arthroplasty radiograph showed a stable acetabular component with wear of the polyethylene cup that can contribute, in association with stress shielding, to the moderate periprosthetic osteolysis in the trochanteric femoral region. The wear debris is an inevitable problem common to all hip endoprostheses.

During the last clinical and radiological examinations, the patient presented a stable and asymptomatic hip and expressed high satisfaction with the surgery result. The femoral stem presented an excellent fixation to the bone at follow-up period of 31 years.

Nowadays, like in the past, the acetabular side is the weak point in the hip prosthesis. The volume of THA will continue to escalate as will failures. A good knowledge of the various implants available for surgical application is essential to aid surgeon choosing a proper total hip prosthesis for each patient. Lord cementless THA is part of endoprosthetic surgery history.

#### 4. Conclusion

Despite Lord total hip prosthesis has been discontinued, we believe that many femoral stems will continue to show mechanical stability for a long time after acetabular component revision, similarly to the present report. It is important to emphasize that the patient is 55-years-old. To our knowledge, there are no previous reports concerning results of the Lord femoral stem with more than 26-year's follow-up.

#### Conflicts of interest

The authors declare that they have no competing interests.

#### Sources of funding

None.

#### Consent

Written informed consent was obtained from the patient for publication of this case report and any accompanying images. A

copy of the written consent is available for review by the Editor-in-Chief of this journal upon request.

#### Author contribution

All authors contributed to the writing and collection of data, and they have participated in the surgery. All authors read and approved the final manuscript for submission.

#### References

- [1] H. Malchau, P. Herberts, Y.X. Wang, et al., Long-term clinical and radiological results of the Lord total hip prosthesis. A prospective study, *J. Bone Joint Surg. (Br.)* 78 (1996) 884–891.
- [2] R. Zugner, R. Tranberg, P. Herberts, et al., Stable fixation but unpredictable bone remodelling around the Lord stem: minimum 23-year follow-up of 66 total hip arthroplasties, *J. Arthroplasty* 28 (2013) 644–649.
- [3] G. Lord, J.H. Marotte, J.P. Blanchard, et al., Madreporic, polarized total arthroplasties of the hip. Apropos of 2688 cases, *Rev. Chir. Orthop. Rep. L'appar. Mot.* 74 (1988) 3–14.
- [4] T. Kubo, S. Inoue, T. Maeda, et al., Cementless Lord total hip arthroplasty: cup loosening common after minimum 10-year follow-up of 103 hips, *Acta Orthop. Scand.* 72 (2001) 585–590.
- [5] C.C. Lyback, C.O. Lyback, A. Kyro, et al., A long-term follow-up of 60 Lord total hip arthroplasties in rheumatic disease: a mean follow-up of 14 years, *Int. Orthop.* 30 (2006) 391–394.
- [6] J.R. McLaughlin, K.R. Lee, Cementless total hip replacement using second-generation components: a 12- to 16-year follow-up, *J. Bone Joint Surg. (Br.)* 92 (2010) 1636–1641.
- [7] K.S. Keisu, E.B. Mathiesen, J.U. Lindgren, The uncemented fully textured Lord hip prosthesis: a 10- to 15-year followup study, *Clin. Orthop. Relat. Res.* (2001) 133–142.
- [8] P. Grant, L. Nordsletten, Total hip arthroplasty with the Lord prosthesis. A long-term follow-up study, *J. Bone Joint Surg. (Am.)* 86-A (2004) 2636–2641.
- [9] C.A. Engh, T.F. McGovern, J.D. Bobyn, W.H. Harris, A quantitative evaluation of periprosthetic bone-remodeling after cementless total hip arthroplasty, *J. Bone Joint Surg. (Am.)* 74 (1992) 1009–1020.
- [10] T.J. Gill, J.B. Sledge, M.E. Muller, Total hip arthroplasty with use of an acetabular reinforcement ring in patients who have congenital dysplasia of the hip. Results at five to fifteen years, *J. Bone Joint Surg. (Am.)* 80 (1998) 969–979.
- [11] K.M. Krishnan, L. Longstaff, P. Partington, Acetabular reconstruction using morcellised bone with ring support—medium-term results at three to nine years, *Acta Orthop. Belg.* 77 (2011) 61–67.
- [12] A.J.F. Proença, R. Cabral, N. Canha, Revision Surgery of Hip Prosthesis, Osteolysis Reconstruction with Bone Allografts, Orthopaedics Department of Coimbra University Hospitals, 1996.

#### Open Access

This article is published Open Access at [sciedirect.com](http://sciedirect.com). It is distributed under the [IJSCR Supplemental terms and conditions](#), which permits unrestricted non commercial use, distribution, and reproduction in any medium, provided the original authors and source are credited.